

Primary Splenic and Nodal Marginal Zone Lymphoma:

Jacques Diebold, Agnès Le Tourneau, Eva Comperat,
Thierry Molina and José e Audouin

Primary splenic and nodal marginal zone (MZ) lymphomas are rare small B cell lymphomas presenting with similar histopathologic features. The neoplastic cell population mostly consists of monocytoid B cells organized in a MZ pattern, associated with centrocytoid cells colonizing follicles. About 50% of cases have a monotypic plasma cell component. The different histopathologic patterns and differential diagnosis are discussed here. Both diseases share a similar immunophenotype, with the expression of B-cell associated antigens and restriction of immunoglobulin light chain. The only difference is the more frequent expression of IgD in splenic than in nodal lymphomas. The most recent findings in genetics and molecular biology are presented and discussed. The main clinical and biological symptoms are described and the similarity of some cases with Waldenströms macroglobulinemia is stressed. Both lymphomas present with the same type of bone marrow involvement with a high frequency of intravascular infiltrates, which can be associated with interstitial and nodular infiltrates. Transformation into diffuse large B cell lymphoma occurs in about 10 to 15% of the cases. The outcome in many splenic MZ lymphomas is characterized by a lengthy survival after splenectomy (9 to 13 years or longer), despite the absence of a consensus on the optimal treatment. Nodal MZ lymphoma has a more aggressive evolution and seems to only be curable at an early stage. Further studies are needed of both lymphomas to improve treatment and prognosis.

Key words primary splenic marginal zone lymphoma, primary nodal marginal zone lymphoma, bone marrow involvement in marginal zone lymphoma, secondary aggressive lymphoma in marginal zone lymphoma

INTRODUCTION

The WHO classification¹ recognizes three types of small B-cell lymphomas arising from the marginal zone (MZ) of lymphoid follicles. There is still some debate as to whether these three types, which primarily arise in mucosa-associated lymphoid tissue (MALT), lymph nodes, and spleen, are a homogeneous group of tumors or are instead different lymphomas with some common features. The aim of this review is to compare the morphology, immunophenotype, cytogenetics, clinical and biological characteristics, and progression of primary nodal and primary splenic MZ lymphomas.

THE CONCEPT OF MZ

The term MZ (marginal zone) was initially proposed by Snook² to describe the pale corona surrounding the mantle zone of splenic follicles. This corona was first described at

the beginning of the 20th century³ and has been observed in the spleens of rodents and humans^{4,5}. The MZ can also be observed in mucosa-associated lymphoid tissues (MALT), such as tonsils and Peyer's patches, in hyperplastic follicles arising in the gastrointestinal tract (follicular gastritis due to *Helicobacter pylori* infection), and in autoimmune disorders, such as thyroiditis or sialadenitis⁶. The MZ can occasionally be observed in lymph nodes, particularly in those draining MALT, such as the cervical lymph nodes draining the tonsils and the mesenteric lymph nodes^{7,8}. The MZ has a pale perifollicular corona appearance due to the peculiar morphology of the lymphoid B-cells from which it is formed. These medium-sized cells exhibit an abundant pale cytoplasm surrounding an oval or kidney-shaped nucleus with some irregularities and a medium-sized central nucleolus. The chromatin is organized in smaller blocks than in small B-lymphocytes.

MZ cells express CD 20, CD 79a, bcl-2, and surface immunoglobulin (Sig), which is mostly IgM and rarely IgG or IgA. They do not express CD 5, CD 10, CD 11 c, or CD 23^{5,7}. This immunophenotype is different from that of centrofollicular B-cells and mantle cells. The absence of IgD and the presence of CD 21 and CD 27 indicate that MZ cells are related to memory B-cells⁹. However, IgD is expressed by some MZ cells, as in mantle cells¹⁰, indicating the heter-

Received : Dec, 2004

Accepted : Dec, 2004

Department of Pathology, Hôtel-Dieu, place du Parvis Notre-Dame, F-75181 PARIS Cedex 04

Address correspondence and reprint requests to Jacques Diebold, Department of Pathology, Hôtel-Dieu, place du Parvis Notre-Dame, F-75181 PARIS Cedex 04

ogeneous nature of the MZ cell population. KiB 3, an antibody produced by a group from the University of Kiel, revealed the presence of different subsets of MZ cells¹¹. This antibody recognizes a glycosylation-independent epitope of CD 45 RA, present in immunocompetent B lymphocytes that have not yet responded to antigenic stimulation⁹. Most MZ B-cells are negative for KiB 3 staining. Only a subset of splenic MZ cells and mantle cells are positive for KiB 3⁹. This subset expresses IgD in addition to IgM, but is negative for CD 21 and CD 27 and shows some similarities with naive B-cells.

MZ B-cells are morphologically similar to cells first described by Lennert¹² in Piringer's lymphadenitis, which were called "immature histiocytes. Later, these cells were demonstrated to express a B immunophenotype leading to calling them "monocytoid B-cells^{8,13,14}. Monocytoid B-cells represent a peculiar type of small B-cell in rodents¹⁵ and humans^{9,13,16,17}. Recent studies¹⁸ have shown that reactive monocytoid B-cells exhibit a peculiar profile: negative for bcl 2 protein, no detectable surface immunoglobulins, expression of p 21 (WAF 1), cyclins E, D 2, and D 3, and strong p 27 expression. This immunophenotype is different from that of non-neoplastic splenic MZ B-cells and from neoplastic B-cells from splenic and nodal MZ lymphomas. These neoplastic B-cells are bcl 2-positive and express IgM, but are negative for or express only very low levels of cyclins A, B, E, and D, and p 21¹⁸. These findings led to the hypothesis that reactive monocytoid B-cells represent either a unique B-cell population arising from an unknown cell lineage, or are related to MZ B-cells but represent a distinct differentiation stage¹⁸.

MZ B-cells appear to have many functions¹⁹. In rodents and humans, they play an important role in the thymus-independent type 2 immune response (Ti-2) to antigens including some bacterial capsular antigens²⁰. They are the main group of splenic B-cells responsible for mounting a humoral immune response against bacteria present in the peripheral blood. This explains why splenectomized patients have an impaired response to some Ti-2 antigens. In addition, in rodents, the MZ also contains memory B-cells from T-cell-dependent humoral immune responses²¹.

PCR analyses of point mutations in Ig genes in microdissected cells have shown that most splenic MZ B-cells are postfollicular memory B-cells^{22,23}, although a small number are similar to mantle B-cells⁹. The function of MZ B-cells is still unclear. Postfollicular memory B-cells are recirculating memory B-cells²². Splenic MZ B-cells can bind polysaccharide antigens with two possible outcomes⁹. Some of these cells migrate to germinal centers, present the polysaccharide antigens to centrofollicular B-cells, and trigger a humoral immune response. Others come into contact with T-cells, which release cytokines that rapidly transform the B cells into plasma cells⁹. This represents a T-cell-dependent humoral

immune reaction. It should be noted that in the spleen, the MZ is in close contact with periarteriolar sheets consisting of T-cells and that numerous dispersed T-cells or T-cells in nests are present in the MZ. Mice knocked out for Pyk-2, a tyrosine kinase involved in the control of cell adhesion and motility, lack splenic MZ cells²⁴ and exhibit a strong deficit in IgG 3 responses to Ti-2 antigens and a slight deficit in IgM secretion after stimulation with T-cell-dependent antigens. (2)

To explain the location of MZ B-cells, Guinamard *et al.*²⁴ suggested that resident macrophages secrete a hypothetical MZ B-cell trophic chemokine. Maes and de Wolf-Peeters suggested that the B-lymphocyte stimulator (BLYS/BAFF) is a candidate for transmitting T-independent signals that might induce proliferation and rapid differentiation of MZ B-cells into Ig-secreting cells. BLYS/BAFF belongs to the tumor necrosis factor (TNF) family of proteins and is secreted by myeloid-monocytoid cells. Mature B-cells express receptors for BLYS/BAFF. Binding of BLYS/BAFF activates the transcription factor NF-kappa B²⁵, which is essential for the development, survival, and proliferation of MZ B-cells¹⁹.

FIRST DESCRIPTION OF LYMPHOMAS ARISING FROM THE MZ

Lymphomas consisting of cells thought to be derived from MZ B-cells were first reported in the spleen in 1980 by Cousar *et al.*²⁶ and in the salivary glands in 1982 by Schmid *et al.*²⁷ When the term monocytoid B-cells was given in 1984 to cells found in Piringer's lymphadenitis, the term "monocytoid B-cell lymphoma" was used to describe some nodal lymphomas²⁸⁻³². At the same time, Isaacson and Wright⁶ reported four cases of extranodal lymphomas arising from MALT and particularly from the MZ of follicles.

Between 1982 and 1992, the Kiel group described 28 cases of B-cell lymphoma in lymph nodes, comprising sheets of monocytoid B-cells^{33,34}. Nineteen appeared to be restricted to the lymph node. Nine were associated with an extranodal lymphoma of MALT, which also contained monocytoid B-cells. Nathwani *et al.*³⁵⁻³⁷ and Ortiz and Wright³⁸ demonstrated that monocytoid B-cell ML occur primarily in the lymph nodes without any extranodal MALT lymphoma. These primary nodal MZ (PNMZ) lymphomas are distinct from follicular lymphomas or mantle cell lymphomas with a monocytoid component. It has been proposed that PNMZ lymphomas be divided into a "MALT type and a "splenic type^{39,40}. This reflects the wide spectrum covered by the term MZ lymphoma, with the splenic type and the MALT-type at the two extremes rather than being truly different types¹⁹. Both types can be observed in PNMZ lymphoma.

Schmid *et al.*⁴¹ published the first four cases of primary splenic MZ (PSMZ) lymphoma in 1992. However, similar cases had been reported before²⁶, often with another diagnosis

such as lymphoplasmacytic lymphoma⁴². Since these first reports, numerous cases have been described⁴³⁻⁵⁰. Due to the presence of peculiar lymphocytes in the peripheral blood, many cases have been diagnosed as splenic lymphoma with villous lymphocytes⁵¹⁻⁵⁵. The REAL classification suggests that PSMZ lymphoma is a provisional entity⁵⁶, and the WHO classification proposes that it is a true entity¹. (3) Recent studies have shown that bone marrow involvement is frequent in both PSMZ and PNMZ lymphomas but less frequent in MALT lymphomas^{49,57-61}. Thus, bone marrow biopsy (BMB) appears to be very useful for diagnosis.

SPLENIC MZ LYMPHOMA

This lymphoma represents less than 1% of all lymphomas¹. However, it is the most frequent small B-cell lymphoma associated with splenomegaly and probably the most frequent splenic lymphoma⁴⁸.

Clinical and biological data

The patients we reported⁴⁹ had a median age of 61 years, ranging from 21 to 85 years. Women were slightly more common than men (sex ratio F : M=1.8). These results were similar to those published in other reports^{1,19,41,50}. Most patients initially presented with splenomegaly, which was often massive. A few cases without splenomegaly have been reported⁴⁴. Hepatomegaly was observed in less than half of cases. Peripheral adenopathies were observed in a small number of patients, mostly those with a long follow-up. Thrombocytopenia may occur as well as anemia and leukopenia. Anemia is often the consequence of an autoimmune hemolytic process. (4) Peripheral blood absolute lymphocytosis occurs in about 25% of patients⁵⁸. These lymphocytes express monotypic surface immunoglobulins. This may lead to a false diagnosis of B-cell chronic lymphocytic leukemia. In some cases, the lymphocytes show the morphology of villous lymphocytes, and many cases were diagnosed as "splenic lymphoma with villous lymphocytes"^{51-53,55,62}. A small number of cases have been diagnosed as hairy cell leukemia.

A serum monoclonal component (MC) seems to be present more often than previously assumed. This MC is mostly $\mu\kappa$, and occasionally $\mu\lambda$ ⁴⁹. The concentration of the MC differs from one ζ patient to another and seems to increase over time. Sometimes the concentration may be greater than 5 g/L, consistent with a diagnosis of Waldenström's macroglobulinemia. Hyperviscosity syndrome may even be present. MC and autoimmune disorders such as autoimmune hemolytic anemia (AIHA), immune thrombocytopenia, and circulating autoantiprothrombinase, were observed in our series⁴⁹, but only in patients presenting a monotypic plasma cell population in the spleen (see below).

Macroscopic features of the spleen

In our series, the spleen was typically enlarged (median weight : 1360 g, range 660-3100 g). Similar findings have been reported in the literature. Lymphadenopathies of various sizes were present in the hilum. The cut surface showed a multimicronodular pattern in all cases. White nodules, measuring 0.5 cm or less, were dispersed throughout the entire splenic parenchyma. This pattern is not specific for MZ lymphoma, and has been observed in all types of small B-cell lymphoma involving the spleen, with the exception of hairy cell leukemia that diffusely infiltrates the red pulp^{11,49}. This pattern reflects the predominance of white pulp involvement.

Histopathology

The architecture of the spleen was preserved. Lymphomatous infiltration was predominant in the white pulp (Fig. 1), with enlarged follicles^{11,49}. The most characteristic lesion was a broad, clear MZ at the periphery of each nodule (Figs. 1 and 2). The cells that constitute these MZ were monocytoid B-cells. They were medium-sized and had an abundant pale cytoplasm with clear cell borders. Nuclei were ovoid or slightly irregular, with open chromatin and small nucleoli. Large B-cells, resembling centroblasts or immunoblasts, were scattered between the monocytoid B-cells, accounting for less

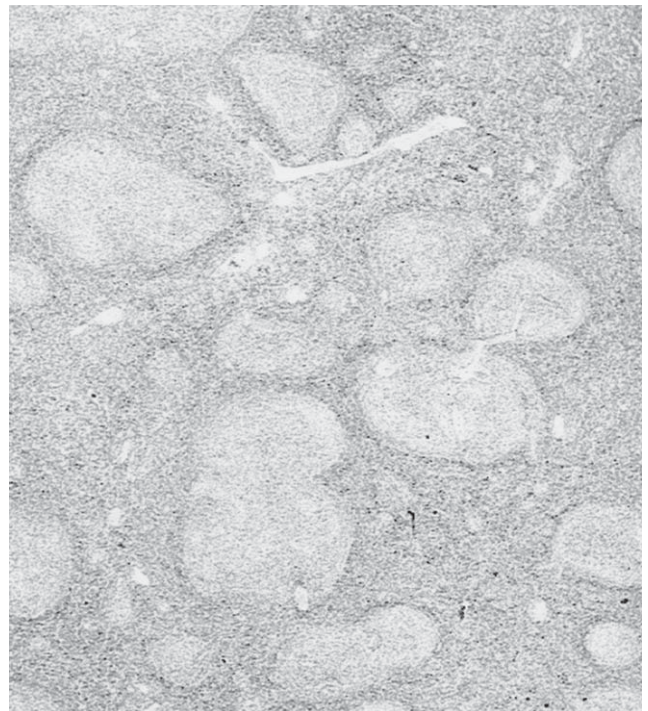


Fig. 1. Primary splenic MZ lymphoma (HE, $\times 2$). Follicles are surrounded by a pale MZ and homogenized, due to colonization by lymphoma cells.

than 20% of the total population. The centers of the nodules were often dark, homogeneously consisting of small lymphocytes with dark chromatin and no recognizable nucleolus. Some had a round nucleus and a thin rim of cytoplasm, as in the normal mantle zone. Many exhibited a dark nucleus with irregular, often cleaved contours and a larger pale cytoplasm. These cells have been called centrocytoid, due to the morphology of their nuclei. Most had a B-immunophenotype, and the same monotypic surface immunoglobulins as in monocytoid B-cells were seen on frozen sections. Both centrocytoid and monocytoid cells belong to the lymphoma cell population. This is similar to follicular colonization, as described in extranodal MZ MALT lymphoma⁶. Sometimes, reactive germinal centers of various sizes were observed in the dark centers of the nodules. In about one third of cases, regressive germinal centers were detected, with an onion bulb-like pattern, causing a Castleman-like modification.

In a few cases, the MZ pattern was not so clear. The MZ was small or infiltrated by cords of small lymphocytes, sometimes dividing the MZ into two parts. The centers of the follicles were large and homogeneous. Such cases were difficult to distinguish from B-CLL and mantle-cell lymphoma, without immunohistochemistry. About half of all cases were associated with a plasma cell component. This component consisted of a mixture of mature plasma cells and of lymphoplasmacytic cells. Some of these cells contained PAS-positive intranuclear vacuoles (Dutcher-Fahey bodies). The plasma cell component represents a variable part of the MZ and infiltrates the mantle zone and germinal center of follicles. Small clusters of epithelioid cells, or less frequently epithelioid cell granulomas, could also be observed in or around the MZ.

The cords of the red pulp were always diffusely infiltrated by centrocytoid and/or monocytoid cells and also by the plasma cell component when present (Fig. 2). The density of cord infiltration seemed to depend on disease duration. Another pattern of red pulp involvement involves the presence of centrocytoid or monocytoid cells in the lumen of sinuses. This was observed mostly in patients with peripheral blood lymphocytosis and has been described in chronic leukemia with villous lymphocytes. Both types of red pulp involvement can occur in the same patient, sometimes leading to a dense infiltration of the red pulp. In a few cases, we also observed focal areas with sinus dilatation, leading to a pseudoangiomatous pattern, similar to that described in hairy cell leukemia, representing something similar to peliosis^{11,49}.

Splenic hilar lymphadenopathy

A nodular pattern was often observed together with a MZ pattern due to the perifollicular accumulation of monocytoid B-cells^{49,63}. The follicles were more or less homogenized by the infiltration of centrocytoid cells, with germinal



Fig. 2. Primary splenic MZ lymphoma (HE, $\times 10$). The follicle in the upper part, is colonized by centrocytoid cells and shows a regressive germinal center. It presents a pale MZ at the periphery. Lymphoma cells infiltrate the red pulp (bottom), particularly the cords.

centers more or less recognizable. A more diffuse infiltrate could also be observed. All cases with a plasma cell component in the spleen also showed a plasma cell infiltrate in the hilar lymph node. In all cases, hemosiderin-laden macrophages accumulated in the sinuses and even in the parenchyma.

Liver

In most cases in our series⁴⁹, the portal spaces were infiltrated by centrocytoid and monocytoid cells, either diffusely or with a more nodular pattern. These cells were associated with plasma cells when this component was present in the spleen. Small centrocytoid cells have been seen in the sinusoids, particularly in patients with peripheral blood lymphocytosis. Rarely, perhaps during an early phase of the disease, the liver is not involved.

Immunohistochemistry

The neoplastic cells, including many cells from the plasma cell component, express CD 20 and CD 79a. These cells also express bcl-2, p 53, and p 27¹⁸. In a few cases, they also express DBA 44 (35%). IgD was found in the majority of the

cases in our series⁴⁹, mostly in cells of the MZ, or in cells colonizing the inner part of germinal centers. Recently, CD 27, a marker for memory B-cells, was found to be expressed on neoplastic cells from seven out of ten PSMZ lymphomas, whereas the MZ B-cells from all cases with normal spleens were found to be positive for CD 27⁶⁴. This confirms the heterogeneity of the neoplastic cell population in PSMZ lymphoma, with some cells corresponding to memory B-cells and others to naive B-cells. The neoplastic cells were negative for CD 5, CD 10, CD 23, CD 43, bcl-6, and cyclin D 1. A network of follicular dendritic cells was present in the germinal centers, stained with anti-CD 21, anti-CD 23, anti CD 35, and CNA 42 antibodies. Finally, fewer than 5% of cells expressed Mib 1. Cyclins A, B, D, and E, and p 21 were undetectable or only present at very low levels¹⁸. A monotypic immunoglobulin could be easily detected in the cytoplasm of the plasma cell component in over 40% of cases. The μ chain was the most frequent heavy chain detected. The κ light chain was expressed six times more frequently than λ . Cases with a bclonal population have also been reported^{49,65}. In patients without a plasma cell component, nests of polytypic reactive plasma cells were observed in the cords of the red pulp of the spleen.

Peculiar subtype

A small number of cases with spleens with morphology typically associated with SMZ lymphoma share some characteristics with mantle cell lymphoma: expression of CD 5 and the oncoprotein cyclin D 1 and the presence of a t(11; 14)^{9,58}. In some cases⁹, patients also present with villous circulating lymphocytes and bone marrow sinusoidal involvement. These patients⁹ underwent splenectomy without any other treatment and were still alive and well 2 to 3 years later. Further studies are needed to determine whether these cases represent mantle cell lymphoma of the spleen with a MZ differentiation or a special subtype of MZ lymphoma of the spleen sharing characteristics with mantle cell lymphoma.

Outcome

In our series⁴⁹, the median follow-up was 70 months (range 5-173 months). Thus, many patients survived for 10 to 15 years after splenectomy and chemotherapy. After splenectomy, peripheral lymphadenopathies may develop. Biopsy should always be performed. The risk of transformation into a more aggressive large B-cell lymphoma is now well demonstrated^{49,66}. Other series^{58,67,68} also reported long survival times (between 9-13 years) after only splenectomy. There is no consensus concerning the optimal therapeutic strategy. Prospective trials are needed. Some factors associated with a severe adverse prognosis have been identified⁹: AIHA, immune thrombocytopenia, high serum monoclonal

component (MC) and beta 2 concentrations, microglobulinemia, blood leukocyte count >>20,000/ μ L, blood lymphocyte count >9,000 μ L, and overexpression of p 53 by neoplastic cells^{58,67,68}.

NODAL MZL

This type of lymphoma accounts for less than 1% of all lymphoid neoplasms^{1,69}.

Clinical and biological data

Primary nodal MZ (PNMZ) lymphoma occurs at approximately the same age as SMZL. The sex ratio is also similar. Patients have localized or generalized peripheral lymphadenopathies. In early reports, patients were stage I or II, but they now often present with an advanced stage (III or IV)^{35-37,63}. A small number of patients show B symptoms¹¹. Signs of leukemia are rare, as is the presence of a monoclonal component (MC) in the serum¹¹. About half of all patients have an International Prognostic Index (IPI) score between 1 and 2. In a few patients, splenomegaly is observed at presentation. These cases are impossible to distinguish from cases of PSMZL associated with peripheral lymphadenopathy⁴⁹. Careful studies of such cases are needed to better diagnose them. It is also necessary to search for extranodal MZ MALT lymphoma systematically, namely to distinguish secondary nodal involvement from true PNMZ lymphoma³⁵⁻³⁷. A series of 48 cases of NMZL occurring in children and young adults was recently reported⁷⁰. Half of these patients were aged 18 years or younger. Two thirds of cases (67%) were classified as primary NMZL. Most of these cases concerned young males (median 16 years, M/F ratio 5.4: 1), presenting a localized adenopathy (90% stage I). The prognosis was excellent, better than for extranodal MZL in the same age group, with a low rate of recurrence⁷⁰.

Histopathology

Some cases are easy to recognize due to the presence (visible at low magnification) of pale plaques, more or less sharply demarcated, in and along the sinuses, with a peritrabecular and subcapsular topography (Fig. 3). A complete or partial MZ sometimes forms a pale ring around nodules (Fig. 4). Germinal centers can be present. They can be reactive, regressive with a Castleman-like pattern, or colonized by small centrocytoid cells. The neoplastic cells exhibit the typical morphology of monocytoid B-cells (Fig. 5 A), with an abundant faintly eosinophilic cytoplasm with hematoxylin-eosin or gray cytoplasm with Giemsa. These cells have medium-sized nuclei, round or slightly indented or cleaved, with chromatin in small blocks and a single small nucleolus. Large B-cells, with the morphology of centrob-

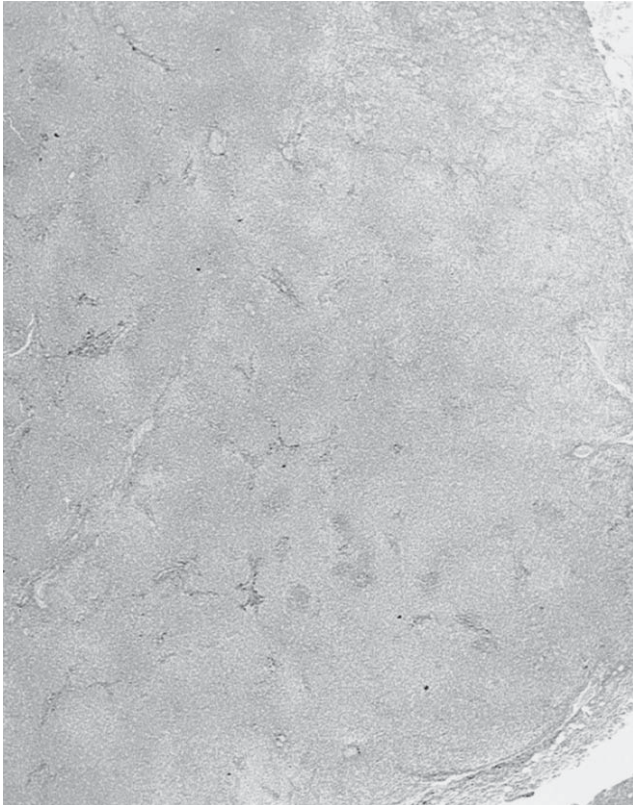


Fig. 3. Primary nodal MZ lymphoma (HE, $\times 1.25$). Pale bands or nodules can be recognized, with small remnants of lymphoid tissue (dark areas).

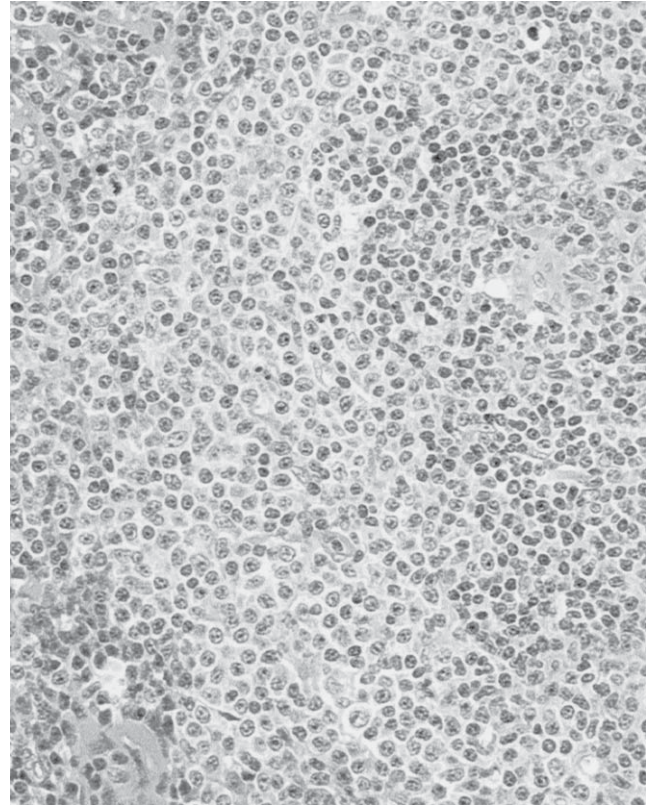


Fig. 4. Primary nodal MZ lymphoma (HE, $\times 40$). Bands around remnants of follicles or along the sinuses, consist of monocytonoid B cells.

lasts or more often of immunoblasts, are scattered between monocytonoid B-cells (Fig. 5 A). Centrocytonoid cells infiltrated follicles (Fig. 5 B). In some cases, a large number of plasma cells and lymphoplasmacytes accumulate at the periphery of the pale areas (Fig. 5 C). In other cases, these cells are dispersed in the centers of the nodules. Clusters of epithelioid cells may be present. When the follicles are numerous, a nodular pattern with MZ is clearly visible. The follicles are sometimes rare and the monocytonoid B-cells form a more diffuse infiltrate along the sinuses. In other cases, they are even more diffusely infiltrated. When centrocytonoid cells are more numerous than monocytonoid cells, the diagnosis can be extremely difficult due to similarities with other small B-cell lymphomas. In rare cases, plasma cells can be numerous, forming large sheets and mimicking a plasmacytoma. In some cases, the centers of the nodules show regressive germinal centers mimicking Castleman disease. A few publications have reported an association between Castleman disease and MZ lymphoma^{71,72}. In pediatric cases, the disruption of residual follicles is common, resembling the progressive transformation of germinal centers⁷⁰. Finally, areas consisting of numerous contiguous large B-cells replace the sheets of monocytonoid B-cells. This pattern represents the

progression into a diffuse large B-cell lymphoma⁶¹.

Immunohistochemistry

The immunophenotype of PNMZ lymphoma is similar to that of PSMZ lymphoma. B-cells express CD 20, CD 79 a, KiB 3 (related to CD 45 RA), and often SIGM, mostly with the κ light chain¹¹. Some cases may be IgD (-). Biclonal cases can occur, as in PSMZL⁶⁵. The plasma cell component, when present, expresses the same monotypic Ig in the cytoplasm as on the cell membrane.

Outcome

In a study by Cogliatti *et al.*³³, stage I and II patients were treated with radiotherapy, and stage III and IV patients with chemotherapy. Complete remission lasted from 1-78 months (mean : 28 months in 15 cases). Six patients remained free of recurrence (30%) for at least 34 months, with a maximum of over 6.5 years. More than half of patients relapsed after a remission period of between 1 and 55 months (mean 20 months). Five patients (28%) died from causes related to lymphoma after 3 to 54 months (mean 24 months).

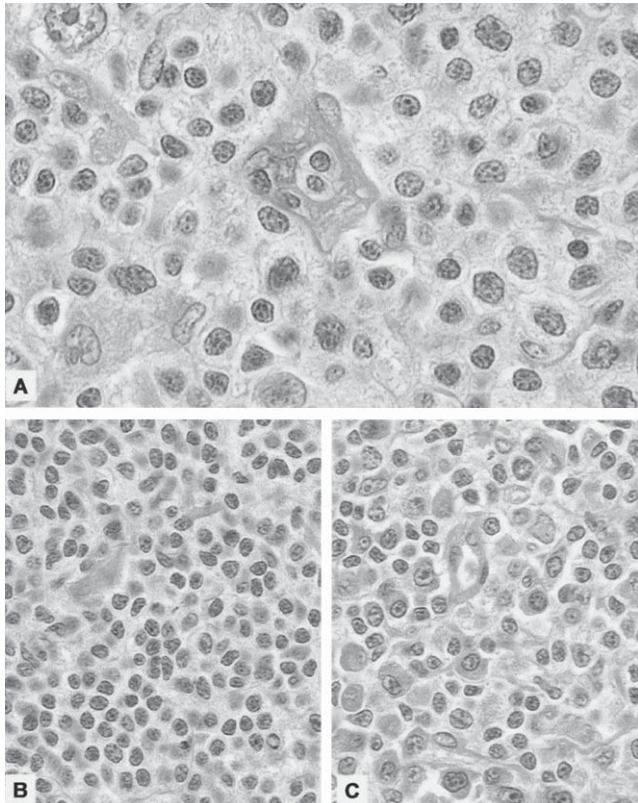


Fig. 5. Primary nodal MZ lymphoma (HE, $\times 100$). A ; Monocytyoid B cells in the MZ with a large blast in the upper left corner. B. Centrocytoid cells colonizing the germinal center. C. Clusters of mature plasma cells in the MZ.

In the series reported by Nathwani *et al.*³⁷, the overall five-year survival rate was 56% and the five-year failure-free survival rate was 28%. NMZ lymphoma is only curable during the early stages and is more aggressive than SMZ lymphoma.

TRANSFORMATION INTO DIFFUSE LARGE B-CELL LYMPHOMA

This transformation is characterized by the infiltration and destruction of the MZ in the spleen or lymph node by sheets of large cells. The large cells are similar to centroblasts, immunoblasts, or immunoblasts with a plasmacytic differentiation. They express B-cell markers (CD 20, CD 79 a, and bcl-2) and are negative for CD 5, CD 10, CD 23, and IgD. The same monotypic immunoglobulin produced by the plasma cell component can be detected in the cytoplasm of large cells, particularly in immunoblasts with plasmacytic differentiation. PCR studies have shown the same Ig gene rearrangement in the small and large B-cell components, confirming that they share a common origin⁶⁶. Between 30 and 60% of cells express Mib-1. Progression to diffuse large B-cell

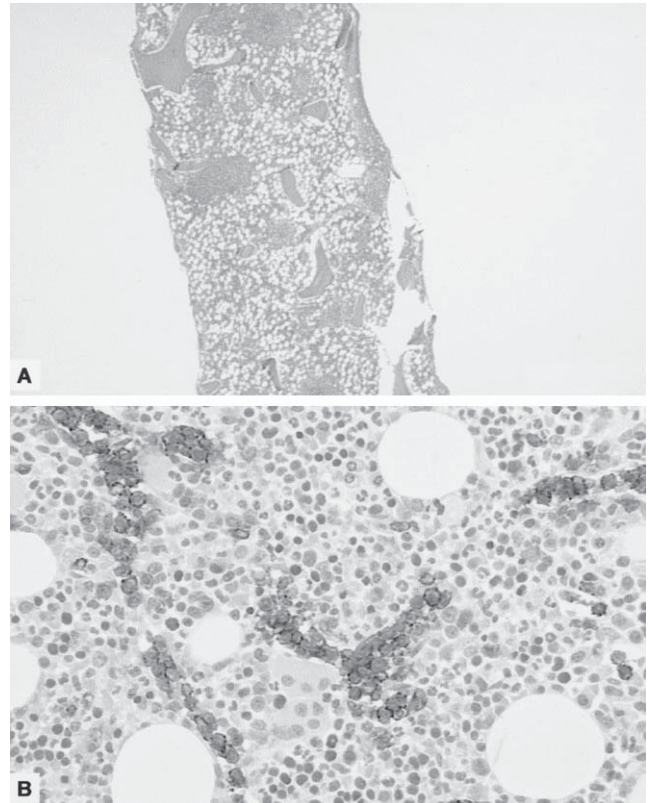


Fig 6. Bone marrow biopsies in patients with a primary splenic MZ lymphoma. A. Multiple intertrabecular nodules (HE, $\times 2$). B. In another case, only intravascular infiltrates could be observed. Immunohistochemistry is very useful to demonstrate the presence of neoplastic B cells in the lumen of small vessels (CD 20, immunoperoxidase)..

lymphoma occurs in about 10 to 15% of patients^{49,66}. Progression can occur in patients with PSMZL in the spleen or even in the bone marrow (BM) at presentation or later, such as after splenectomy in peripheral lymph nodes^{49,63,73}.

BONE MARROW INVOLVEMENT IN NODAL AND SPLENIC MZL

The frequency of BM involvement differs greatly between nodal and splenic MZL. In splenic MZL, the reported frequency is between 86%^{58,68} and 100%^{59,60}, while for nodal MZL it is between 28%^{36,69} and 43%⁵⁸. In comparison, less than 18% of patients with extranodal MALT lymphomas have BM involvement^(36,58,60,61). Both nodal and splenic MZL show the same pattern of BM involvement^{60,61}. The most original pattern is intravascular infiltration^{57,60,61,74}. This is characterized by the accumulation of small- to medium-sized lymphoid cells, either in small clusters distending the venous sinuses or in monocellular columns in capillaries. This intravascular infiltrate is sometimes easier to recognize after de-

monstration of CD 20 expression by immunohistochemistry (Fig. 6 B). This infiltrate may be the only type of involvement. It represents the first lesion in the BM and may be the only sign of residual disease after treatment. In our series⁶⁰, this type of intravascular infiltration was observed in all biopsies from patients with BM involvement, associated with other types of infiltration. The second type of involvement is interstitial infiltration. This may be localized or more diffuse, forming lymphoid aggregates. A third frequent type is intertrabecular or juxtatrabecular nodules^{60,61,74,75}. Their number varies from 2 to more than 10 nodules per 1 cm section (Fig. 6 A). Some are homogeneous, consisting of small cells with centrocytoid morphology. Others exhibit homogeneous nodules surrounded by a more or less typical pale MZ composed of large lymphoid cells with a monocytoid appearance. In rare cases, the nodules show a reactive germinal center or remnants of a more or less colonized germinal center. After years of progression, massive infiltration of all medullary spaces can be observed, with slight nodularity⁶⁰.

Plasma cells and lymphoplasma cells can present in about 40 to 50% of patients, regardless of the type of extravascular infiltration. They form clusters around the nodules or are dispersed between the lymphoid cells of the interstitial or nodular infiltrate. This cell population produces a monotypic intracytoplasmic immunoglobulin, mostly μ or κ , similar to that observed in the spleen and lymph nodes^{60,61}. A peculiar pattern has been seen in a very small number of treated SMZL or NMZL patients. In these cases, the BM involvement consists of an interstitial plasmacytic infiltrate mimicking a myeloma^{60,61}. This pattern disappears after the end of chemotherapy and is replaced by a nodular and interstitial infiltrate. In about 10% of our cases^{60,61}, transformation into a diffuse large B-cell lymphoma was identified due to the presence of areas only containing large B-cells with the morphology of centroblasts, immunoblasts, or plasmablasts or due to the presence of these large B-cells only in the lumen of vessels. The immunophenotype of the neoplastic cells is similar to that found in the spleen and in adenopathies. The neoplastic cells present in the vessels do not express CD 27, whereas those in the interstitial infiltrates and nodules do⁶⁴. This suggests two different phases of neoplastic progression: the expansion of a clone of virgin B-cells in the BM and recolonization of the BM by memory B-cells following exposure to antigens⁶⁴.

RELATION WITH WALDENSTRÖMS MACROGLOBULINEMIA

Seven patients in our series of PSMZL^{49,60} had a serum monoclonal IgM concentration of 5 g/L or more, associated with liver and bone marrow infiltration by a subset of lymphoplasmacytic/plasma cells containing a monotypic intracytoplasmic immunoglobulin. This is typical of Waldenströms

macroglobulinemia (WM). The relationship between WM and MZL is not well understood⁷⁶. Some MALT lymphomas mimicking WM have also been reported⁷⁷. It is possible that, in the past, the criteria used to diagnose MZ were overlooked and that some cases of lymphoplasmacytic lymphoma were in fact MZL. This is supported by the fact that since pathologists have been able to diagnose MZL, the number of lymphoplasmacytic lymphomas has decreased dramatically. Alternatively, WM could be a biological syndrome that occurs during the progression of different types of small B-cell lymphoma, such as B-CLL MZL or even other types⁷⁶.

DIFFERENTIAL DIAGNOSIS

A pale ring of medium-sized cells surrounding the follicles is the key criterion for the diagnosis of MZ lymphoma in both the spleen and lymph nodes. It can be difficult to distinguish between cases of MZ hyperplasia in reactive conditions, particularly in the spleen⁷⁸ and lymph nodes (cervical, mesenteric) draining organs with MALT. The age of the patient, the clinical presentation, and the size of the spleen are very important to rule out the possibility of MZ lymphoma.

It can also be difficult to distinguish MZ lymphoma from follicular or mantle cell lymphoma with MZ differentiation^{16,79-81}. Clinical information and careful histopathological and immunohistochemical studies usually make it possible to distinguish between these lymphomas. However, in some cases, cytogenetic studies (presence or absence of a t(14; 18) or a t(11; 14) translocation) and molecular studies (presence or absence of a rearrangement of *bcl 1* or *bcl 2*) are needed. An exceptional case of a mantle cell lymphoma in blastic transformation with a MZ pattern was recently reported⁸².

Primary NMZL and even SMZL need to be distinguished from secondary involvement by an extranodal MZ MALT lymphoma^{39,54,78}. Campo *et al.*³⁹ suggested that cases of secondary involvement can be identified due to the persistence of a mantle zone and the absence of IgD expression by the tumor cells from splenic type, in which the mantle zone is missing and tumor cells are often IgD (+). In our experience, there are no histopathological or immunohistochemical criteria that can satisfactorily distinguish primary MZ from secondary involvement.

Other diagnoses should also be considered for both primary SMZL and NMZL. When the centrocytoid component is prominent, other small B-cell lymphomas, either diffuse or nodular (B-CLL, mantle cell, or lymphoplasmacytic lymphoma) should be considered. When the plasmacytic component is prominent, the diagnosis with an extra-osseous plasmacytoma or, more frequently, a lymphoplasmacytic lymphoma can be difficult. A careful histopathological study is required to detect the centrocytoid and/or monocytoid cell components. When a large B-cell component leads to the diagnosis of a

diffuse large B-cell lymphoma, the small B-cell component should not be missed, because the prognosis associated with a secondary large B-cell lymphoma is worse than that associated with a primary one. The diagnosis may be very difficult with mantle cell lymphoma in blastic progression⁸².

Finally, regressive germinal centers may mimic Castleman disease. In our cases, such follicular modifications were never prominent. Thus, we have never seen cases of MZ lymphoma associated with true Castleman disease, as recently reported^{71,72}.

GENETIC MODIFICATIONS IN NODAL AND SPLENIC MZL

Chromosomal abnormalities

The most relevant chromosomal abnormalities in MZ lymphoma are trisomy 3, t(11;18), and t(1;14)⁸³. Cytogenetic studies have identified trisomy 3 in about 15 to 60% of cases, with a similar frequency in extranodal, nodal, and splenic MZCL^{84,85}. FISH revealed trisomy 3 in between 60 and 85% of cases⁸⁵. Brynes *et al.*⁸⁶ detected trisomy 3 in 50% of nodal MZL and in only 18% of splenic MZL. The most frequent chromosomal abnormality in MALT lymphomas, t(11;18), is not observed in nodal or splenic MZ lymphomas⁸⁷⁻⁹⁰. Furthermore, t(1;14) is not found in nodal or splenic MZL.

In splenic MZL, cytogenetic findings are heterogeneous and frequently complex. Apart from complete or partial trisomy 3, abnormalities have been observed in chromosomes 1, 8, 10, and most frequently 7^{66,85,91-93} (particularly a loss of 7q 31-q 32). According to cytogenetic studies, splenic MZL is a heterogeneous tumor^{85,94,95}. It has been proposed to divide splenic MZL into two subtypes⁹¹, one showing a gain of 3q and the other a loss of 7q. In a recent CGH analysis, chromosomal imbalance of regions 3q, 4q, 7q, 9q, 12q, and 20q was observed in some patients with a shorter than average survival time⁹⁶. The switch to a DLBCL is often associated with complex cytogenetic abnormalities, including 6q-, 11q-, +12, and 17p⁹⁷.

Molecular biology

Tumor suppressor genes such as p 53, RB, and p 16 are rarely deleted in both nodal and splenic MZL, in contrast to other lymphomas^{63,98}. Mutational analysis of the rearranged V_H genes has revealed somatic mutations in all types of MZCL. IgV_H gene analysis demonstrated the heterogeneous nature of neoplastic cells. In some patients, the cells have unmutated genes, suggesting the presence of naive B-cells^{95,99}. In other cases, the neoplastic cells show somatic mutations as in post-GC B-cells^{95,99-102}, which could be memory B-cells. In one case¹⁰³, it has been possible to show the

switch from unmutated to hypermutated elements in the same neoplastic clone. The presence of these somatic mutations may suggest an antigen-mediated selective pressure^{9,103-105}. Rearrangements most commonly affect V_H4, V_H3, and V_H1 family genes, with an over-representation of some particular V_H genes that seem to be frequently involved in autoantibody production. This suggests that (auto)antigen stimulation plays a role in lymphomagenesis^{19,100}.

In nodal MZBCL, as in splenic MZL, no characteristic cytogenetic alterations have been found⁸⁵. However, the observed pattern of V_H mutations suggests that the malignant cells are not only memory B-cells, but also belong to different subsets of MZ B-cells: naive B-cells expressing unmutated V_H genes, memory B-cells showing somatic mutations without intraclonal variation, and germinal center B-cells able to undergo somatic hypermutation¹⁰⁵.

A high-density microarray study of 128 primary non-germinal center small B-cell lymphomas⁶⁷ showed that transcriptional profiles can be used to distinguish between all MZ lymphoma samples, B-CLL samples, and most mantle cell lymphoma samples. Only a few cases of mantle cell lymphoma exhibit MZ lymphoma-type transcriptional profiles. In the future, these profiles may be relevant for diagnosis and help us to understand the pathogenesis of these lymphomas. Genes associated with intracellular signaling via the AKT1 pathway are upregulated in SMZL.

ETIOLOGY

Chronic gastritis due to *Helicobacter pylori* plays an important role in the development of gastric MALT lymphoma. Autoimmune conditions, such as Sjögren's syndrome or Hashimoto's thyroiditis, seem to play a role in the development of salivary gland or thyroid MALT lymphomas. Other infections linked with other MZCL will probably be discovered in the future. Recently, it was suggested that chronic hepatitis C virus (HCV) infection may be involved in the development of lymphomas, particularly MZCL^{106,107}. It has been shown that eradication of HCV infection in SMZL patients with villous lymphocytes is followed by regression of the lymphoma. Additional factors (host, genetic, environmental) may also play a role in lymphomagenesis.

TREATMENT

There are numerous treatment options¹⁰⁸. For example, SMZL can be treated by splenectomy⁴⁹, chemotherapy⁴⁹, purine analogs, anti-CD20, or interferon. Alternatively, watchful waiting can be adopted. Most NMZL patients receive chemotherapy. The usefulness of purine analogs and anti-CD20 immunotherapy needs to be evaluated in prospective trials, as do new treatments¹⁰⁸.

ACKNOWLEDGMENT

We thank Mr. Lionel Poursac for providing photographs.

REFERENCES

- 1 Jaffe ES, Harris N, Stein H, Vardiman JW : Tumours of hematopoietic and lymphoid tissues. International Agency For Research on Cancer. 2001.
- 2 Snook T : Studies on the perifollicular region of therat's spleen. *Anat Rec* 148 : 149-59, 1964.
- 3 Weidenreich F : Das Gefäss-System der menschlichen Milz. *Arch Mikroskopische Anat* 58 : 247-376, 1901.
- 4 Kumaratne DS, Bazin H, MacLennan ICM : Marginal zones : the major B cell compartment in rats spleens. *Eur J Immunol* 11 : 858-864, 1981.
- 5 Van Krieken JHJM, te Velde J : Normal histology of the human spleen. *Am J Surg Pathol* 12 : 777-785, 1988.
- 6 Isaacson PG, Wright DH : Extranodal malignant lymphoma arising from mucosa-associated lymphoid tissue. *Cancer* 53 : 2515-2524, 1984.
- 7 Van den Ord J, De Wolf-Peeters C, Desmet V : The marginal zone in the human reactive lymph node. *Am J Clin Pathol* 86 : 475-479, 1986.
- 8 Van Krieken JHJM, von Schilling C, Kluin PM, Lennert K : Splenic marginal zone lymphocytes and related cells in the lymph node : a morphological and immunohisto-chemical study. *Hum Pathol* 20 : 320-325, 1989.
- 9 Pileri SA, Zinzani PL, Went P, Pileri A Jr, Bendandi M : Indolent lymphoma : the pathologist's viewpoint. *Ann Oncol* 15 : 12-18, 2004.
- 10 Spencer J, Perry ME, Dunn-Walters DK : Human marginal zone B-cells. *Immunol Today* 19 : 421-426, 1998.
- 11 Feller AC, Diebold J : Histopathology of nodal and extranodal non-Hodgkin's lymphomas. Vol. I Springer, Heidelberg, 2003.
- 12 Lennert K : Diagnose und Aetiologie der Píringerschen Lymphadenitis. *Verh Dtsch Ges Path* 42 : 203-208, 1959.
- 13 Stein H, Lennert K, Mason DY, Liangru S, Ziegler A : Immature sinus histiocytes. Their identification as a novel B-cell population. *Am J Pathol* 117 : 44-52, 1984.
- 14 Sheibani K, Fritz RM, Winberg CD, Burke JS, Rappaport H : "Monocytoid" cells in reactive follicular hyperplasia with and without multifocal histiocytic reactions : an immunohistochemical study of 21 cases including suspected cases of toxoplasmic lymphadenitis. *Am J Clin Pathol* 81 : 453-458, 1984.
- 15 MacLennan ICM, Gray D, Kumaratne DS, Bazin H : The lymphocytes of splenic marginal zones : a distinct B-cell lineage. *Immunol Today* 3 : 305-307, 1982.
- 16 Schmid U, Cogliatti SB, Diss TC, Isaacson PG : Monocytoid/marginal zone B-cell differentiation in follicle centre cell lymphoma. *Histopathology* 29 : 201-208, 1996.
- 17 Kurtin PJ : Marginal zone B cells, monocytoid B cells, and the follicular microenvironment. Determinants of morphologic features in a subset of low-grade B-cell lymphomas. *Am J Clin Pathol* 114 : 505-508, 2000.
- 18 Camacho FI, Garcia JF, Sanchez-Verde L, Saez AI, Sanchez-Beato M, Mollejo M, Piris MA : Unique phenotypic profile of monocytoid B cells : differences in comparison with the phenotypic profile observed in marginal zone B cells and so-called monocytoid B cell lymphoma. *Am J Pathol* 158 : 1363-1369, 2001.
- 19 Maes B, De Wolf-Peeters C : Marginal zone cell lymphoma—an update on recent advances. *Histopathology* 40 : 117-126, 2002.
- 20 Amlot PL, Grennan D, Humphrey JH : Splenic dependence of the antibody response to thymus-independent (TI-2) antigens. *Eur J Immunol* 15 : 508-512, 1985.
- 21 Liu YJ, Oldfield S, MacLennan IC : Memory B cells in T cell-dependent antibody responses colonize the splenic marginal zones. *Eur J Immunol* 18 : 355-362, 1988.
- 22 Dunn-Walters DK, Isaacson PG, Spencer J : Analysis of mutations in immunoglobulin heavy chain variable region genes of microdissected marginal zone (MGZ) B cells suggests that the MGZ of human spleen is a reservoir of memory B cells. *J Exp Med* 182 : 559-566, 1995 1.
- 23 Stein K, Hummel M, Korbjuhn P, Foss HD, Anagnostopoulos I, Marafioti T, Stein H : Monocytoid B cells are distinct from splenic marginal zone cells and commonly derive from unmutated naive B cells and less frequently from postgerminal center B cells by polyclonal transformation. *Blood* 94 : 2800-2808, 1999.
- 24 Guinamard R, Okigaki M, Schlessinger J, Ravetch JV : Absence of marginal zone B cells in Pyk-2-deficient mice defines their role in the humoral response. *Nat Immunol* 1 : 31-36, 2000.
- 25 Cariappa A, Liou HC, Horwitz BH, Pillai S : Nuclear factor kappa B is required for the development of marginal zone B lymphocytes. *J Exp Med* 192 : 1175-1182, 2000.
- 26 Cousar JB, Mc Kee LC, Greco FA, Grick AD, Corrins RD : Report of an unusual B-cell lymphoma probably arising from perifollicular cells (marginal zone) of the spleen (abstract). *Lab Invest* 42 : 109, 1980.
- 27 Schmid U, Helbron D, Lennert K : Development of malignant lymphoma in myoepithelial sialadenitis (Sjögrens syndrome). *Virchow's Arch A* 395 : 11-43, 1982.
- 28 Sheibani K, Sohn CC, Burke JS, Winberg CD, Wu AM, Rappaport H : Monocytoid B-cell lymphoma. A novel B-cell neoplasm. *Am J Pathol* 124 : 310-318, 1986.
- 29 Cousar JB, McGinn DL, Glick AD, List AF, Collins RD : Report of an unusual lymphoma arising from parafollicular B-lymphocytes (PBLs) or so-called "monocytoid" lymphocytes. *Am J Clin Pathol* 87 : 121-128, 1987.
- 30 Ng CS, Chan JK : Monocytoid B-cell lymphoma. *Hum Pathol* 18 : 1069-1071, 1987.
- 31 Sheibani K, Burke JS, Swartz WG, Nademanee A, Winberg CD : Monocytoid B-cell lymphoma. Clinicopathologic study of 21 cases of a unique type of low-grade lymphoma. *Cancer* 62 : 1531-1538, 15, 1988.
- 32 Piris MA, Rivas C, Morente M, Cruz MA, Rubio C, Oliva H :

- Monocytoid B-cell lymphoma, a tumour related to the marginal zone. *Histopathology* 12 : 383-392, 1988.
- 33 Cogliatti SB, Lennert K, Hansmann ML, Zwingers TL : Monocytoid B cell lymphoma : clinical and prognostic features of 21 patients. *J Clin Pathol* 43 : 619-625, 1990.
 - 34 Nizze H, Cogliatti SB, von Schilling C, Feller AC, Lennert K : Monocytoid B-cell lymphoma : morphological variants and relationship to low-grade B-cell lymphoma of the mucosa-associated lymphoid tissue. *Histopathology* 18 : 403-414, 1991.
 - 35 Nathwani BN, Mohrmann RL, Brynes RK, Taylor CR, Hansmann ML, Sheibani K : Monocytoid B-cell lymphomas : an assessment of diagnostic criteria and a perspective on histogenesis. *Hum Pathol* 23 : 1061-1071, 1992.
 - 36 Nathwani BN, Anderson JR, Armitage JO, Cavalli F, Diebold J, Drachenberg MR, Harris NL, MacLennan KA, Muller-Hermelink HK, Ullrich FA, Weisenburger DD : Marginal zone B-cell lymphoma : A clinical comparison of nodal and mucosa-associated lymphoid tissue types. *Non-Hodgkin's Lymphoma Classification Project. J Clin Oncol* 17 : 2486-2492, 1999.
 - 37 Nathwani BN, Drachenberg MR, Hernandez AM, Levine AM, Sheibani K : Nodal monocytoid B-cell lymphoma (nodal marginal-zone B-cell lymphoma). *Semin Hematol* 36 : 128-138, 1999.
 - 38 Ortiz-Hidalgo C, Wright DH : The morphological spectrum of monocytoid B-cell lymphoma and its relationship to lymphomas of mucosa-associated lymphoid tissue. *Histopathology* 21 : 555-561, 1992.
 - 39 Campo E, Miquel R, Krenacs L, Sorbara L, Raffeld M, Jaffe ES : Primary nodal marginal zone lymphomas of splenic and MALT type. *Am J Surg Pathol* 23 : 59-68, 1999.
 - 40 Nathwani BN, Drachenberg MR, Hernandez AM : Primary nodal marginal zone lymphomas of splenic and MALT type. *Am J Surg Pathol* 24 : 317-319, 2000.
 - 41 Schmid C, Kirkham N, Diss T, Isaacson PG : Splenic marginal zone cell lymphoma. *Am J Surg Pathol* 16 : 455-466, 1992.
 - 42 Audouin J, Diebold J, Schvartz H, Le Tourneau A, Bernadou A, Zittoun R : Malignant lymphoplasmacytic lymphoma with prominent splenomegaly (primary lymphoma of the spleen). *J Pathol* 155 : 17-33, 1988.
 - 43 Pawade J, Wilkins BS, Wright DH : Low-grade B-cell lymphomas of the splenic marginal zone : a clinicopathological and immunohistochemical study of 14 cases. *Histopathology* 27 : 129-137, 1995.
 - 44 Rosso R, Neiman RS, Paulli M, Boveri E, Kindl S, Magrini U, Barosi G : Splenic marginal zone cell lymphoma : report of an indolent variant without massive splenomegaly presumably representing an early phase of the disease. *Hum Pathol* 26 : 39-46, 1995.
 - 45 Mollejo M, Menarguez J, Lloret E, Sanchez A, Campo E, Algara P, Cristobal E, Sanchez E, Piris MA : Splenic marginal zone lymphoma : a distinctive type of low-grade B-cell lymphoma. A clinicopathological study of 13 cases. *Am J Surg Pathol* 19 : 1146-1157, 1995.
 - 46 Hammer RD, Glick AD, Greer JP, Collins RD, Cousar JB : Splenic marginal zone lymphoma. A distinct B-cell neoplasm. *Am J Surg Pathol* 20 : 613-626, 1996.
 - 47 Wu CD, Jackson CL, Medeiros LJ : Splenic marginal zone cell lymphoma. An immunophenotypic and molecular study of five cases. *Am J Clin Pathol* 105 : 277-285, 1996.
 - 48 Pittaluga S, Verhoef G, Criel A, Wlodarska I, Dierlamm J, Mecucci C, Van den Berghe H, De Wolf-Peeters C : "Small" B-cell non-Hodgkin's lymphomas with splenomegaly at presentation are either mantle cell lymphoma or marginal zone cell lymphoma. A study based on histology, cytology, immunohistochemistry, and cytogenetic analysis. *Am J Surg Pathol* 20 : 211-223, 1996.
 - 49 Van Huyen JP, Molina T, Delmer A, Audouin J, Le Tourneau A, Zittoun R, Bernadou A, Diebold J : Splenic marginal zone lymphoma with or without plasmacytic differentiation. *Am J Surg Pathol* 24 : 1581-1592, 2000.
 - 50 Franco V, Florena AM, Iannitto E : Splenic marginal zone lymphoma. *Blood* 101 : 2464-2472, 2003.
 - 51 Melo JV, Hegde U, Parreira A, Thompson I, Lampert IA, Catovsky D : Splenic B cell lymphoma with circulating villous lymphocytes : differential diagnosis of B cell leukaemias with large spleens. *J Clin Pathol* 40 : 642-651, 1987.
 - 52 Melo JV, Robinson DS, Gregory C, Catovsky D : Splenic B cell lymphoma with "villous" lymphocytes in the peripheral blood : a disorder distinct from hairy cell leukemia. *Leukemia* 1 : 294-298, 1987.
 - 53 Isaacson PG, Matutes E, Burke M, Catovsky D : The histopathology of splenic lymphoma with villous lymphocytes. *Blood* 84 : 3828-3834, 1994.
 - 54 Isaacson PG : Splenic marginal zone lymphoma. *Blood* 88 : 751-752, 1996.
 - 55 Rousselet MC, Gardembas-Pain M, Renier G, Chevailler A, Ifrah N : Splenic lymphoma with circulating villous lymphocytes. Report of a case with immunologic and ultrastructural studies. *Am J Clin Pathol* 97 : 147-152, 1992.
 - 56 Harris NL, Jaffe ES, Stein H, Banks PM, Chan JK, Cleary ML, Delsol G, De Wolf-Peeters C, Falini B, Gatter KC : A revised European-American classification of lymphoid neoplasms : a proposal from the International Lymphoma Study Group. *Blood* 84 : 1361-1392, 1994.
 - 57 Franco V, Florena AM, Campesi G : Intrasinusoidal bone marrow infiltration : a possible hallmark of splenic lymphoma. *Histopathology* 29 : 571-575, 1996.
 - 58 Berger F, Felman P, Thieblemont C, Pradier T, Baseggio L, Bryon PA, Salles G, Callet-Bauchu E, Coiffier B : Non-MALT marginal zone B-cell lymphomas : a description of clinical presentation and outcome in 124 patients. *Blood* 95 : 1950-1956, 2000.
 - 59 Kent SA, Variakojis D, Peterson LC : Comparative study of marginal zone lymphoma involving bone marrow. *Am J Clin Pathol* 117 : 698-708, 2002.
 - 60 Audouin J, Le Tourneau A, Molina T, Camilleri-Broet S, Adida C, Comperat E, Benattar L, Delmer A, Devidas A, Rio B, Diebold J : Patterns of bone marrow involvement in 58 patients presenting

- primary splenic marginal zone lymphoma with or without circulating villous lymphocytes. *Br J Haematol* 122 : 404-412, 2003.
- 61 Le Tourneau A, Compérat E, Devidas A, Adida C, Camillei-Broet S, Molina T, Diebold J, Audouin J : Different patterns of bone marrow involvement in primary nodal marginal zone lymphoma (monocytoid B-cell lymphoma). A report of 3 cases. *Recent Advances and Research Updates*, 3, No. 2 : 175-186, 2002.
- 62 Sun T, Susin M, Brody J, Dittmar K, Teichberg S, Weiner R, Lin JH, Felber N : Splenic lymphoma with circulating villous lymphocytes : report of seven cases and review of the literature. *Am J Hematol* 45 : 39-50, 1994.
- 63 Mollejo M, Lloret E, Menarguez J, Piris MA, Isaacson PG : Lymph node involvement by splenic marginal zone lymphoma : morphological and immunohistochemical features. *Am J Surg Pathol* 21 : 772-780, 1997.
- 64 Franco V, Florena AM, Ascani S, Paulli M, Salvato M, Pileri SA : CD 27 distinguishes two phases in bone marrow infiltration of splenic marginal zone lymphoma *Histopathology* 44 : 381-386, 2004.
- 65 Finch CN, Nichols M, Shrimpton A, Liu D, Hutchison RE : Primary nodal marginal zone B-cell lymphoma arising from more than one clonal neoplastic population. *Arch Pathol Lab Med* 124 : 1816-1819, 2000.
- 66 Camacho FI, Mollejo M, Mateo MS, Algara P, Navas C, Hernandez JM, Santoja C, Sole F, Sanchez-Beato M, Piris MA : Progression to large B-cell lymphoma in splenic marginal zone lymphoma : a description of a series of 12 cases. *Am J Surg Pathol* 25 : 1268-1276, 2001.
- 67 Thieblemont C, Nasser V, Felman P, Leroy K, Gazzo S, Callet-Bauchu E, Loriod B, Granjeaud S, Gaulard P, Haioun C, Traverse-Glehen A, Baseggio L, Bertucci F, Birnbaum D, Magrangeas F, Minvielle S, Avet-Loiseau H, Salles G, Coiffier B, Berger F, Houlgatte R : Small lymphocytic lymphoma, marginal zone B-cell lymphoma, and mantle cell lymphoma exhibit distinct gene-expression profiles allowing molecular diagnosis. *Blood* 103 : 2727-2737, 2004.
- 68 Chacon JI, Mollejo M, Munoz E, Algara P, Mateo M, Lopez L, Andrade J, Carbonero IG, Martinez B, Piris MA, Cruz MA : Splenic marginal zone lymphoma : clinical characteristics and prognostic factors in a series of 60 patients. *Blood* 100 : 1648-1654, 2002.
- 69 The Non-Hodgkin's Lymphoma Classification Project : A clinical evaluation of the International Lymphoma Study Group classification of non-Hodgkin's lymphoma. *Blood* 89 : 3909-3918, 1997.
- 70 Tadesse-Heath L, Pittaluga S, Sorbara L, Bussey M, Raffeld M, Jaffe ES : Marginal zone B-cell lymphoma in children and young adults. *Am J Surg Pathol* 27 : 522-531, 2003.
- 71 Kojima M, Nakamura S, Shimizu K, Suda Y, Kasuga Y, Sugihara S, Sakata N, Masawa N : Nodal marginal zone B-cell lymphoma resembling plasmacytoma arising from a plasma cell variant of localized Castleman's disease : a case report. *APMIS* 110 : 523-527, 2002.
- 72 Kojima M, Nakamura S, Motoori T, Shimano S, Murayama K, Tamaki Y, Shimizu K, Oyama T, Sugihara S, Sakata N, Masawa N : Primary marginal zone B-cell lymphoma of the lymph node resembling plasmacytoma arising from a plasma cell variant of Castleman's disease. A clinicopathological and immunohistochemical study of seven patients. *APMIS* 110 : 875-880, 2002.
- 73 Cualing H, Steele P, Zellner D : Blastic transformation of splenic marginal zone B-cell lymphoma. *Arch Pathol Lab Med* 124 (5) : 748-752, 2000.
- 74 Labouyrie E, Marit G, Vial JP, Lacombe F, Fialon P, Bernard P, de Mascarel A, Merlio JP : Intrasinusoidal bone marrow involvement by splenic lymphoma with villous lymphocytes : a helpful immunohistologic feature. *Mod Pathol* 10 : 1015-1020, 1997.
- 75 Franco V, Florena AM, Stella M, Rizzo A, Iannitto E, Quintini G, Campesi G : Splenectomy influences bone marrow infiltration in patients with splenic marginal zone cell lymphoma with or without villous lymphocytes. *Cancer* 91 : 294-301, 2001.
- 76 Diebold J, Molina T, Tissier F, le Tourneau A, Audouin J : Waldenstrom's macroglobulinemia is a biological syndrome which may occur during the evolution of different types of low grade B cell lymphoma. *Leukemia* 13 : 1637-1638, 1999.
- 77 Allez M, Mariette X, Linares G, Bertheau P, Jian R, Brouet JC : Low-grade MALT lymphoma mimicking Waldenstrom's macroglobulinemia. *Leukemia* 13 : 484-485, 1999.
- 78 Harris S, Wilkins BS, Jones DB : Splenic marginal zone expansion in B-cell lymphomas of gastrointestinal mucosa-associated lymphoid tissue (MALT) is reactive and does not represent homing of neoplastic lymphocytes. *J Pathol* 179 : 49-53, 1996.
- 79 Alkan S, Ross CW, Hanson CA, Schnitzer B : Follicular lymphoma with involvement of the splenic marginal zone : a pitfall in the differential diagnosis of splenic marginal zone cell lymphoma. *Hum Pathol* 27 : 503-506, 1996.
- 80 Nathwani BN, Anderson JR, Armitage JO, Cavalli F, Diebold J, Drachenberg MR, Harris NL, MacLennan KA, Muller-Hermelink HK, Ullrich FA, Weisenburger DD : Clinical significance of follicular lymphoma with monocytoid B cells. Non-Hodgkin's Lymphoma Classification Project. *Hum Pathol* 30 : 263-268, 1999.
- 81 Kansal R, Ross CW, Singleton TP, Finn WG, Schnitzer B : Histopathologic features of splenic small B-cell lymphomas. A study of 42 cases with a definitive diagnosis by the World Health Organization classification. *Am J Clin Pathol* 120 : 335-347, 2003.
- 82 Mollejo M, Lloret E, Solares J, Bergua JM, Mateo M, Piris MA : Splenic involvement by blastic mantle cell lymphoma (large cell/anaplastic variant) mimicking splenic marginal zone lymphoma. *Am J Hematol* 62 : 242-246, 1999.
- 83 Dierlamm J, Pittaluga S, Wlodarska I, Stul M, Thomas J, Boogaerts M, Michaux L, Driessen A, Mecucci C, Cassiman JJ, De Wolf Peeters C, Van den Berghe H : Marginal zone B-cell lymphomas of different sites share similar cytogenetic and morphologic features. *Blood* 87 : 299-307, 1996.
- 84 Dierlamm J, Michaux L, Wlodarska I, Pittaluga S, Zeller W, Stul M, Criel A, Thomas J, Boogaerts M, Delaere P, Cassiman JJ, de Wolf-Peeters C, Mecucci C, Van den Berghe H : Trisomy 3 in marginal zone B-cell lymphoma : a study based on cytogenetic

- analysis and fluorescence in situ hybridization. *Br J Haematol* 93 : 242-249, 1996.
- 85 Ott MM, Rosenwald A, Katzenberger T, Dreyling M, Krumdiek AK, Kalla J, Greiner A, Ott G, Muller-Hermelink HK : Marginal zone B-cell lymphomas (MZBL) arising at different sites represent different biological entities. *Genes Chromosomes Cancer* 28 : 380-386, 2000.
- 86 Brynes RK, Almaguer PD, Leathery KE, McCourty A, Arber DA, Medeiros LJ, Nathwani BN : Numerical cytogenetic abnormalities of chromosomes 3, 7, and 12 in marginal zone B-cell lymphomas. *Mod Pathol* 9 : 995-1000, 1996.
- 87 Baens M, Maes B, Steyls A, Geboes K, Marynen P, De Wolf-Peeters C : The product of the t (11 ; 18), an API 2-MLT fusion, marks nearly half of gastric MALT type lymphomas without large cell proliferation. *Am J Pathol* 156 : 1433-1439, 2000.
- 88 Maes B, Baens M, Marynen P, De Wolf-Peeters C : The product of the t (11 ; 18), an API 2-MLT fusion, is an almost exclusive finding in marginal zone cell lymphoma of extranodal MALT-type. *Ann Oncol* 11 : 521-526, 2000.
- 89 Rosenwald A, Ott G, Stilgenbauer S, Kalla J, Bredt M, Katzenberger T, Greiner A, Ott MM, Gawin B, Dohner H, Muller-Hermelink HK : Exclusive detection of the t (11 ; 18) (q 21 ; q 21) in extranodal marginal zone B cell lymphomas (MZBL) of MALT type in contrast to other MZBL and extranodal large B cell lymphomas. *Am J Pathol* 155 : 1817-1821, 1999.
- 90 Remstein ED, James CD, Kurtin PJ : Incidence and subtype specificity of API 2-MALT 1 fusion translocations in extranodal, nodal, and splenic marginal zone lymphomas. *Am J Pathol* 156 : 1183-1188, 2000.
- 91 Sole F, Woessner S, Florensa L, Espinet B, Mollejo M, Martin P, Piris MA : Frequent involvement of chromosomes 1, 3, 7 and 8 in splenic marginal zone B-cell lymphoma. *Br J Haematol* 98 : 446-449, 1997.
- 92 Dierlamm J, Rosenberg C, Stul M, Pittaluga S, Wlodarska I, Michaux L, Dehaen M, Verhoef G, Thomas J, de Kelver W, Bakker-Schut T, Cassiman JJ, Raap AK, De Wolf-Peeters C, Van den Berghe H, Hagemeijer A : Characteristic pattern of chromosomal gains and losses in marginal zone B cell lymphoma detected by comparative genomic hybridization. *Leukemia* 11 : 747-758, 1997.
- 93 Mateo M, Mollejo M, Villuendas R, Algara P, Sanchez-Beato M, Martinez P, Piris MA : 7 q 31-32 allelic loss is a frequent finding in splenic marginal zone lymphoma. *Am J Pathol* 154 : 1583-1589, 1999.
- 94 Sole F, Salido M, Espinet B, Garcia JL, Martinez Climent JA, Granada I, Hernandez JM, Benet I, Piris MA, Mollejo M, Martinez P, Vallespi T, Domingo A, Serrano S, Woessner S, Florensa L : Splenic marginal zone B-cell lymphomas : two cytogenetic subtypes, one with gain of 3 q and the other with loss of 7 q. *Haematologica* 86 : 71-77, 2001.
- 95 Algara P, Mateo MS, Sanchez-Beato M, Mollejo M, Navas IC, Romero L, Sole F, Salido M, Florensa L, Martinez P, Campo E, Piris MA : Analysis of the IgV (H) somatic mutations in splenic marginal zone lymphoma defines a group of unmutated cases with frequent 7 q deletion and adverse clinical course. *Blood* 99 : 1299-1304, 2002.
- 96 Hernandez JM, Garcia JL, Gutierrez NC, Mollejo M, Martinez-Climent JA, Flores T, Gonzalez MB, Piris MA, San Miguel JF : Novel genomic imbalances in B-cell splenic marginal zone lymphomas revealed by comparative genomic hybridization and cytogenetics. *Am J Pathol* 158 : 1843-1850, 2001.
- 97 Cuneo A, Bigoni R, Roberti MG, Milani R, Agostini P, Cavazzini F, Minotto C, De Angeli C, Bardi A, Tammiso E, Negrini M, Cavazzini P, Castoldi G : Molecular cytogenetic characterization of marginal zone B-cell lymphoma : correlation with clinicopathologic findings in 14 cases. *Haematologica* 86 : 64-70, 2001.
- 98 Dierlamm J, Stefanova M, Wlodarska I, Hinz K, Maes B, Michaux L, Stul M, Verhoef G, Thomas J, De Wolf-Peeters C, Van den Berghe H, Hossfeld DK, Hagemeijer A : Analysis of the P 53, RB/D 13 S 25, and P 16 tumor suppressor genes in marginal zone B-cell lymphoma : An interphase fluorescence in situ hybridization study. *Cancer Genet Cytogenet* 120 : 1-5, 2000.
- 99 Bahler DW, Pindzola JA, Swerdlow SH : Splenic marginal zone lymphomas appear to originate from different B cell types. *Am J Pathol* 161 : 81-88, 2002.
- 100 Tierens A, Delabie J, Pittaluga S, Driessen A, DeWolf-Peeters C : Mutation analysis of the rearranged immunoglobulin heavy chain genes of marginal zone cell lymphomas indicates an origin from different marginal zone B lymphocyte subsets. *Blood* 91 : 2381-2386, 1998.
- 101 Dunn-Walters DK, Boursier L, Spencer J, Isaacson PG : Analysis of immunoglobulin genes in splenic marginal zone lymphoma suggests ongoing mutation. *Hum Pathol* 29 : 585-593, 1998.
- 102 Miranda RN, Cousar JB, Hammer RD, Collins RD, Vnencak-Jones CL : Somatic mutation analysis of IgH variable regions reveals that tumor cells of most parafollicular (monocytoid) B-cell lymphoma, splenic marginal zone B-cell lymphoma, and some hairy cell leukemia are composed of memory B lymphocytes. *Hum Pathol* 30 : 306-312, 1999.
- 103 Zhu D, Oscier DG, Stevenson FK : Splenic lymphoma with villous lymphocytes involves B cells with extensively mutated Ig heavy chain variable region genes. *Blood* 85 : 1603-1607, 1995.
- 104 Kuppers R, Hajadi M, Plank L, Rajewsky K, Hansmann ML : Molecular Ig gene analysis reveals that monocytoid B cell lymphoma is a malignancy of mature B cells carrying somatically mutated V region genes and suggests that rearrangement of the kappa-deleting element (resulting in deletion of the Ig kappa enhancers) abolishes somatic hypermutation in the human. *Eur J Immunol* 26 : 1794-1800, 1996.
- 105 Conconi A, Bertoni F, Pedrinis E, Motta T, Roggero E, Luminari S, Capella C, Bonato M, Cavalli F, Zucca E : Nodal marginal zone B-cell lymphomas may arise from different subsets of marginal zone B lymphocytes. *Blood* 98 : 781-786, 2001.
- 106 Zuckerman E, Zuckerman T, Levine AM, Douer D, Gutekunst K, Mizokami M, Qian DG, Velankar M, Nathwani BN, Fong TL : Hepatitis C virus infection in patients with B-cell non-Hodgkin

- lymphoma. *Ann Intern Med* 127 : 423-428, 1997.
- 107 Marasca R, Vaccari P, Luppi M, Zucchini P, Castelli I, Barozzi P, Cuoghi A, Torelli G : Immunoglobulin gene mutations and frequent use of VH 1-69 and VH 4-34 segments in hepatitis C virus-positive and hepatitis C virus-negative nodal marginal zone B-cell lymphoma. *Am J Pathol* 159 : 253-261, 2001.
- 108 Arcaini L, Pauli M, Boveri E, Magrini U, Lazzarino M : Marginal zone-related neoplasms of splenic and nodal origin. *Haematologica* 88 : 80-93, 2003.