

Case Study

Spontaneous Regression of Diffuse Large B-Cell Lymphoma Harbouring Epstein-Barr Virus : A Case Report and Review of the Literature

Rokuo Abe^{1,2)}, Kazuei Ogawa^{1,2)}, Yukio Maruyama²⁾, Naoya Nakamura^{3,4)}, and Masafumi Abe³⁾

We report an elderly patient with diffuse large B cell lymphoma harbouring Epstein-Barr virus that showed spontaneous regressions with subsequent relapses three times. The patient died of aspiration pneumonia without any anti-neoplastic treatment 5 years 10 months after the initial onset of lymph node swelling. In the literature, there are several reports of aggressive non-Hodgkin's lymphoma cases that showed spontaneous regressions without relapse till the last observation. Over half of the cases were the extra-nodal type. The tendency toward regression of swollen lymph nodes detected by clinicians occurs within 2 weeks after biopsy. If the remaining lymph nodes show a tendency to decrease in size after biopsy without any anti-tumor therapies, the patient may develop spontaneous regression. [*J Clin Exp Hematopathol* 47(1) : 23-26, 2007]

Keywords: diffuse large B-cell lymphoma, EB virus associated lymphoma, spontaneous regression

INTRODUCTION

Although spontaneous regression (SR) in patients with low-grade lymphoma has been reported to occur in 5 to 15 percents of patients^{1,2)}, aggressive non-Hodgkin's lymphoma (NHL) cases showing SR are extremely rare³⁻¹⁶⁾. We report here a case of diffuse large B cell lymphoma (DLBCL) harboring Epstein-Barr virus (EBV) that showed SR in the absence of any anti-neoplastic treatment. EBV-associated lymphoproliferative disorders (LPDs) without immunodeficiency mainly occurs in elderly patients¹⁷⁾. Recent studies suggested that EBV may be a causative factor for good prognosis of sporadic Burkitt lymphoma with granulomatous reaction^{18,19)}. Aggressive NHL cases showing SR are reviewed in the literature.

CASE REPORT

An 89-year-old man consulted to our hospital with a swollen left inguinal lymph node (LN) measuring 40 mm in

diameter. The swollen LN was slightly tender. Physical examinations did not detect any other swollen LN or hepatosplenomegaly. Laboratory data including hematological and biochemical studies were unremarkable. The initial diagnosis was granulomatous lymphadenitis (GL). Postmortem immunostains of the first biopsy specimens were positive for CD20 and anti-Ig κ antibody, but negative for CD3, CD5, CD10 and anti-EBV antibody. The anti-Ig λ antibody was also negative. The pathological diagnosis of the first biopsy was corrected from GL to lymphoplasmacytoid lymphoma (Fig. 1). The swollen LN was removed by biopsy and there were no palpable LN for about 34 months (Fig. 2). Two years 10 months later, painful left inguinal and supraclavicular LN swellings were recognized, and measuring 20 x 40 and 40 x 40 mm, respectively. Serum M-protein appeared and the serum γ -globulin level was about 30%. Three years 2 months later, serum γ -globulin level increased to 45%. Extreme elevation of serum IgA (3,800 mg/dl), and normal levels of IgG (950 mg/dl) and IgM (95 mg/dl) were detected. Thrombocytopenia (70,000/ μ l) was observed. Bone marrow (BM) smears showed an increased percentage of plasma cells (11%) and hypoplastic megakaryocytes without adhesions of platelets. Laboratory data did not show any anemia and there were no abnormal findings on x-ray films of the whole body. Three years 8 months later, M-protein disappeared. Pathological examination of the second biopsy of the left inguinal LN demonstrated DLBCL with severe pleomorphism (Fig. 3). Lymphoma cells did not show a tendency of a differentiation to plasma cells. Immunohistochemical markers of LN cells were positive for CD20, CD30, MUM-1,

Received : Jun 14, 2006

Accepted : Oct 2, 2006

¹⁾ Department of Internal Medicine, Fukushima-ken Taiyoh-no-kuni Hospital, Fukushima, Japan

²⁾ First Department of Internal Medicine, Fukushima Medical University, Fukushima, Japan

³⁾ First Department of Pathology, Fukushima Medical University, Fukushima, Japan

⁴⁾ Current address : Department of Pathology, Tokai University School of Medicine, Isehara, Japan

Address correspondence and reprint request to Yukio Maruyama, First Department of Internal Medicine, Fukushima Medical University

1 Hikarigaoka, Fukushima 960-1295 Japan

E-mail : r-abe@silver.plala.or.jp

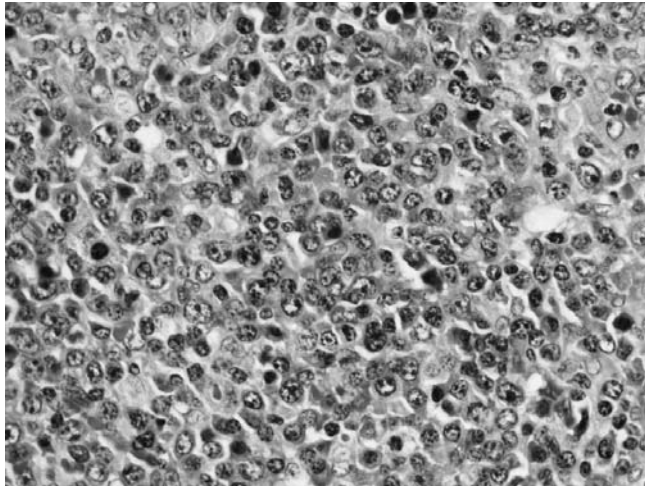


Fig. 1. Lymphoplasmacytoid lymphoma at the first lymph node biopsy. HE, x200.

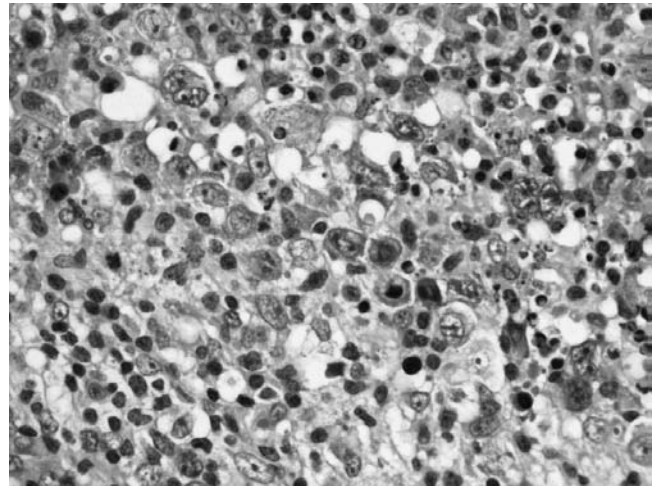


Fig. 3. Diffuse large B-cell lymphoma with severe nuclear pleomorphism at the second lymph node biopsy. HE, x200

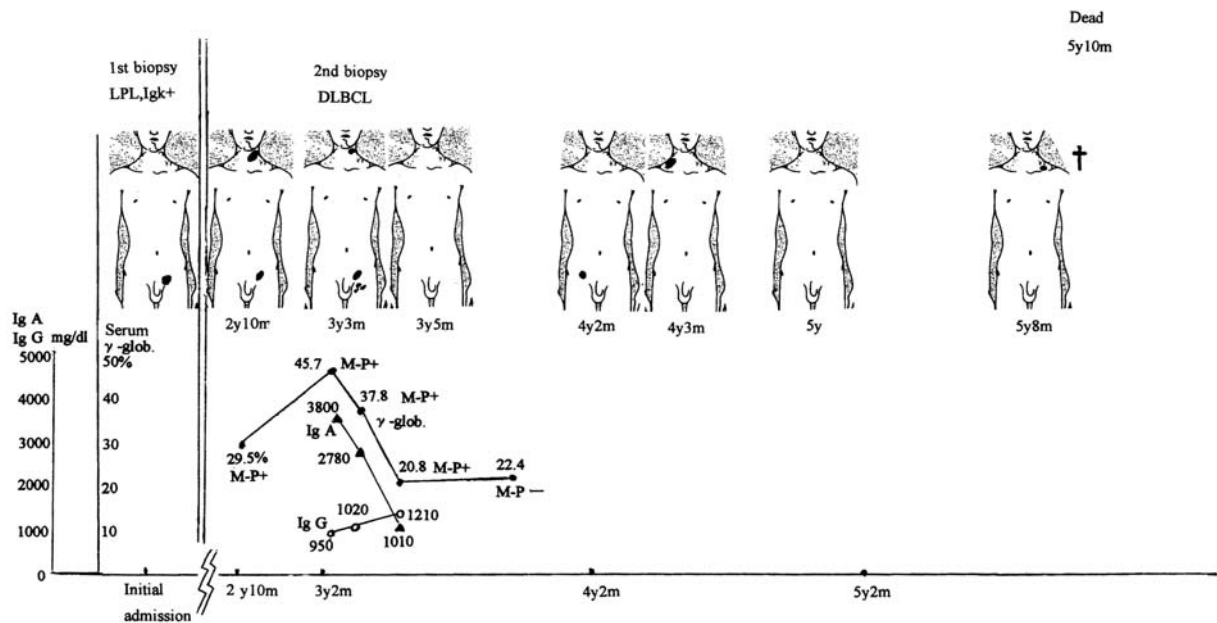


Fig. 2. Clinical course of lymph node swellings and serum M protein.

Oct-2, Bob-1 and EBV-encoded latent membrane protein-1, and negative for CD3, CD5, CD10, CD15, Bcl-6 and EBV nuclear antigen 2. RNA *in situ* hybridization with the EBV-encoded small nuclear early region-1 probe demonstrated that the lymphoma cells harboured to EBV. Fifty-five days after the second biopsy, the swollen LNs decreased in size. After another five days, LN swelling disappeared completely. Thereafter, the right and left cervical, and right inguinal LNs became swollen for 2-3 months, then disappeared, respectively. The patient had advanced senile dementia, and aspiration pneumonias occurred repeatedly. Five years 10 months later, he died of severe aspiration pneumonia with disseminated

intravascular coagulation syndrome. No anti-tumor agent, including prednisolone, had been administered. During the 31-month course from the initial diagnosis of DLBCL until death, there was an absence of palpable LN swelling for 20 of those months.

DISCUSSION

We present a case of DLBCL harbouring EBV and showing SR. Polyclonal or oligoclonal proliferation, but not monoclonal proliferation of EBV-positive large B-cells cannot be excluded, although the diagnosis of DLBCL was made.

The transient appearance of serum M-protein and increase of plasma cells in the BM may have been reactions to EBV infection. The thrombocytopenia probably occurred by the bone marrow suppression due to the viral infection. This infection may have been the cause of histological transformation in NHL in this case.

Cells from the first and second biopsied LNs were examined by polymerase chain reaction (PCR) to detect rearrangement of the same immunoglobulin gene. However, because the second biopsied specimen did not show rearrangement of the immunoglobulin genes, identification of cells from the two biopsied LNs could not be confirmed.

Gattiker *et al.*²⁰ reviewed 69 cases of diffuse type NHL retrospectively, and reported that 2 cases (2.9%) showed SR. However, clinicians generally start anti-neoplastic treatment immediately after establishing a pathological diagnosis of malignant lymphoma (ML). Since almost all patients with NHL were treated with irradiation and/or chemotherapies, the actual ratio of SR in NHL remains unclear. Table 1 shows 15 reported cases of SR in aggressive NHL except for the gastric type in patients without any anti-neoplastic treatments till relapse. Several gastric ML cases showing SR have been reported²¹⁻²³. However, those cases were not included in table 1 because observations of those tumors require endoscopic examinations, and resection of gastric tumors is usual-

ly performed as the first therapy. Six of 15 cases (40%) have not shown relapse up to the respective last observation. Eight of 15 cases (53%) involved extra-nodal disease. Extra-nodal onset of lymphoma may be an important factor in SR. The tendency toward regression of tumors detected by clinicians occurs within 2 weeks after biopsy. If the remaining LNs after biopsy show a tendency to decrease in size without any anti-tumor therapies, the patients may show SR. In such cases, it may be a benefit for patients that "watchfull waiting" is included in the list of ML therapies.

The leading hypothesis regarding SR in relation to NHL involves modulation of the host immune system to viral or bacterial infection and/or traumatic effects including biopsy^{7,11,13,23}. Indeed, many cases in table 1 indicated that the trigger for reduction in the size of LNs was apparently biopsy alone, except in 2 cases developing measles shortly after diagnostic biopsy⁶ and our case. Schneider *et al.* reported regression of EBV-associated LPDs in 2 AIDS patients after therapy with an inhibitor of viral DNA polymerases²⁴. Our patient might have had unstable immunocompetence due to his advanced age of about 90. It is probable that fluctuating increase and decrease of the patient's immunocompetence affected the remissions and recurrences of DLBCL. In this case, the patient's anti-tumor immunity which was activated by the EBV probably excluded the EBV infected lymphoma

Table 1. Spontaneous regression in aggressive non-Hodgkin's lymphoma cases without anti-neoplastic treatments

Case	Age/ Sex	Location	Pathologic diagnoses	Starting of regression	Complete regression	Period of regression	Relapse	Last condition	EBV	Reference
1	12/ M	Submandibular	SNCML	1 day	ND	3 years	none	CR	Neg	3
2	67/ M	Bone marrow	DLCL	7 days	21 days	16 months	none	CR	Neg	4
3	30/ M	Chest wall	DLCL	8 days	12 days	9 days	present	Dead (AIDS)	ND	5
4	8/ M	Orbita	Burkitt L	10 days	24 days	4 months	none	CR	ND	6
5	58/ F	S-LNs	Imm blast L	11 days	22 days	2 years	none	CR	Neg	7
6	63/ F	Intracranial	DLCL	12 days	66 days	25 days	present	CR	ND	8
7	68/ F	Thyroid gland	DLCL	ND	14 days	4.5 months	present	CR	ND	9
8	84/ F	S-LNs	DLCL	ND	14 days	1.5 months	present	Dead	ND	10
9	78/ M	Gingiva	DLBCL	ND	21 days	3 years	none	CR	ND	11
10	77/ M	Soft palate	LCL	1 month	several weeks	12 months	present	CR	ND	12
11	54/ F	Waldeyer's ring	DLCL	1 month	8 months	4 years	none	CR	ND	13
12	54/ F	S-LNs	DLBCL	1 month	7 months	3 months	present	Dead (ML)	Neg	14
13	48/ M	Mediastinum	Anaplast T	ND	3 months	10 days	none	Dead (AIDS)	ND	15
14	82/ F	Para-aortic LN	DLCL	ND	4 months	6 months	none	Dead	ND	16
15	91/ M	S-LNs	DLBCL	55 days	60 days	16 months	present	Dead	Pos	Present case

S-LNs : Superficial lymph nodes, Para-aortic LN : Abdominal para-aortic lymph node, SNCML : small noncleaved cell malignant lymphoma, DLCL : diffuse large cell lymphoma, Burkitt L : Burkitt's lymphoma, Imm blast L : high grade immunoblastic lymphoma, DLBCL : diffuse large B-cell lymphoma, LCL : large cell lymphoma, Anaplast T : anaplastic : T cell lymphoma, CR : complete remission, AIDS : acquired immunodeficiency syndrome, ML : malignant lymphoma, EBV : Epstein-Barr virus, ND : not described, Neg : negative, Pos : positive

cells, as in the recovery period of infectious mononucleosis. Haralambieva *et al.* and Schrager *et al.* indicated that EBV may be a causative factor for good prognosis of sporadic Burkitt lymphoma with granulomatous reaction^{18,19}.

Recently, EBV-associated LPD in elderly people has been reported¹⁷. Aging is another important factor in the oncogenesis of EBV-associated lymphoma.

The existence of these SR cases indicates the possibility of curing aggressive NHL by immunotherapy in the future.

REFERENCES

- 1 Horning SJ, Rosenberg SA : The natural history of initially untreated low-grade non-Hodgkin's lymphomas. *N Eng J Med* 311 : 1471-1475, 1984
- 2 Krikorian JG, Portlock CS, Cooney DP, Rosenberg SA : Spontaneous regression of non-Hodgkin's lymphoma : A report of nine cases. *Cancer* 46 : 2093-2099, 1980
- 3 Poppema S, Postma L, Brinker M, de Jong B : Spontaneous regression of a small non-cleaved cell malignant lymphoma (non-Burkitt's lymphoblastic lymphoma). *Cancer* 62 : 791-794, 1988
- 4 Grigg AP, Gray GR, Shepherd JD : Spontaneous remission of multilobated non-Hodgkin lymphoma. *Am J Hematol* 40 : 222-225, 1992
- 5 Karnad AB, Jaffar A, Lands RH : Spontaneous regression of acquired immune deficiency syndrome-related, high-grade, extranodal non-Hodgkin's lymphoma. *Cancer* 69 : 1856-1857, 1992
- 6 Bluming AZ, Ziegler JL : Regression of Burkitt's lymphoma in association with measles infection. *Lancet* 2 : 105-106, 1971
- 7 Kumamoto M, Nakamine H, Hara T, Yokoya Y, Kawai J, Ito H, Nishioka S, Takenaka T, Wickert RS, Mitchell DW : Spontaneous complete regression of high grade non-Hodgkin's lymphoma. *Cancer* 74 : 3023-3028, 1994
- 8 Sugita Y, Shigemori M, Yuge T, Iryo O, Kuramoto S, Nakamura Y, Morimatsu M : Spontaneous regression of primary malignant intracranial lymphoma. *Surg Neurol* 30 : 148-152, 1988
- 9 Uohashi A, Imoto S, Matsui T, Murayama T, Okimura Y, Chihara K, Ohbayashi C, Itoh H : Spontaneous regression of diffuse large-cell lymphoma associated with Hashimoto's thyroiditis. *Am J Hematol* 53 : 201-211, 1996
- 10 Kashiyama T, Tojima H, Mizoo A, Imahashi M, Yasuda J, Fujita A, Watanabe A, Suzuki A, Kimura H : Diffuse large cell lymphoma with spontaneous regression in the lung and lymph nodes. Case report. *Jpn J Thoracic Dis* 30 : 1175-1179, 1992
- 11 Koga M, Kusukawa J, Hayabuchi N : Spontaneous regression of extranodal malignant lymphoma occurred in the gingiva. *Oral Oncol* 39 : 323-324, 2003
- 12 Savarrio L, Gibson J, Dunlop DJ, O'Rourke N, Fitzsimons EJ : Spontaneous regression of an anaplastic large cell lymphoma in the oral cavity : first reported case and review of the literature. *Oral Oncol* 35 : 609-613, 1999
- 13 Grem JL, Hafez GR, Brandenburg JH, Carbone PP : Spontaneous remission in diffuse large cell lymphoma. *Cancer* 57 : 2042-2044, 1986
- 14 Tamura J, Jinbo T, Take H, Matsushima T, Sawamura M, Murukami H, Kubota K, Naruse T, Tsuchiya J : Spontaneous regression in B cell, diffuse large cell type non-Hodgkin's lymphoma. *Acta Haematol* 90 : 46-47, 1993
- 15 Diekman MJM, Bresser P, Noorduyn LA, Reiss P : Spontaneous regression of Ki-1 positive T-cell non-Hodgkin's lymphoma. *Br J Haematol* 82 : 477-478, 1992
- 16 Ono O, Itabashi K, Sakai I, Nakano I, Fujino M, Kimura K, Sakai Y, Ohsaki Y, Kojima H : A case of spontaneous regression of malignant lymphoma, complicated with miliary tuberculosis, liver dysfunction and pancytopenia. *Jpn J Thoracic Dis* 28 : 1092-1097, 1990
- 17 Oyama T, Ichimura K, Suzuki R, Suzumiya J, Ohshima K, Yatabe Y, Yokoi T, Kojima M, Kamiya Y, Taji H, Kagami Y, Ogura M, Saito H, Morishima Y, Nakamura S : Senile EBV⁺ B-cell lymphoproliferative disorders : A clinicopathologic study of 22 patients. *Am J Surg Pathol* 27 : 16-26, 2003
- 18 Haralambieva E, Rosati S, van Noesel C, Boers E, van Marwijk Kooy M, Schuurin E, Kluin P : Florid granulomatous reaction in Epstein-Barr virus-positive nonendemic Burkitt lymphomas : report of four cases. *Am J Surg Pathol* 28 : 379-383, 2004
- 19 Schrager JA, Pittaluga S, Raffeld M, Jaffe ES : Granulomatous reaction in Burkitt lymphoma : correlation with EBV positive and clinical outcome. *Am J Surg Pathol* 29 : 1115-1116, 2005
- 20 Gattiker HH, Wiltshaw E, Galton DAG : Spontaneous regression in non-Hodgkin's lymphoma. *Cancer* 45 : 2627-2632, 1980
- 21 Ogawa D, Uemura N, Sasaki N, Mukai T, Yamaguchi S, Okamoto S, Yamamoto S, Mashiba H, Taniyama K : Case report. Spontaneous regression of malignant lymphoma of the stomach. *J Med* 29 : 381-393, 1998
- 22 Shigematsu A, Iida M, Lien G-S, Imamura T, Okada M, Fuchigami T, Fujishima M, Itoh H, Iwashita A : Spontaneous regression of primary malignant lymphoma of the stomach in two nontreated Japanese. *J Clin Gastroenterol* 11 : 511-517, 1989
- 23 Strauchen JA, Moran C, Goldsmith M, Greenberg M : Spontaneous regression of gastric lymphoma. *Cancer* 60 : 1872-1875, 1987
- 24 Schneider U, Ruhnke M, Delecluse H-J, Stein H, Huhn D : Regression of Epstein-Barr virus-associated lymphoproliferative disorders in patients with acquired immunodeficiency syndrome during therapy with foscarnet. *Ann Hematol* 79 : 214-216, 2000