

Case Study

A Case of Intravascular Lymphoma Complicated with Fournier's Syndrome Due to Multidrug-Resistant *Pseudomonas aeruginosa*

Hiroyasu Kaya and Takashi Yoshida

Fournier's syndrome is the fulminant necrotizing fasciitis of the external genitalia. The occurrence of Fournier's syndrome in patients with hematologic malignancies has been reported. Here we report a case of an intravascular lymphoma complicated with Fournier's syndrome due to multidrug-resistant *Pseudomonas aeruginosa* (MDRP). A 71-year-old Japanese man received intensive chemotherapy for recurring intravascular lymphoma. Blood culture revealed MDRP, and physical examination led to the diagnosis of Fournier's syndrome. Aggressive treatment that comprised granulocyte transfusion, granulocyte stimulating factor, endotoxin filtration, appropriate antibiotic coverage, and aggressive surgical therapy was administered, and this led to the successful recovery from sepsis and Fournier's syndrome. [*J Clin Exp Hematopathol* 51(2) : 115-118, 2011]

Keywords: Fournier's syndrome, multidrug-resistant *Pseudomonas aeruginosa*, granulocyte transfusion

INTRODUCTION

Fournier's syndrome is the fulminant necrotizing fasciitis of the external genitalia.^{1,2} The occurrence of Fournier's syndrome in patients with hematologic malignancies has been reported. It has a mortality rate of 30-50%, and underlying cellular immunodeficiency, irrespective of the etiology, predisposes a person to Fournier's syndrome.³ Here we report the case of a patient with non-Hodgkin's lymphoma (intravascular lymphoma) who developed Fournier's syndrome due to infection with multidrug-resistant *Pseudomonas aeruginosa* (MDRP). He was treated with granulocyte transfusion (the donor was his wife with a major ABO mismatch), granulocyte-colony stimulating factor (G-CSF), continuous hemodialytic filtration, endotoxin filtration, and surgical treatment, and was eventually cured of sepsis and the syndrome.

CASE REPORT

A 71-year-old Japanese man had been diagnosed with non-Hodgkin's lymphoma of bone marrow origin at another

hospital. He had attained complete remission after 6 cycles of the CHOP regimen (cyclophosphamide, doxorubicin, vincristine, and prednisone) in 2007. He was referred to our hospital for fever of unknown origin in August 2008. He had no hepatosplenomegaly, no skin eruption, and no lymphadenopathy. His laboratory data showed mild anemia, thrombocytopenia, a lactate dehydrogenase level of 487 IU/L, and a serum soluble interleukin-2 receptor level of 4,000 U/mL. We repeated bone marrow aspiration at our hospital; several atypical cells were detected, but because the cells were very few, we did not diagnose non-Hodgkin's lymphoma. Because random skin biopsy is known to be useful, skin biopsy was performed at 3 different sites. Of the 3 biopsies, 2 were positive for intravascular lymphoma. After adequate informed consent, he was therefore administered intensive chemotherapy with our salvage regimen "R-TVBBM" (rituximab, THP-adriamycin, etoposide, behenyl arabinocide, bleomycin, and m-prednisolone), which was done as clinical study in our hospital. After this chemotherapy, fever disappeared, but only to recur after 2 weeks along with chemotherapy-induced pancytopenia. On day 13 after chemotherapy, blood culture revealed infection with MDRP, for which he was administered several antibiotics; finally, piperacillin, ciprofloxacin, and astreonam were administered on the basis of the results of the drug-sensitive test. However, septic shock and renal failure developed, and he was treated with granulocyte transfusion, where the donor was his wife with a major ABO mismatch; continuous hemodialytic filtration; G-CSF; and endotoxin filtration (Fig. 1). His blood type was O (+) whereas his wife's blood type was AB (+) against American

Received : January 25, 2011

Revised : April 14, 2011

Accepted : April 23, 2011

Department of Internal Medicine, Toyama Prefectural Central Hospital, Toyama City, Japan

Address correspondence and reprint request to Hiroyasu Kaya, M.D., Department of Internal Medicine, Toyama Prefectural Central Hospital, Nishi-nagae 2-2-78, Toyama City 930-8550, Japan

E-mail : hiro-kaya@kit.hi-ho.ne.jp

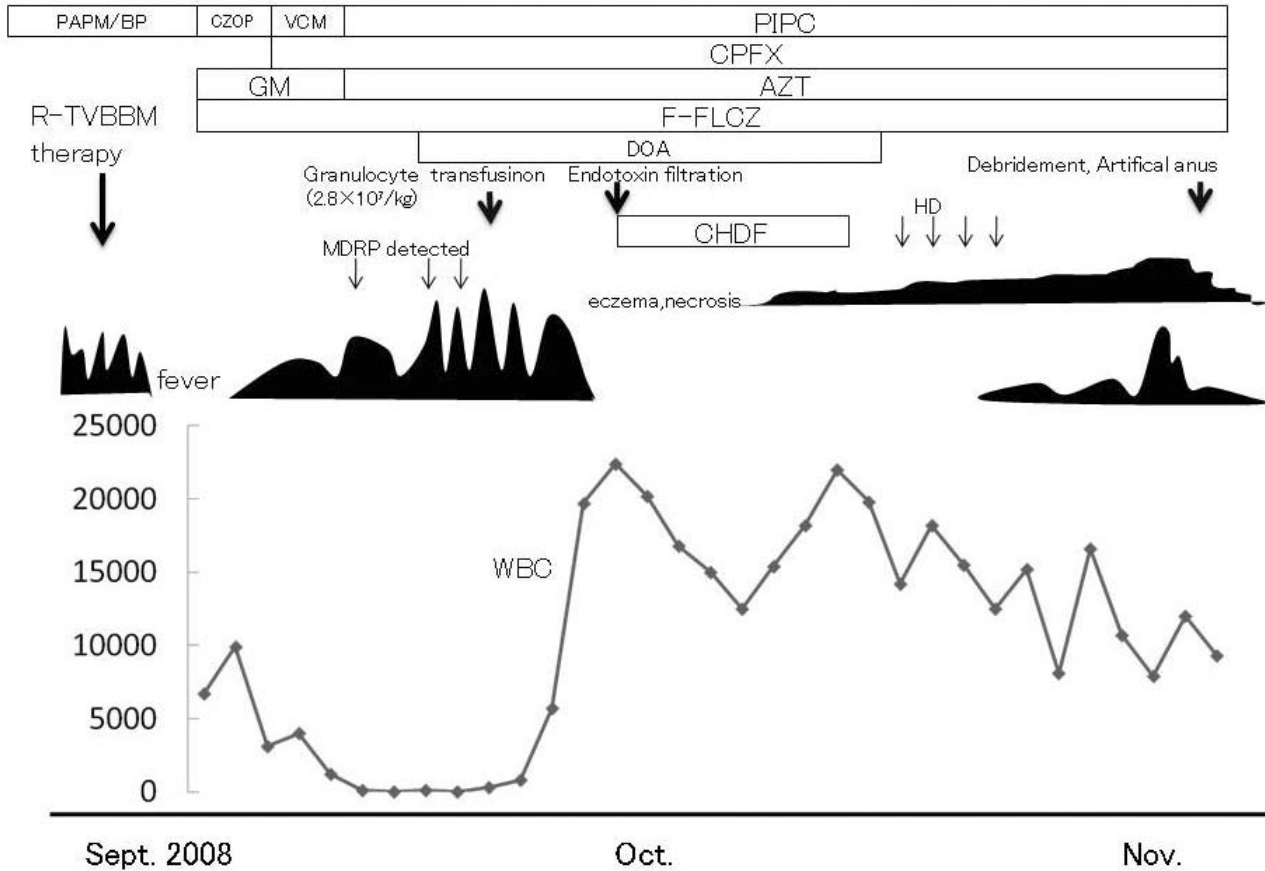


Fig. 1. Clinical course

Association Blood Banks (AABB) Circular of Information for the Use of Human Blood and Blood Components;⁴ she was selected as the donor, because no other options were available and his titers of anti-A and anti-B antibodies was maintained very low (1:8 and 1:4, respectively) by previous rituximab therapy. By this reason, we injected G-CSF 300 μg to his wife at the day before harvest and harvested granulocytes by COBE spectra. His white blood cell increased from 300 to 800/ μL after the granulocyte infusion of 1.86×10^9 cells. After two days, he was afebrile. Two weeks later, his blood cell count recovered completely and he recovered from septic shock and renal failure. However, eczema and skin necrosis was noted on his testis and that eventually extended into his genital region with the diagnosis of Fournier's syndrome (Fig. 2). MDRP was detected in the discharge from the skin necrotic lesion and his stool. Treatment with antibiotics, debridement of necrotic tissue, and creation of an artificial anus were effective in clearing his skin lesion after about 3 years.

DISCUSSION

Fournier's syndrome is believed to develop because of the

worsening of the impetigo around the anus into an abscess involving the entire genitalia,⁵ but septic emboli can also, in some cases, lead to Fournier's syndrome.⁶ Shultz *et al.* have suggested that Fournier's syndrome may be related to a form of localized vasculitis with histological evidence of hemorrhagic necrosis.⁷ The most common organisms isolated in the bacterial culture are *Escherichia coli*, *Bacteroides*, *Streptococcus*, and *Staphylococcus*. *Pseudomonas* is also detected in about 20% of patients with Fournier's syndrome.^{5,8} Martinelli³ reported that cultures were positive for *Pseudomonas aeruginosa* in all but one of six patients with bone marrow transplantation. *Pseudomonas aeruginosa* is one of the most important infections encountered in patients in the agranulocytotic state of hematologic malignancy. In particular, the recently isolated MDRP was found to be resistant to all commercially available antibiotics in Japan. MDRP infection can be critical in patients at the leukocytopenic state of hematologic malignancy. Because MDRP contains metallo- β -lactamase, this bacteria is resistant to carbapenem, fluoroquinolone, and amino glycoside; only systemic therapy with colistin is reportedly effective. Colistin was first introduced in 1952 and was used until the early 1980s to treat infections

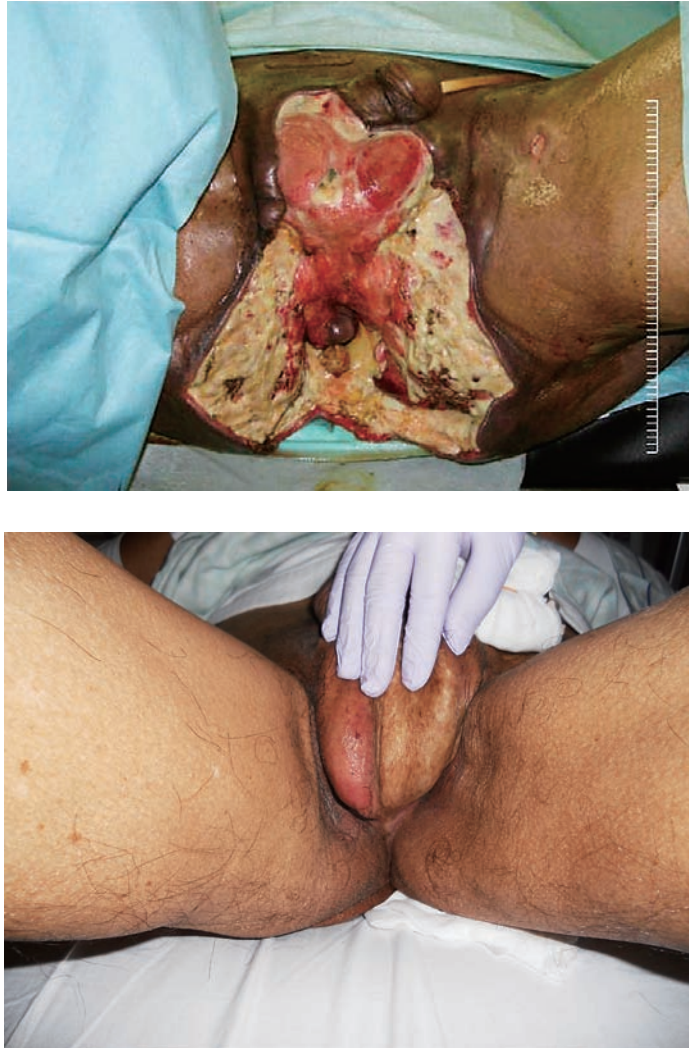

Fig. 2. Photograph of Fournier's gangrene. (2a) The patient's genital lesion before debridement and creation of an artificial anus. (2b) The patient's present genital lesion after surgical treatment, including skin transplantation

caused by gram-negative rods. At the beginning of the 21st century, the increasing prevalence of MDR gram-negative organisms has rekindled the interest in colistin.⁹ Our patient recovered from MDRP-induced sepsis because of treatment with other antibiotics, GCSF, endotoxin filtration, and granulocyte transfusion from an ABO major-mismatch donor. Colistin was not used in our patient because it is not available in Japan; however, we believe that if colistin were used, he would have recovered from sepsis even sooner.

Granulocyte transfusion is a logical approach to infection in severely neutropenic patients, and several early trials have suggested the benefits of this approach adjunct to antibiotic therapy.¹⁰ In both donors and recipients, adverse events are very infrequent and alloimmunization does not develop rap-

idly. With this approach, neutropenia can be corrected and the body's capacity to deliver neutrophils to the site of inflammation can be restored. In AABB Circular of Information for the Use of Human Blood and Blood Components, the indications are described as the following. Apheresis Granulocytes are typically used in the treatment of patients with documented infections (especially gram-negative bacteria and fungi) unresponsive to antimicrobial therapy in the setting of neutropenia [absolute granulocyte count $< 0.5 \times 10^9/L$ ($500/\mu L$)] with expected eventual marrow recovery, or neonatal sepsis. A trial of broad-spectrum antimicrobial agents should be used before granulocyte transfusion therapy is initiated. The red cells in Apheresis Granulocytes must be ABO compatible.⁴ Our patient was treated with granulocyte trans-

fusion from an ABO major-mismatch donor (his wife) ; however, his anti-A and anti-B antibody titers were maintained very low because of the use of rituximab, and therefore, adverse events did not occur. Moreover, debridement, creation of an artificial anus, and skin transplantation eventually led to the complete recovery from Fournier's syndrome.

Despite the advent of newer antibiotics, Fournier's gangrene remains a surgical emergency because the ability of the infection to worsen in a few hours. In 1999, it was reported that exploration and debridement should be undertaken under general anesthesia as soon as the patient is ready for the procedure.^{5,8} We believe that in our case, aggressive surgical therapy was effective.

In summary, we believe that the combination of granulocyte transfusion ; GCSF ; endotoxin filtration ; appropriate antibiotic, particularly colistin, and aggressive surgical therapy is very important in treating sepsis by MDRP and Fournier's syndrome.

REFERENCES

- 1 Fournier JA: Gangrene foundroyante de la verge. *Sem Med* 3:344-346, 1883
- 2 Mantadakis E, Pontikoglou C, Papadaki HA, Aggelidakis G, Samonis G: Fatal Fournier's gangrene in a young adult with acute lymphoblastic leukemia. *Pediatr Blood Cancer* 49:862-864, 2007
- 3 Martinelli G, Alessandrino EP, Bernasconi P, Cardera D, Colombo A, *et al.*: Fournier's gangrene: a clinical presentation of necrotizing fasciitis after bone marrow transplantation. *Bone Marrow Transplant* 22:1023-1026, 1998
- 4 American Association Blood Banks: AABB Circular of Information for the Use of Human Blood and Blood Components. www.aabb.org/resources/bct/Documents/coi0809r.pdf 237 KB-2/23/2011
- 5 Cakmak A, Genc V, Akyol C, Kayaoglu HA, Hazinedaroglu SM: Fournier's gangrene: is it scrotal gangrene ? *Adv Ther* 25:1065-1074, 2008
- 6 Norton K, Johnson L, Perry T, Perry K, Sehon J, *et al.*: Management of Fournier's gangrene: an eleven year retrospective analysis of early recognition, diagnosis, and treatment. *Am Surg* 68:709-713, 2002
- 7 Schultz ESS, Diepgen TL, Von Den Driesch P, Hornstein OP: Systemic corticosteroids are important in the treatment of Fournier's gangrene: a case report. *Br J Dermatol* 133:633-635, 1995
- 8 Vick R, Carson CC, III: Fournier's disease. *Urol Clin North Am* 26:841-849, 1999
- 9 Kallel H, Bahloul M, Hergafi L, Akrouf M, Ketata W, *et al.*: Colistin as a salvage therapy for nosocomial infections caused by multidrug-resistant bacteria in the ICU. *Int J Antimicrob Ag* 28:366-369, 2006
- 10 Price TH, Bowden RA, Boeckh M, Bux J, Nelson K, *et al.*: Phase I/II trial of neutrophil transfusions from donors stimulated with G-CSF and dexamethasone for treatment of patients with infections in hematopoietic stem cell transplantation. *Blood* 95:3302-3309, 2000