

Case Study

# Portal Vein Thrombosis during Eltrombopag Treatment for Immune Thrombocytopenic Purpura in a Patient with Liver Cirrhosis due to Hepatitis C Viral Infection

Noriaki Kawano,<sup>1)\*</sup> Satoru Hasuike,<sup>2)\*</sup> Hisayoshi Iwakiri,<sup>2)</sup> Kenichi Nakamura,<sup>2)</sup> Yoshinori Ozono,<sup>2)</sup> Hisanori Kusumoto,<sup>2)</sup> Kenji Nagata,<sup>2)</sup> Ikuko Kikuchi,<sup>1)</sup> Shuro Yoshida,<sup>1)</sup> Takuro Kuriyama,<sup>1)</sup> Kiyoshi Yamashita,<sup>1)</sup> Takahiro Muranaka,<sup>3)</sup> Takumi Kawaguchi,<sup>4)</sup> Michio Sata,<sup>4)</sup> Takashi Okamura,<sup>5)</sup> Akira Ueda,<sup>1)</sup> and Kazuya Shimoda<sup>2)</sup>

Portal vein thrombosis is a rare, aggressive and life-threatening complication of liver cirrhosis (LC). Eltrombopag is effective for the treatment of chronic hepatitis with thrombocytopenia, and portal vein thrombosis at this time has rarely been reported. We describe the case of a 78-year-old woman who suffered from LC due to hepatitis C viral infection. The patient developed immune thrombocytopenic purpura (ITP) that was diagnosed on the basis of nasal bleeding, progressive severe thrombocytopenia, elevation of platelet-associated IgG (PAIgG), no response to the transfusion of platelets and no abnormal findings on bone marrow biopsy. Although we first administered prednisolone (0.5 mg/kg/day), there was no recovery of platelet function and the nasal bleeding persisted. Subsequently, we administered eltrombopag for refractory ITP at a dose of 12.5 mg/day, and the thrombocytopenia gradually improved. Fifty-four days after the start of eltrombopag therapy, she developed portal vein thrombosis. Eltrombopag was stopped immediately, and antithrombin III was administered for prophylaxis against further portal vein thrombosis. Despite these treatments, there were subsequent deep vein and pulmonary artery thromboses. We then administered heparin for recanalization of the thrombi. One month after the initiation of heparin, there was recanalization as well as improvements of the portal vein, deep vein and pulmonary artery thromboses. There was no further thrombosis progression after switching from heparin to warfarin therapy. Our case suggests that eltrombopag may increase the risk of portal vein thrombosis; therefore, this drug must be used carefully in the treatment of ITP in patients with LC due to hepatitis C viral infection. [*J Clin Exp Hematop* 53(2) : 151-155, 2013]

**Keywords:** portal vein thrombosis, eltrombopag, immune thrombocytopenic purpura, liver cirrhosis

## INTRODUCTION

Liver cirrhosis (LC) is the final stage of any chronic liver

Received : July 23, 2012

Revised : February 14, 2013

Accepted : March 21, 2013

<sup>1)</sup>Department of Internal Medicine, Miyazaki Prefectural Hospital, Miyazaki, Japan

<sup>2)</sup>Department of Internal Medicine, Gastroenterology and Hematology, Faculty of Medicine, Miyazaki University, Miyazaki, Japan

<sup>3)</sup>Department of Radiology, Miyazaki Prefectural Hospital, Miyazaki, Japan

<sup>4)</sup>Division of Gastroenterology, Department of Medicine, and Department of Digestive Disease Information & Research, Kurume University School of Medicine, Kurume, Japan

<sup>5)</sup>Department of Internal Medicine, Hematology, Kurume University, Fukuoka, Japan  
Corresponding author : Dr. Noriaki Kawano, Department of Internal Medicine, Miyazaki Prefectural Hospital, 5-30 Kitatakamatsu, Miyazaki, Miyazaki 880-0017, Japan

E-mail : kawanoriaki@yahoo.co.jp

\* These authors contributed equally to this work.

disease and is accompanied by thrombocytopenia due to portal hypertension, hypersplenism, decreased thrombopoietin production, and virus-induced bone marrow suppression.<sup>1,2</sup> Among the etiologies of chronic liver disease, hepatitis C virus (HCV) infection was reported to be associated with an elevated risk of immune thrombocytopenia purpura (ITP) (hazard ratio, 1.8; 95% confidence interval, 1.4-2.3), and HCV infection may play a role in the etiology of ITP.<sup>3</sup>

Eltrombopag is a newly developed, non-peptide agent that stimulates thrombopoietic receptors and is effective in patients with ITP.<sup>4-8</sup> Recently, the indications for eltrombopag have been expanded to include the treatment of ITP in patients with chronic hepatitis and thrombocytopenia.<sup>2</sup> Recent studies have shown that there is a risk of thrombosis, such as deep vein and pulmonary thromboses, with the administration of eltrombopag for ITP.<sup>4-8</sup> Furthermore, portal vein thrombosis is a rare but life-threatening complication that can develop

when eltrombopag is used to treat chronic liver disease with thrombocytopenia.<sup>2,9,10</sup>

Here, we report a case of portal vein thrombosis that developed during the treatment of ITP with eltrombopag in a patient who had LC due to HCV infection.

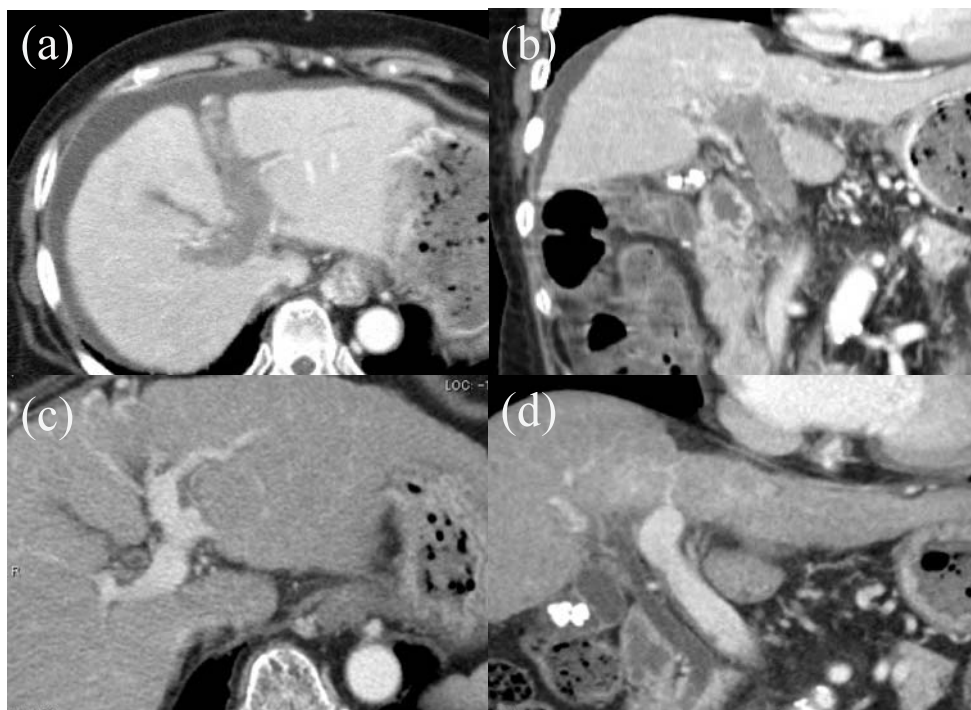
### CASE REPORT

A 78-year-old woman presenting with nasal bleeding was referred to a regional hospital on May 31, 2011. She was medicated and followed up for LC due to HCV infection in April 2006. On admission, the patient was normotensive (102/64 mmHg) with a heart rate of 66 beats/min. Physical examination revealed petechiae on the extremities and 2 finger breadths of splenomegaly.

Laboratory findings showed a hemoglobin concentration of 11.8 g/dL, a platelet count of  $1 \times 10^9/L$  and a white blood cell count of  $2.24 \times 10^9/L$  with 55% neutrophils, 36% lymphocytes and 9% monocytes. Total serum bilirubin and lactate dehydrogenase levels increased to 2.90 mg/dL and 329 IU/L, respectively. IgG, IgA and IgM were 2, 257 mg/dL, 138 mg/dL and 707 mg/dL, respectively. Serological markers

related to ITP such as antinuclear antibody and platelet-associated IgG were elevated to 80 and 3,740 IU/mL, respectively. Serological markers related to primary biliary cirrhosis, such as antimitochondrial antibodies, were within the normal range. A bone marrow biopsy was obtained and histology revealed hypocellular bone marrow with no other abnormalities. Considering all of these findings together, we made a diagnosis of LC with ITP due to HCV infection.

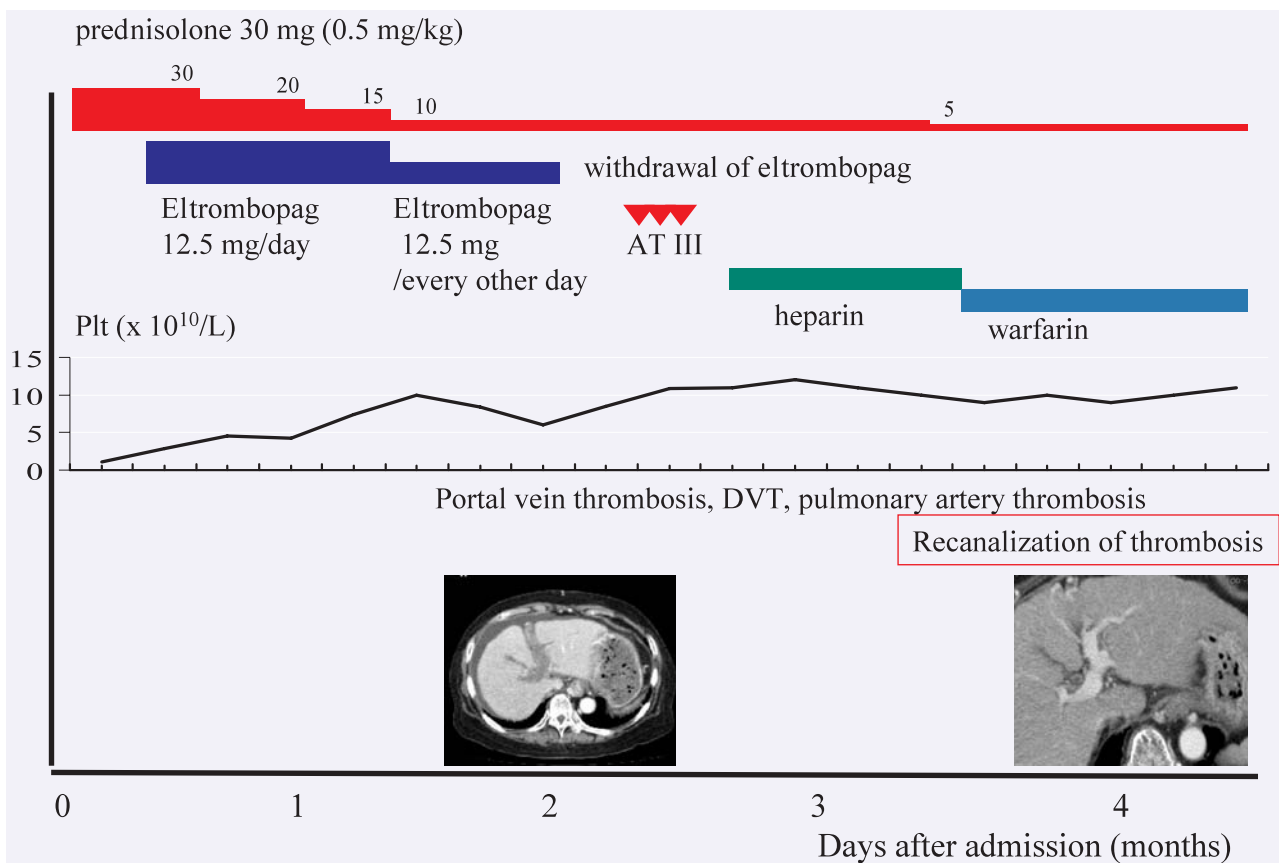
Although we first administered prednisolone at a dose of 0.5 mg/kg due to the patient's age, hyperglycemia, and the negative findings of *Helicobacter pylori* infection, there was no recovery of platelet function and the nasal bleeding persisted. In this setting, according to the treatment guidelines of ITP,<sup>11</sup> high-dose d-globulin (IVIG) was recommended. However, we did not administer IVIG because of the patient's age and chronic heart failure. Therefore, we subsequently administered eltrombopag for refractory ITP at a dose of 12.5 mg/day, and the thrombocytopenia gradually improved. According to the therapeutic guidelines for the administration of eltrombopag, the dose should be adjusted based on the platelet count. In our case, the 12.5 mg dose was administered every other day when the platelet count was  $> 100 \times 10^9/L$ .



**Fig. 1.** Abdominal computed tomography (CT) findings that confirmed the diagnosis and the treatment efficacy of portal vein thrombosis during treatment with eltrombopag. (**1a**) Abdominal CT findings that revealed portal vein thrombosis on enhanced abdominal CT. (**1b**) Abdominal CT findings on the coronary image that revealed portal vein thrombosis on enhanced abdominal CT. (**1c**) Abdominal CT findings that revealed the recanalization of portal vein thrombosis on enhanced abdominal CT. (**1d**) Abdominal CT findings on the coronary image that revealed the recanalization of portal vein thrombosis on enhanced abdominal CT.

After recovery of the platelet count, the value of platelet-associated IgG was not measured. Forty-four days after this treatment regimen, the patient presented with stage 2 hepatic encephalopathy that included lethargy, moderate confusion and an elevated blood NH<sub>3</sub> level. The hepatic encephalopathy resolved with the administration of branched-chain amino acids and lactulose. Fifty-four days later, fibrin degradation products (FDP) gradually increased, and abdominal ultrasound indicated the presence of portal vein thrombosis. Abdominal enhanced computed tomography (CT) was performed and confirmed portal vein thrombosis (Fig. 1a & 1b). The CT also showed swelling of the ascending colon. Antigen and protein S activity were within normal ranges. Antigen and protein C activity were slightly decreased to 40% and 44%, respectively. We immediately terminated the eltrombopag therapy (Fig. 2) and then administered antithrombin AT (ATIII) for prophylaxis against further development

of portal vein thrombosis. After the discontinuation of eltrombopag, we tapered the prednisolone and then continued to administer it at a dose of 5 mg/day for the maintenance of ITP because the effect of eltrombopag only continues for short periods. Despite ATIII treatment and the withdrawal of eltrombopag, deep vein and pulmonary artery thromboses subsequently occurred. Therefore, we administered heparin to promote recanalization of the thrombi. After the initiation of heparin therapy, the serological findings of liver dysfunction and coagulation markers of FDP gradually improved. One month after the initiation of heparin, there were recanalization and resolution of the portal vein, deep vein and pulmonary artery thromboses (Fig. 1c & 1d). Consequently, heparin was discontinued and warfarin was initiated with no further progression of the thrombosis.



**Fig. 2.** Clinical course of the present patient. The patient suffered from liver cirrhosis due to hepatitis C viral infection. She developed immune thrombocytopenic purpura (ITP). Although we first administered prednisolone (0.5 mg/kg/day), there was no recovery of platelets. Subsequently, we administered eltrombopag for refractory ITP at a dose of 12.5 mg/day, and the thrombocytopenia gradually improved. Fifty-four days after the start of eltrombopag therapy, she developed portal vein thrombosis. Eltrombopag was stopped immediately, and antithrombin III was administered. Despite these treatments, there was subsequent deep vein and pulmonary artery thromboses. We then administered heparin. One month after the initiation of heparin, there was recanalization as well as improvement of the portal vein, deep vein and pulmonary artery thromboses. Plt, platelet ; ATIII, antithrombin, DVT, deep vein thrombosis

## DISCUSSION

Portal vein thrombosis is one of the lethal complications of chronic liver disease.<sup>1,2,9,10</sup> In contrast to previous reports of thrombotic complications such as deep vein thrombosis and pulmonary artery thromboembolism during the administration of eltrombopag for ITP,<sup>4,8</sup> portal vein thrombosis during eltrombopag therapy for ITP in patients with chronic liver disease is a rare but potentially lethal complication.<sup>2,9,10</sup> Since portal vein thrombosis is rare during the administration of thrombopoietic receptor stimulators (< 5 cases reported), the clinical features, treatment and prognosis of this condition are not clear.<sup>1,9,10</sup> McHutchison *et al.* reported that eltrombopag may be effective for thrombocytopenia in patients with LC associated with HCV infection in a phase III trial.<sup>2</sup> Thrombotic complications were not observed in the 74 patients in that trial.<sup>2</sup> Komori *et al.* reported that one patient with LC developed portal vein thrombosis during treatment with eltrombopag.<sup>9</sup> Dultz *et al.* reported portal vein thrombosis as a complication of romiplostim treatment in a cirrhotic patient with HCV-associated ITP.<sup>10</sup> In both of these cases, thrombopoietic receptor stimulation with eltrombopag or romiplostim was terminated immediately.<sup>9,10</sup> Subsequently, anticoagulant treatment with heparin or warfarin was initiated, and the portal vein thrombosis improved in both cases.<sup>9,10</sup>

In our case, portal vein, deep vein and pulmonary artery thromboses developed during the administration of eltrombopag for ITP in LC. When portal vein thrombosis was diagnosed in our case, eltrombopag therapy was stopped immediately. Since deep vein and pulmonary thromboses developed subsequently, we initiated ATIII, heparin and warfarin therapy based on liver function, and this led to resolution of the thrombosis. Our case strongly suggested that the treatment of ITP with eltrombopag in a patient with LC may result in lethal systemic thrombosis and require immediate anticoagulant treatment. Consequently, eltrombopag may increase the risk of portal vein thrombosis; therefore, this drug must be used carefully in the treatment of ITP in patients with LC due to HCV infection.

The onset of portal vein thrombosis in our case may have been related to the administration of eltrombopag and the prothrombotic characteristics of ITP. The initial dose of eltrombopag was only 12.5 mg/day. According to the therapeutic guidelines for the administration of eltrombopag,<sup>4,8</sup> the dose should be adjusted based on the platelet count. Eltrombopag should be tapered when the platelet count is  $> 200 \times 10^9/L$  and terminated when the count is  $> 400 \times 10^9/L$ .<sup>4,8</sup> In our case, eltrombopag was tapered when the platelet count was  $> 100 \times 10^9/L$ . Although we started with a low dose of eltrombopag and adjusted the dose as the platelet count increased, this did not prevent the development of portal vein thrombosis. In the RAISE trial, Cheng *et al.* reported that thromboembolic events occurred in only about 2% [3/

135; The RAISE study reported that three (2%) patients receiving eltrombopag ( $n = 135$ ) had thromboembolic events compared with no patients on placebo ( $n = 62$ ). Thus, it was 3/135 patients rather than 3/197 patients who had thromboembolic events.] of ITP patients treated with eltrombopag when the platelet count was in the target range ( $50-400 \times 10^9/L$ ).<sup>7</sup> Therefore, in patients at increased risk of thrombosis, the dose of eltrombopag may need to be adjusted even when the platelet count is below the lower limit of normal ( $150 \times 10^9/L$ ). Although the mechanism of thrombosis due to eltrombopag is not clear, increases in both platelet count and platelet activity may play a role.

An important feature of our case was that screening of FDP and the abdominal ultrasound were useful for detecting portal vein thrombosis before the patient presented with the clinical features of this condition. When the abdominal ultrasound suggested portal vein thrombosis, abdominal CT was used to make a definitive diagnosis.

Although we withdrew eltrombopag immediately when portal vein thrombosis was diagnosed, this did not prevent the progression of thrombosis. According to the guidelines for the treatment of portal vein thrombosis in non-cirrhotic patients,<sup>11-15</sup> the standard treatment is anticoagulation with agents such as ATIII and heparin for 3-6 months.<sup>11-15</sup> However, Garcia-Fuster *et al.* reported that 83% (14/17) of cirrhotic patients who were treated with anticoagulants for thromboembolism had progression of hemorrhage and many required blood transfusion.<sup>12</sup> Therefore, the administration of anticoagulants such as ATIII and heparin to LC patients with ITP is controversial because of the increased risk of bleeding.<sup>12</sup> In our case, the administration of ATIII and heparin led to recanalization and resolution of the portal vein, deep vein and pulmonary artery thromboses. A case-by-case approach is essential for the treatment of portal vein thrombosis in LC patients with ITP.

In conclusion, our case indicated that the treatment of ITP with eltrombopag in a patient with LC due to HCV infection may result in portal vein thrombosis. A randomized study with multiple patients and longer follow-up time will be necessary to establish the indication for eltrombopag in cirrhotic patients with ITP.

## ACKNOWLEDGEMENTS

We thank Ms. Kiyoyama, Ms. Sakurai and Ms. Kugimiya for carefully examining the bone marrow specimen.

## REFERENCES

- 1 Garcia-Tsao G, Lim JK; Members of Veterans Affairs Hepatitis C Resource Center Program: Management and treatment of patients with cirrhosis and portal hypertension: recommendations from the Department of Veterans Affairs Hepatitis C Resource

- Center Program and the National Hepatitis C Program. *Am J Gastroenterol* 104:1802-1829, 2009
- 2 McHutchison JG, Dusheiko G, Shiffman ML, Rodriguez-Torres M, Sigal S, *et al.*: Eltrombopag for thrombocytopenia in patients with cirrhosis associated with hepatitis C. *N Engl J Med* 357:2227-2236, 2007
  - 3 Chiao EY, Engels EA, Kramer JR, Pietz K, Henderson L, *et al.*: Risk of immune thrombocytopenic purpura and autoimmune hemolytic anemia among 120 908 US veterans with hepatitis C virus infection. *Arch Intern Med* 169:357-363, 2009
  - 4 Provan D, Stasi R, Newland AC, Blanchette VS, Bolton-Maggs P, *et al.*: International consensus report on the investigation and management of primary immune thrombocytopenia. *Blood* 115:168-186, 2010
  - 5 Cines DB, Bussel JB, Liebman HA, Luning Prak ET : The ITP syndrome : pathogenic and clinical diversity. *Blood* 113:6511-6521, 2009
  - 6 Stasi R: Immune thrombocytopenic purpura : the treatment paradigm. *Eur J Haematol Suppl.* (Suppl 71):13-19, 2009
  - 7 Cheng G, Saleh MN, Marcher C, Vasey S, Mayer B, *et al.*: Eltrombopag for management of chronic immune thrombocytopenia (RAISE) : a 6-month, randomised, phase 3 study. *Lancet* 377:393-402, 2011
  - 8 Kuter DJ: Thrombopoietin and thrombopoietin mimetics in the treatment of thrombocytopenia. *Annu Rev Med* 60:193-206, 2009
  - 9 Komori A, Seike M, Fujiyama S, Watanabe H, Mukouzaka A, *et al.*: Phase II trial of eltrombopag for thrombocytopenia in patients with cirrhosis associated with hepatitis C. *The Japanese Society of Hepatology. Kanzo* 52 (suppl 1) : 147A, 2011 (*in Japanese*)
  - 10 Dultz G, Kronenberger B, Azizi A, Mihm U, Vogl TJ, *et al.*: Portal vein thrombosis as complication of romiplostim treatment in a cirrhotic patient with hepatitis C-associated immune thrombocytopenic purpura. *J Hepatol* 55:229-232, 2011
  - 11 Neunert C, Lim W, Crowther M, Cohen A, Solberg L Jr, *et al.*: The American Society of Hematology 2011 evidence-based practice guideline for immune thrombocytopenia. *Blood* 117:4190-4207, 2011
  - 12 Ponziani FR, Zocco MA, Tortora A, Gasbarrini A : Is there a role for anticoagulants in portal vein thrombosis management in cirrhotic patients ? *Expert Opin Pharmacother* 11:1479-1487, 2010
  - 13 García-Fuster MJ, Abdilla N, Fabiá MJ, Fernández C, Oliver V, *et al.*: Venous thromboembolism and liver cirrhosis. *Rev Esp Enferm Dig* 100:259-262, 2008 (*in Spanish*)
  - 14 DeLeve LD, Valla DC, Garcia-Tsao G: American Association for the Study Liver Diseases. *Vascular disorders of the liver. Hepatology* 49:1729-1764, 2009
  - 15 Rajani R, Björnsson E, Bergquist A, Danielsson A, Gustavsson A, *et al.*: The epidemiology and clinical features of portal vein thrombosis : a multicentre study. *Aliment Pharmacol Ther* 32:1154-1162, 2010