

Case Study

Gradually-Deteriorating Liver Function due to Iron Overload Over Four Years after Allogeneic Stem Cell Transplantation

Hiroaki Tanaka,^{1,2)} Chika Kawajiri,³⁾ Shio Sakai,³⁾ Yusuke Takeda,³⁾ Takeharu Kawaguchi,¹⁾ Naoya Mimura,³⁾ Emiko Sakaida,³⁾ Chikako Ohwada,³⁾ Masahiro Takeuchi,³⁾ Shinichiro Hashimoto,¹⁾ Toshiyuki Takagi,¹⁾ and Chiaki Nakaseko³⁾

In allogeneic hematopoietic stem cell transplantation (allo-SCT) recipients with liver dysfunction, it is often difficult to determine the cause. Several cases of liver dysfunction may be interpreted as chronic graft versus host disease without a definitive diagnosis, resulting in continued immunosuppressive therapy for longer periods. Allo-SCT recipients commonly require frequent red blood cell transfusions during the course of treatment and transplantation, leading to significant iron overload, which could be one of causes of liver dysfunction. Here we report an allo-SCT recipient with chronic deteriorating liver dysfunction due to iron overload, despite maintaining transfusion independence for more than four years. Using magnetic resonance-based liver iron concentration (MR-LIC), iron overload-related liver dysfunction was diagnosed. It drastically improved with monthly phlebotomy and has not recurred following its termination. The observations from our case suggested that iron overload should be recognized as a cause of chronic liver dysfunction even in patients who remain transfusion-independent for several years and that MR-LIC analysis is a useful and reliable method for detecting iron overload and monitoring the effect of iron-reduction therapy. [*J Clin Exp Hematop* 55(2) : 109-112, 2015]

Keywords: iron overload, liver dysfunction, transfusion independence, magnetic resonance imaging, phlebotomy

INTRODUCTION

In allogeneic hematopoietic stem cell transplantation (allo-SCT) recipients with liver dysfunction, it is often difficult to determine whether the cause of liver dysfunction is hepatic graft-versus-host disease (GVHD), viral liver dysfunction, drug toxicity, non-alcoholic steatohepatitis, or iron overload.¹ Several cases of liver dysfunction may be often interpreted as chronic hepatic GVHD, resulting in continued immunosuppressive therapy for longer periods, despite liver dysfunction being the only symptom that could suggest chronic GVHD.

Allo-SCT recipients commonly require frequent red blood cell (RBC) transfusions during the course of treatment and transplantation, leading to significant post-transplantation iron

overload. Tissue accumulation of iron may eventually lead to progressive liver, heart, and endocrine gland dysfunction. Pre-transplant iron overload has been significantly associated with an increased incidence of transplant-related mortality and decreased overall survival rate.^{2,3} However, to date, delayed post-transplant iron overload and its complications have not been well characterized, except in patients with thalassemia.^{4,5}

Here we report the successful treatment by monthly phlebotomy of chronic deteriorating liver dysfunction in an allo-SCT recipient. Despite maintaining transfusion independence for more than four years, the patient was diagnosed with iron overload by serum ferritin (SF) levels and magnetic resonance-based liver iron concentration (MR-LIC) analyses.

CASE REPORT

A 58-year-old Japanese man developed chronic-phase chronic myeloid leukemia (CML) in September 2005. Treatment with imatinib was initiated; however, it resulted in severe pancytopenia. The patient received blood transfusions over six months; as a result of which, imatinib was eventually discontinued in the absence of a cytogenetic response. Bone marrow transplantation from an HLA-matched sibling donor

Received: June 9, 2015

Revised : June 30, 2015

Accepted: July 19, 2015

¹⁾Department of Hematology, Oami Municipal Hospital, Chiba, Japan

²⁾Department of Hematology, Asahi General Hospital, Chiba, Japan

³⁾Department of Hematology, Chiba University Hospital, Chiba, Japan

Corresponding author: Hiroaki Tanaka, M.D., Department of Hematology, Asahi General Hospital, I-1326, Asahi-city, Chiba, Japan

e-mail: htanaka@hospital.asahi.chiba.jp

was performed in September 2007, following conditioning with busulfan and fludarabine. A complete cytogenetic response was initially achieved; however, the disease relapsed with increased amounts of recipient cells, and the patient developed severe pancytopenia. In May 2008, the patient underwent allogeneic peripheral blood stem cell transplantation (PBSCT) from the same sibling donor, following conditioning with fludarabine and melphalan. For both transplantation procedures, Cyclosporin A (CsA) and short-term methotrexate were administered for GVHD prophylaxis. Engraftment was achieved on the 11th post-PBSCT day. However, 28 days post-PBSCT, the patient developed acute GVHD with skin involvement and diarrhea; hence, he was treated with 2 mg/kg of prednisolone. A complete molecular response was achieved 67 days post-PBSCT, and the patient remained independent of blood transfusions following engraftment. SF level on the 63rd post-PBSCT day was 2,520 ng/mL (reference range, 25-280 ng/mL). On the 105th post-PBSCT day, when the CsA dose was reduced to 20 mg, γ -glutamyl transpeptidase levels acutely increased to 560 IU/mL (normal, 10-47 IU/mL). Concurrently, serum alanine aminotransferase (ALT) and SF levels were also found to be elevated [177 IU/mL (reference range, 8-42 IU/mL) and 4,840 ng/mL, respectively]. Although there was no histological evidence, liver dysfunction was initially attributed to chronic hepatic GVHD due to the development of characteristic signs and symptoms of chronic GVHD, including sicca, gingival erosion, and bronchiolitis obliterans. The CsA dose was increased to 100 mg, leading to immediate improvement in liver dysfunction. On the 171st post-PBSCT day, previously elevated SF levels decreased to 2,710 ng/mL.

Over the four years following transplantation, liver function fluctuated and gradually deteriorated, despite of improve-

ment in the other symptoms of chronic GVHD (Fig. 1). Tapering of CsA dose was attempted, however, it could not be decreased to less than 50 mg. Laboratory evaluation in January 2013 revealed the following biochemical results: total bilirubin, 0.5 mg/dL; aspartate aminotransferase, 160 IU/mL (reference range, 13-33 IU/mL); ALT, 177 IU/mL; lactate dehydrogenase, 221 IU/mL (reference range, 119-229 IU/mL); alkaline phosphatase, 288 IU/mL (reference range, 115-359 IU/mL); γ -glutamyl transpeptidase, 35 IU/mL; white blood cell count, $7.7 \times 10^9/L$; RBC count, $4,690 \times 10^9/L$; hemoglobin, 15.1 g/dL; platelets, $244 \times 10^9/L$; serum iron (Fe), 219 $\mu\text{g/dL}$; unsaturated iron-binding capacity, 167 $\mu\text{g/dL}$; total iron-binding capacity, 386 $\mu\text{g/dL}$; and SF, 4,529 ng/mL. Serological tests for hepatitis B and C virus were negative. Abdominal ultrasonography revealed no abnormal lesions in the liver or biliary system, except for elevated hepatorenal contrast. The patient received 56 RBC transfusion units in total since the onset of CML and remained RBC transfusion-independent for more than four years thereafter.

MR-LIC was calculated according to a well-validated algorithm described by Gandon and colleagues.⁶ Magnetic resonance imaging of the liver with various gradient-recalled echo sequences was performed using a 1.5-T system (EXCELART Vantage XGV, Toshiba Medical Systems Corporation, Japan). The correlation between the liver-to-muscle signal intensity ratio and liver iron concentration was calculated. An algorithm to calculate MR-LIC was developed using data from the aforementioned study and is publicly available online (<http://www.radio.univ-rennes1.fr/index.html.en.html>).

Iron overload-related liver injury was diagnosed with an MR-LIC of 200 $\mu\text{mol/g}$. Phlebotomy, drawing 400 mL of whole blood, was performed every four weeks after the initial

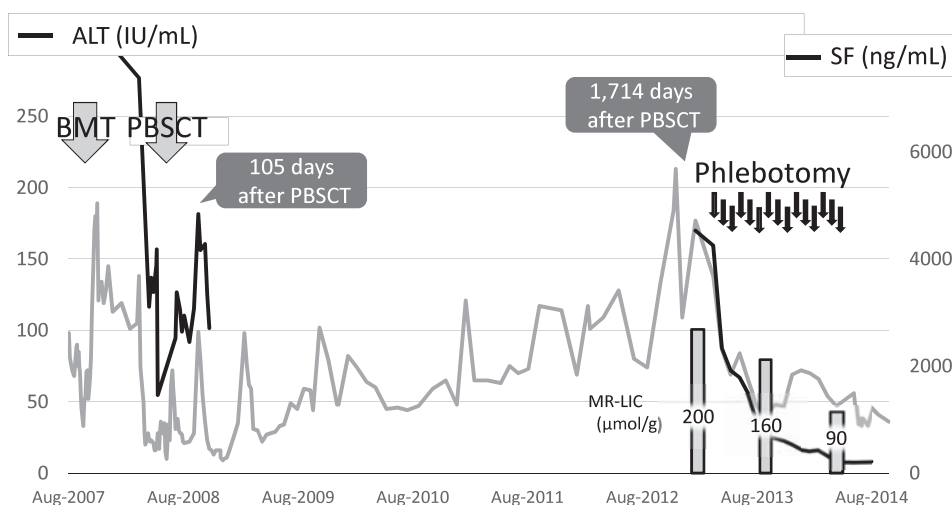


Fig. 1. Clinical course. ALT, alanine aminotransferase; BMT, bone marrow transplantation; PBSCT, peripheral blood stem cell transplantation; SF, serum ferritin; MR-LIC, magnetic resonance-based liver iron concentration

diagnosis. Laboratory findings showed significant improvement after eight phlebotomies (SF, 620 ng/mL; aspartate aminotransferase, 53 IU/mL; ALT, 40 IU/mL), and MR-LIC decreased to 160 μ mol/g. The CsA dose was gradually decreased and finally discontinued after 15 phlebotomies when the SF and MR-LIC levels had further decreased to 327 ng/mL and 90 μ mol/g, respectively; at this point, phlebotomy was also discontinued. No recurrence of liver dysfunction was observed after discontinuation of CsA and phlebotomy.

DISCUSSION

Iron overload should be recognized as a cause of chronic liver dysfunction even in allo-SCT recipients who remain transfusion-independent for several years. Our case suggested that deposition of iron in the liver along with frequent blood transfusions gradually worsens the liver over time. A proportion of allo-SCT recipients with iron-overload liver injury are initially misdiagnosed with hepatic GVHD. Kamble *et al.* reported that these patients can be correctly diagnosed by liver biopsy and successfully treated with phlebotomy.⁷ In our case, the first liver dysfunction on the 105th post-PBSCT day was confirmed to be chronic hepatic GVHD because it was effectively treated with CsA, and the other characteristic symptoms of chronic GVHD were complicated. Therefore, the liver injury was assumed to be due to prolonged chronic hepatic GVHD for over four years. However, in fact, the primary cause of his liver dysfunction might be iron overload for four years following allo-SCT, because all the other symptoms suggestive of chronic GVHD had already improved, and the liver function drastically improved by only phlebotomy. His liver dysfunction was not severe, and the patient remained asymptomatic; however, it is essential to note that CsA administration, which was needlessly continued on a long-term basis, could have been terminated. CsA is expensive and has been known to have adverse effects, such as immune depression, glucose intolerance, and dyslipidemia.

This case demonstrates that monthly phlebotomy is an effective treatment method for iron overload in allo-SCT recipients. In allo-SCT recipients who have no anemia with iron-overload liver injury, phlebotomy could be performed instead of treatment with iron-chelating agents, which are expensive and carry a risk of leading to acute kidney dysfunction.

MR-LIC measurement by Gandon's algorithm may represent a useful and reliable method for evaluating the whole-body iron burden and monitoring the effect of iron-reduction therapy. This algorithm represents a simple method for LIC estimation, requiring the 1.5-T system magnetic resonance imaging, widely available in Japan, without the need for specialized equipment. Measurement of SF levels is commonly used to assess the whole-body iron burden; however, this

measurement may be influenced by inflammatory processes, such as recurrent infection, chronic GVHD, and liver disease.⁸ At the time of the first liver dysfunction on the 105th post-PBSCT day, the SF level sharply fluctuated due to chronic GVHD; over four years after the allo-PBSCT, the SF level increased due to the liver dysfunction itself. Unfortunately, there was no histological evidence of liver dysfunction and time-series behavior of SF in those four years. Therefore, MR-LIC was performed for definite diagnosis instead of liver biopsy. In Japan, iron overload is still estimated by SF levels and the number of RBC transfusions administered, whereas MR-LIC analysis is rarely performed for identification of iron overload. Allo-SCT recipients, frequently suffering from GVHD and recurrent infections, would particularly benefit from iron overload estimation by MR-LIC measurement in addition to SF analysis.

In the present case, liver dysfunction almost completely resolved, and SF levels decreased to approximately 500 ng/mL after the completion of eight phlebotomies; however, the MR-LIC did not significantly decrease. Busca *et al.* reported an allo-SCT recipient exhibiting renormalization of SF and liver dysfunction after completing a phlebotomy regimen with no significant reduction in LIC.⁹ Kamble *et al.* demonstrated that SF levels gradually increase after successful iron-reduction therapy for liver injury and that phlebotomy should be maintained.⁷ As organ damage does not typically occur with an LIC < 120 μ mol/g,^{10,11} we continued phlebotomy for 15 sessions, which resulted in a decrease of MR-LIC (90 μ mol/g) and potential prevention of liver dysfunction recurrence.

In summary, our case highlights the susceptibility of RBC transfusion-independent patients to liver dysfunction due to hepatic iron overload even several years after allo-SCT. We demonstrate the efficacy of monthly phlebotomy for treating iron overload in transfusion-independent allo-SCT recipients. Finally, we propose MR-LIC analysis using Gandon's algorithm as a useful and reliable method for detecting iron overload and monitoring the effect of iron-reduction therapy.

ACKNOWLEDGEMENTS

The authors would like to thank Kazuhiro Yoshino, Department of Radiology, Oami Municipal Hospital, for establishing MR-LIC in our hospital.

DISCLOSURE OF CONFLICTS OF INTEREST: The authors declare no conflicts of interest.

REFERENCES

- 1 Tomás JF, Pinilla I, García-Buey ML, García A, Figuera A, *et al.*: Long-term liver dysfunction after allogeneic bone marrow transplantation: clinical features and course in 61 patients. *Bone*

- Marrow Transplant 26:649-655, 2000
- 2 Kataoka K, Nannya Y, Hangaishi A, Imai Y, Chiba S, *et al.*: Influence of pretransplantation serum ferritin on nonrelapse mortality after myeloablative and nonmyeloablative allogeneic hematopoietic stem cell transplantation. *Biol Blood Marrow Transplant* 15:195-204, 2009
 - 3 Altès A, Remacha AF, Sureda A, Martino R, Briones J, *et al.*: Iron overload might increase transplant-related mortality in haematopoietic stem cell transplantation. *Bone Marrow Transplant* 29:987-989, 2002
 - 4 Sivgin S, Eser B: The management of iron overload in allogeneic hematopoietic stem cell transplant (alloHSCT) recipients: where do we stand? *Ann Hematol* 92:577-586, 2013
 - 5 Majhail NS, Lazarus HM, Burns LJ: Iron overload in hematopoietic cell transplantation. *Bone Marrow Transplant* 41:997-1003, 2008
 - 6 Gandon Y, Olivieri D, Guyader D, Aubé C, Oberti F, *et al.*: Non-invasive assessment of hepatic iron stores by MRI. *Lancet* 363:357-362, 2004
 - 7 Kamble RT, Selby GB, Mims M, Kharfan-Dabaja MA, Ozer H, *et al.*: Iron overload manifesting as apparent exacerbation of hepatic graft-versus-host disease after allogeneic hematopoietic stem cell transplantation. *Biol Blood Marrow Transplant* 12:506-510, 2006
 - 8 Worwood M: Serum ferritin. *Clin Sci (Lond)* 70:215-220, 1986
 - 9 Busca A1, Falda M, Manzini P, D'Antico S, Valfrè A, *et al.*: Iron overload in patients receiving allogeneic hematopoietic stem cell transplantation: quantification of iron burden by a superconducting quantum interference device (SQUID) and therapeutic effectiveness of phlebotomy. *Biol Blood Marrow Transplant* 16:115-122, 2010
 - 10 Olivieri NF, Brittenham GM: Iron-chelating therapy and the treatment of thalassemia. *Blood* 89:739-761, 1997
 - 11 Olivieri NF: The β -thalassemias. *N Engl J Med* 341:99-109, 1999