

Original Article

# Dose-Modified Ifosfamide, Epirubicin, and Etoposide is a Safe and Effective Salvage Therapy with High Peripheral Blood Stem Cell Mobilization Capacity for Poorly Mobilized Hodgkin's Lymphoma and Non-Hodgkin's Lymphoma Patients

Akiko Fukunaga, Mizuki Hyuga, Makoto Iwasaki, Yoshiki Nakae,  
Wataru Kishimoto, Yoshitomo Maesako, and Nobuyoshi Arima

A dose modified ifosfamide, epirubicin, and etoposide (IVE) regimen was prospectively assessed for its efficacy in mobilizing peripheral blood stem cells for autologous transplantation. Two patients with Hodgkin's lymphoma and two with non-Hodgkin's lymphoma who were undergoing stem cell therapy were studied. All patients had a history of multiple treatments with insufficient stem cell mobilization. The dose modified IVE regimen consisted of ifosfamide 3 g/m<sup>2</sup> intravenously (IV) administered on days 1-2 in combination with epirubicin 50 mg/m<sup>2</sup> IV on day 1 and etoposide 200 mg/m<sup>2</sup> (100 mg/m<sup>2</sup> in two patients with complete remission) IV on days 1-3. The ifosfamide dosage was reduced to two-thirds of the original protocol. A substantial high yield of CD34<sup>+</sup> cells was achieved when patients were treated with a dose-modified IVE regimen, compared with that during the previous regimen (two with the ifosfamide, carboplatin, and etoposide [ICE] regimen, one with high-dose cyclophosphamide and one with the original IVE regimen). Two patients who had refractory and residual disease received a 200 mg/m<sup>2</sup> dose of etoposide, which resulted in tumor reduction (one patient with complete remission and one with further reduction in tumor size). After the IVE regimen, all four patients had a sufficient yield of CD34<sup>+</sup> cells in total, which was available for stem cell transplantation. Hematological and non-hematological toxicities were comparable in all regimens. This single-center prospective study demonstrated that the dose-modified IVE regimen can be used as a safe treatment with high mobilizing efficacy in heavily pretreated lymphoma patients. [*J Clin Exp Hematop* 56(1):50-54, 2016]

**Keywords:** lymphoma, stem cell mobilization, ifosfamide, epirubicin, etoposide

## INTRODUCTION

Recently, non-Hodgkin's lymphoma (NHL) patient outcomes have been markedly improved by combining molecular targeting therapy (rituximab) with standard chemotherapy regimens, such as cyclophosphamide, doxorubicin, vincristine, and prednisone, in both aggressive and indolent CD20<sup>+</sup> lymphomas.<sup>1,2</sup> Although many patients respond well, with long-term disease-free survival, there are still some

populations who have refractory or recurrent disease. Rituximab maintenance therapy during the first remission improves progression-free survival in follicular lymphoma, but does not prolong event-free, progression-free, or overall survival of patients with aggressive B-cell non-Hodgkin's lymphoma.<sup>3-5</sup>

HL is a rare lymphoma that accounts for approximately 10% of all lymphomas. It is a potentially curative neoplasm that is treated by anthracycline-based chemotherapy combined with radiation therapy. Recent efforts have concentrated on decreasing the treatment intensity for patients with early stage HL and on improving the outcome of advanced stage HL with more intensive regimens. An antibody drug conjugate targeting CD30, brentuximab vedotin, has proven to be highly effective for refractory or relapsed HL.<sup>6,7</sup> Currently, the focus is on incorporating this novel therapeutic agent into standard front-line chemotherapy regimens, with

Received: February 19, 2016

Revised: April 15, 2016

Accepted: May 20, 2016

Hematology Department, Kitano Hospital, the Tazuke Kofukai Medical Research Institute, Osaka, Japan

**Corresponding author:** Dr. Akiko Fukunaga, Hematology Department, Kitano Hospital, The Tazuke Kofukai Medical Research Institute, 2-4-20 Ohgimachi, Kitaku, Osaka, 530-8480, Japan  
E-mail: a-fukunaga@kitano-hp.or.jp

the aim of improving cure rates for the advanced disease.

Treatment with high-dose chemotherapy followed by autologous hematopoietic stem cell transplantation is known to improve both progression-free and overall survival among patients with NHL and HL in second remission.<sup>8-10</sup> Peripheral blood stem cells (PBSC) are a preferred source for rescue after high-dose chemotherapy, owing to their more rapid hematological recovery compared with the bone marrow, with reductions in antibiotic and blood product use, as well as reduced length of inpatient stay.<sup>11,12</sup> Currently, there are several combination chemotherapy regimens for PBSC collection, particularly the ifosfamide, carboplatin, and etoposide (ICE) regimen, which has a high efficacy and great progenitor cell mobilization capacity.<sup>13</sup> However, the majority of patients with refractory or relapsed disease have a previous treatment history with antitumor agents such as alkylating agents or purine analogs, which may impair the mobilization of CD34<sup>+</sup> cells. The combination of ifosfamide with etoposide and epirubicin (IVE) has been shown to have promising anti-tumor efficacy for relapsed or resistant NHL and HL.<sup>14-16</sup> Moreover, Fox *et al.* have demonstrated that the IVE regimen is a more effective stem cell mobilization regimen than ICE in the context of salvage therapy for HL and NHL patients, allowing more patients to achieve CD34<sup>+</sup> cell mobilization and proceed to high-dose therapy and autologous stem cell transplantation.<sup>17</sup> However, the IVE regimen includes a relatively high dose of ifosfamide, which increases the risk of ifosfamide encephalopathy. Bishton *et al.* have reported that among 143 patients with relapsed or refractory HL and NHL treated with the IVE regimen, encephalopathy occurred in 10 patients, including three severe cases that required further treatment.<sup>16</sup> Most cases of ifosfamide encephalopathy resolve within few days, but some patients develop irreversible central nervous system disorders. Here we will describe four lymphoma patients with relapsed or refractory disease who underwent recruitment of CD34<sup>+</sup> cells via high-dose chemotherapy (two patients: ICE regimen one

patient: high-dose cyclophosphamide one patient: original IVE regimen), which resulted in poor mobilization. They were treated with a dose-modified IVE regimen consisting of a reduced ifosfamide dosage, which resulted in successful PBSC mobilization and reasonable hematological and non-hematological toxicity without attenuating the drug efficacy.

## PATIENTS AND METHODS

### Patients

Two HL patients and two NHL patients were enrolled in the study. All four patients had refractory or relapsed disease after high-dose chemotherapy followed by peripheral blood stem cell collection, which resulted in insufficient stem cell mobilization. All patients provided written informed consent prior to the initiation of chemotherapy. Patient characteristics and previous treatment details are summarized in Table 1.

### Treatment protocol and stem cell mobilization

Patients received a dose-modified IVE regimen. The modified IVE regimen was modified from the original IVE regimen<sup>16</sup> and administered as follows: Ifosfamide 3 g/m<sup>2</sup>/day continuous intravenous (IV) infusion over 24 hr on days 1-2; VP-16 100 mg/m<sup>2</sup>/day IV infusion over 2 hr on days 1-3 for the two HL patients in remission and 200 mg/m<sup>2</sup>/day IV on days 1-3 for the NHL patients in non-remission; epirubicin 50 mg/m<sup>2</sup>/day over 30 min on day 1. MESNA was administered at a dose of 1.8 g/m<sup>2</sup> IV prior to the first dose of ifosfamide, 3 g/m<sup>2</sup>/day continuous IV infusion over 24 hr on days 1 and 2, and 5.4 g/m<sup>2</sup> IV over 12 hr from the completion of the ifosfamide infusion. Prophylactic phenytoin (300 mg/day) was administered from day -1 to day 8. Granulocyte colony-stimulating factor (G-CSF) was administered at a dose of 5 µg/kg daily beginning on day 5 until the comple-

**Table 1.** Patient characteristics

Patient No.	Age	Diagnosis	Clinical stage	Previous chemotherapy	Previous mobilization regimen	Disease status
1	49	cHL NS	II	ABVD, ESHAP, ICE, GVD	HD-AC	CR2
2	51	cHL MC	IV	ABVD, ICE	ICE	CR2
3	51	DLBCL	IV	R-CHOP, R-ICE	R-ICE	PD
4	64	EATL	IV	CHOP, IVE-MTX	IVE	PR

cHL, classical Hodgkin lymphoma; NS, nodular sclerosis; MC, mixed cellularity; DLBCL, diffuse large B-cell lymphoma; EATL, enteropathy-associated T-cell lymphoma; ABVD, adriamycin bleomycin vinblastine & dacarbazine; ESHAP, etoposide cytarabine carboplatin & methylprednisolone; ICE, ifosfamide, carboplatin, & etoposide; GVD gemcitabine vinorelbine & dexamethasone; R-CHOP, rituximab, cyclophosphamide, doxorubicin, vincristine, and prednisolone; R-ICE, rituximab, ifosfamide, carboplatin, & etoposide; IVE, ifosfamide, epirubicin & etoposide; MTX, methotrexate; HD-AC, high dose cytarabine; CR, complete remission; PD, progression disease; PR, partial remission

tion of stem cell collection.

### Stem cell collection and flow cytometric analysis

Following G-CSF stimulation, peripheral leukocytes were counted, and leukapheresis was performed on the day when the white blood cell count exceeded  $5 \times 10^9$  cells/L. CD34<sup>+</sup> selection was performed using COBE Spectra (Caridian BCT, Lakewood, CO) for three cases and Spectra Optia (TERUMO BCT, Tokyo, Japan) for the fourth case. Harvested PBSC was analyzed for the CD34<sup>+</sup> cell population using CYTOMICS FC500 (Beckman Coulter, Tokyo, Japan).

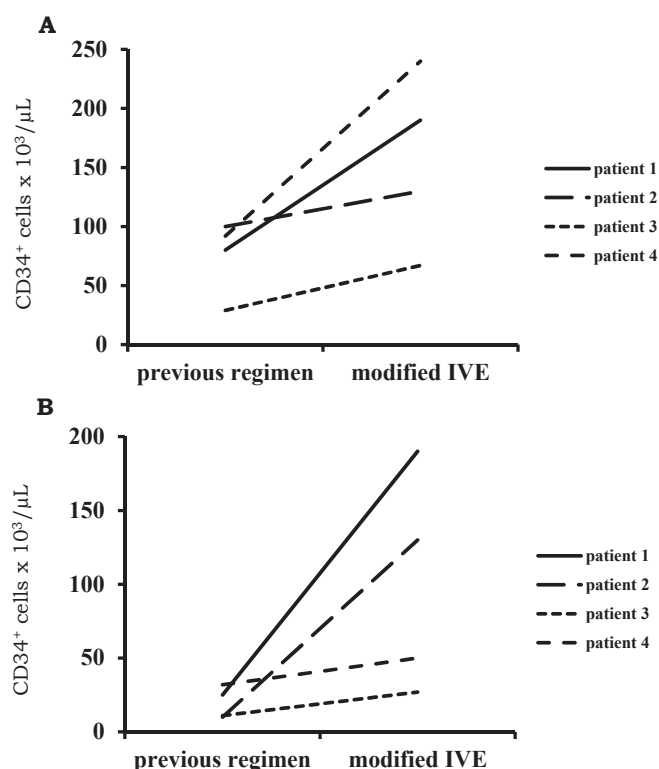
## RESULTS

All four patients achieved a substantial increase in mobilized CD34<sup>+</sup> cells compared with that seen using the previous regimen. In patient 1,  $1.3 \times 10^6$  cells/kg were mobilized,  $1.9 \times 10^6$  cells/kg in patient 2,  $0.67 \times 10^6$  cells/kg in patient 3, and  $2.4 \times 10^6$  cells/kg in patient 4, achieving a higher total CD34<sup>+</sup> cell recruitment in all patients (Fig. 1a). In particular, 13-, 7.6-, 2.5- and 1.6-fold higher amounts of CD34<sup>+</sup> cells were recruited in the four patients on the first day of collection (Fig. 1b). Patients 1 and 2 only underwent a single

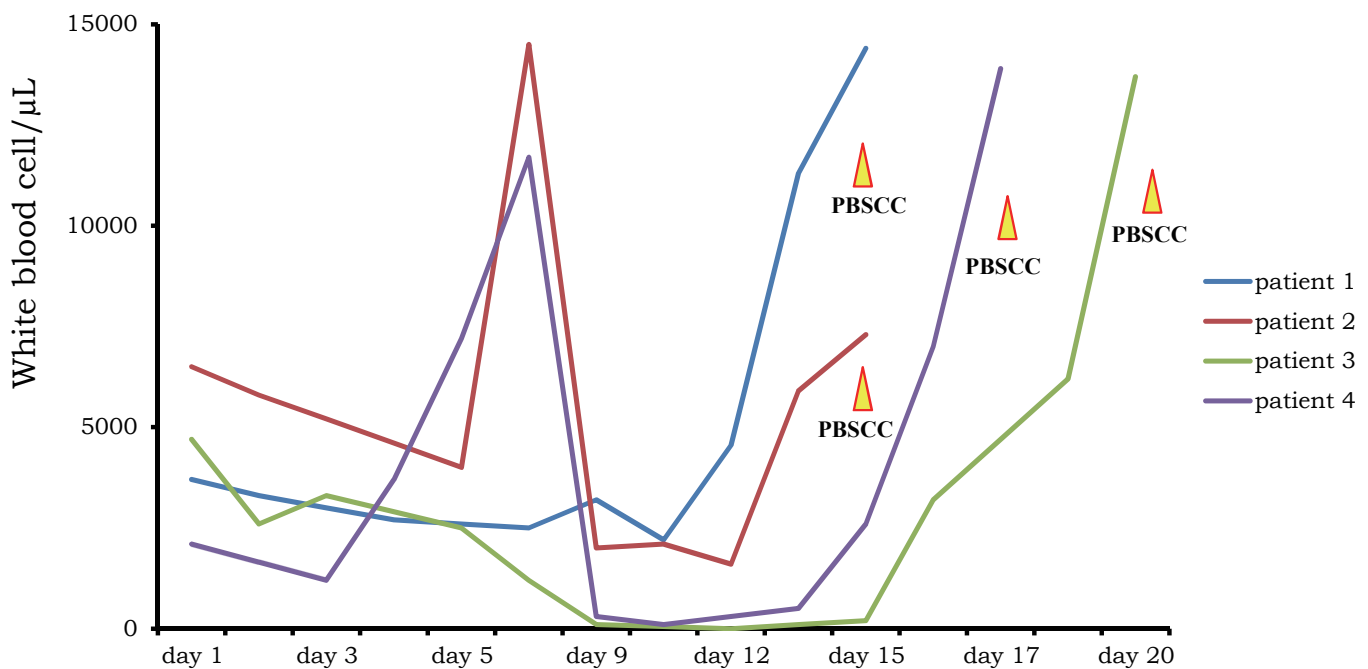
procedure because they achieved a high stem cell yield, which was sufficient for autologous stem cell transplantation, whereas for patients 3 and 4, CD34<sup>+</sup> cells were collected on an additional day. In patients 1 and 2, the cells were harvested on day 14 after the initiation of the IVE regimen, whereas patients 3 and 4 required 20 and 16 days, respectively, to achieve a sufficient white blood cell count (Fig. 2). All four patients tolerated the IVE regimen well. Grade 4 neutropenia occurred in two patients who received a 200 mg/m<sup>2</sup> dose of VP-16, grade 4 thrombocytopenia and grade 3 anemia, which required multiple blood transfusions, occurred in three patients. Non-hematological toxicity was at an acceptable level in all patients; grade 1 febrile neutropenia occurred in one patient. Patients 1 and 2 had tumor remission upon initiation of the modified IVE regimen, and this was maintained after the treatment. Patient 3 and 4 had residual disease before the initiation of the modified IVE regimen, which resulted in complete remission after the modified IVE regimen treatment. All four patients proceeded to autologous stem cell transplantation that achieved neutrophil engraftment on day 11 in patient 2 and on day 12 in patients 1, 3 and 4.

## DISCUSSION

This is a single center study analyzing the efficacy and the stem cell mobilization capacity of the modified IVE regimen. The conventional IVE regimen was described by Zinzani *et al.* as a salvage therapy for patients with relapsed HL and NHL.<sup>18</sup> Recently McQuaker *et al.* have used the IVE regimen as both a salvage and stem cell mobilization therapy. Furthermore, they showed that IVE, in combination with G-CSF, is an effective regimen for stem cell mobilization even in those heavily pretreated patients who have had poor or failed mobilization previously with the cyclophosphamide and G-CSF combination.<sup>19,20</sup> Subsequently, the IVE regimen was shown to have a high efficacy as a salvage therapy for HL and B-cell NHL.<sup>15,21</sup> Furthermore, as a salvage therapy for HL and NHL, Fox *et al.* demonstrated that the IVE regimen has a more effective stem cell mobilization capacity than the ICE regimen, thus allowing more patients to achieve the target CD34<sup>+</sup> cell numbers.<sup>17</sup> IVE seems to have a high efficacy for both the anti-lymphoma effects and the stem cell mobilization capacity; however, the neurotoxicity of ifosfamide is a matter of great concern. In the conventional IVE regimen, patients are administered a total of 9 g/m<sup>2</sup> ifosfamide. With this amount of ifosfamide, 7% of patients developed ifosfamide encephalopathy, including three cases with a severe disease status that required methylene blue administration.<sup>16</sup> In this study, patients with hypoalbuminemia, abnormal liver function, renal impairment or previous encephalopathy episodes were regarded as a high-risk group. Some patients in the high-risk group received dose reductions



**Fig. 1.** Number of collected CD34<sup>+</sup> cells. (*1a*) Total collected CD34<sup>+</sup> cells in previous and modified IVE (ifosfamide, epirubicin & etoposide) regimens. (*1b*) Number of collected CD34<sup>+</sup> cells on the first day of collection.



**Fig. 2.** White blood cell count throughout the course of modified IVE (ifosfamide, epirubicin & etoposide) treatment. Timing of the peripheral blood stem cell collection is indicated (PBSCC).

of ifosfamide, which resulted in only two out of 13 cases developing encephalopathy, whereas all high-risk patients without dose adjustment developed encephalopathy. Used as a salvage therapy, patients are likely to be heavily pretreated and have a tendency toward having low residual organ functions. In a previous study by Tajino *et al.*, ifosfamide encephalopathy occurred in 31.2% of Japanese patients with bone and soft tissue sarcoma when ifosfamide at a dose of 9 g/m<sup>2</sup> or more was administered. In that report, previous cisplatin treatment was associated with an increased risk of encephalopathy onset.<sup>22</sup> Therefore, we conducted our study using an ifosfamide dose of 6 g/m<sup>2</sup> instead of 9 g/m<sup>2</sup>. Furthermore, the patient with remission disease received a half dose of etoposide. Thus, in three patients, more than twice as many CD34<sup>+</sup> cells were mobilized in a single harvest without reducing the anti-tumor effects, compared with that during a previous mobilization regimen. In our study, all four patients were heavily pretreated, but with a poor mobilization yield; however, all patients substantially achieved improvement in CD34<sup>+</sup> mobilization with our regimen, and with minimal non-hematologic toxicity. Moreover, patient 4 was treated with the original IVE regimen for the first mobilization, but developed severe sepsis that resulted in systemic condition deterioration, which may have affected the poor CD34 cell mobilization. This patient was re-mobilized successfully by treatment with a dose-modified IVE regimen without degrading the patient's performance status. None of our patients developed ifosfamide encephalopathy or

infections during the treatment course. Though this study involved too small a sample size to discuss the role of the modified IVE regimen, it may become a cornerstone for the treatment choice of both stem cell mobilization and salvage therapy for malignant lymphoma.

## CONFLICT OF INTEREST

The authors declare that they have no conflict of interest.

## REFERENCES

- 1 Coiffier B, Thieblemont C, Van Den Neste E, Lepage G, Plantier I, *et al.*: Long-term outcome of patients in the LNH-98.5 trial, the first randomized study comparing rituximab-CHOP to standard CHOP chemotherapy in DLBCL patients: a study by the Group d'Etudes des Lymphomes de l'Adulte. *Blood* 116:2040-2045, 2010
- 2 Hiddemann W, Kneba M, Dreyling M, Schmitz N, Lengfelder E, *et al.*: Frontline therapy with rituximab added to the combination of cyclophosphamide, doxorubicin, vincristine, and prednisone (CHOP) significantly improves the outcome for patients with advanced-stage follicular lymphoma compared with therapy with CHOP alone: results of a prospective randomized study of the German Low-Grade Lymphoma Study Group. *Blood* 106:3725-3732, 2005
- 3 Salles G, Seymour JF, Offner F, López-Guillermo A, Belada D, *et al.*: Rituximab maintenance for 2 years in patients with high

- tumour burden follicular lymphoma responding to rituximab plus chemotherapy (PRIMA): a phase 3, randomized controlled trial. *Lancet* 377:42-51, 2011
- 4 Nastoupil LJ, Sinha R, Byrtek M, Zhou X, Taylor MD, *et al.*: The use and effectiveness of rituximab maintenance in patients with follicular lymphoma diagnosed between 2004 and 2007 in the United States. *Cancer* 120:1830-1837, 2014
  - 5 Jaeger U, Trnely M, Melzer H, Praxmarer M, Nawarawong W, *et al.*: Rituximab maintenance for patients with aggressive B-cell lymphoma in first remission: results of the randomized NHL13 trial. *Haematologica* 100:955-963, 2015
  - 6 Younes A, Bartlett NL, Leonard JP, Kennedy DA, Lynch CM, *et al.*: Brentuximab vedotin (SGN-35) for relapsed CD30-positive lymphoma. *N Eng J Med* 363:1812-1821, 2010
  - 7 Younes A, Gopal AK, Smith SE, Ansell SM, Rosenblatt JD, *et al.*: Results of a pivotal phase II study of brentuximab vedotin for patients with relapsed or refractory Hodgkin's lymphoma. *J Clin Oncol* 30:2183-2189, 2012
  - 8 Linch DC, Winfield D, Goldstone AH, Moir D, Hancock B, *et al.*: Dose intensification with autologous bone-marrow transplantation in relapsed and resistant Hodgkin's disease: results of a BNLI randomised trial. *Lancet* 341:1051-1054, 1993
  - 9 Philip T, Guglielmi C, Hagenbeek A, Somers R, Van der Lelie H, *et al.*: Autologous bone marrow transplantation as compared with salvage chemotherapy in relapses of chemotherapy-sensitive non-Hodgkin's lymphoma. *N Engl J Med* 333:1540-1545, 1995
  - 10 Yuen AR, Rosenberg SA, Hoppe RT, Halpern JD, Horning SJ: Comparison between conventional salvage therapy and high-dose therapy with autografting for recurrent or refractory Hodgkin's disease. *Blood* 89:814-822, 1997
  - 11 Russell NH, Pacey S: Economic evaluation of peripheral blood stem cell transplantation for lymphoma. *Lancet* 340:1290, 1992
  - 12 Schmitz N, Linch DC, Dreger P, Goldstone AH, Boogaerts MA, *et al.*: Randomised trial of filgrastim-mobilised peripheral blood progenitor cell transplantation versus autologous bone-marrow transplantation in lymphoma patients. *Lancet* 347(9005):353-357, 1996
  - 13 Moskowitz CH, Bertino JR, Glassman JR, Hedrick EE, Hunte S, *et al.*: Ifosfamide, carboplatin, and etoposide: a highly effective cytoreduction and peripheral-blood progenitor-cell mobilization regimen for transplant-eligible patients with non-Hodgkin's lymphoma. *J Clin Oncol* 17:3776-3785, 1999
  - 14 Proctor SJ, Taylor PR, Angus B, Wood K, Lennard AL, *et al.*: High-dose ifosfamide in combination with etoposide and epirubicin (IVE) in the treatment of relapsed/refractory Hodgkin's disease and non-Hodgkin's lymphoma: a report on toxicity and efficacy. *Eur J Haematol Suppl* 64:28-32, 2001
  - 15 Proctor SJ, Jackson GH, Lennard A, Angus B, Wood K, *et al.*: Strategic approach to the management of Hodgkin's disease incorporating salvage therapy with high-dose ifosfamide, etoposide and epirubicin: a Northern Region Lymphoma Group study (UK). *Ann Oncol* 14 (Suppl 1):i47-i50, 2003
  - 16 Bishton MJ, Lush RJ, Byrne JL, Russell NH, Shaw BE, *et al.*: Ifosfamide, etoposide and epirubicin is an effective combined salvage and peripheral blood stem cell mobilisation regimen for transplant-eligible patients with non-Hodgkin lymphoma and Hodgkin disease. *Br J Haematol* 136:752-761, 2007
  - 17 Fox CP, McMillan AK, Bishton MJ, Haynes AP, Russell NH: IVE (ifosfamide, epirubicin and etoposide) is a more effective stem cell mobilisation regimen than ICE (ifosfamide, carboplatin and etoposide) in the context of salvage therapy for lymphoma. *Br J Haematol* 141:244-248, 2008
  - 18 Zinzani PL, Barbieri E, Visani G, Gherlinzoni F, Perini G, *et al.*: Ifosfamide, epirubicin and etoposide (IEV) therapy in relapsed and refractory high-grade non-Hodgkin's lymphoma and Hodgkin's disease. *Haematologica* 79:508-512, 1994
  - 19 McQuaker IG, Haynes AP, Stainer C, Anderson S, Russell NH: Stem cell mobilization in resistant or relapsed lymphoma: superior yield of progenitor cells following a salvage regimen comprising ifosfamide, etoposide and epirubicin compared to intermediate-dose cyclophosphamide. *Br J Haematol* 98:228-233, 1997
  - 20 McQuaker I, Haynes A, Stainer C, Byrne J, Russell N.: Mobilisation of peripheral blood stem cells with IVE and G-CSF improves CD34<sup>+</sup> cell yields and engraftment in patients with non-Hodgkin's lymphomas and Hodgkin's disease. *Bone Marrow Transplant* 24:715-722, 1999
  - 21 Menzel H, Müller A, Von Schilling C, Licht T, Peschel C, *et al.*: Ifosfamide, epirubicin and etoposide rituximab in refractory or relapsed B-cell lymphoma: analysis of remission induction and stem cell mobilization. *Leuk Lymphoma* 49:1337-1344, 2008
  - 22 Tajino T, Kikuchi S, Yamada H, Takeda A, Konno S: Ifosfamide encephalopathy associated with chemotherapy for musculoskeletal sarcomas: incidence, severity, and risk factors. *J Orthop Sci* 15:104-111, 2010