

Letter to the Editor

Infectious mononucleosis lymphadenitis resembling Kikuchi's disease: Cytological, histopathological, and immunohistological findings.

Atsuko Takada,¹⁾ Kazuhiko Shimizu,²⁾ Yoshimasa Nakazato,¹⁾
Kensuke Ohikata,¹⁾ Shigeru Tsuchida,³⁾ Misa Iijima,³⁾
Masaru Kojima¹⁾

Keywords: Infectious mononucleosis lymphadenitis, Kikuchi disease, Epstein-Barr virus, myeloperoxidase.

TO THE EDITOR

Kikuchi's disease (KD) is a benign self-limited disease, most frequently seen in young Asians, with painless cervical lymphadenopathy and systemic symptoms such as fever.¹ The characteristic cytological findings of KD include tingible body macrophages with crescent-shaped nuclei, prominent karyorrhectic nuclei and the absence of neutrophils.²⁻⁴ The causative agents of KD remain unknown. However, Epstein-Barr virus (EBV)-encoded mRNA (EBER) was found in a few cases by *in situ* hybridization (ISH).^{1,5} Here, we report, here, cytological, histopathological, and immunohistochemical findings of a case of infectious mononucleosis (IM) resembling KD.

A 40-year-old Japanese woman presented with bilateral cervical lymphadenopathy. A lymph node biopsy was performed and she was tentatively diagnosed with malignant lymphoma. Laboratory studies demonstrated a white blood cell count of 5.260/mm³ with lymphocytosis of 45% including 3% atypical forms, a slightly elevated LDH level (245 <229 IU/L), and moderately abnormal liver function tests: ALT (74 <27 IU/L) and AST (125 <47 IU/L). Subsequent

serologic tests for EBV showed the following results: a viral capsid antigen (VCA) IgG titer of 0.2 (normal range <1), VCA IgM titer of 0.6 (normal range <0.5), and an antigen (EBNA) titer of 0.1 (normal range <0.5). There was no further treatment administered, and the patient was well at the last follow-up two months later.

Cytological examination of the imprint smears demonstrated a polymorphic lymphoid cell population, including numerous tingible body macrophages, and isolated or small clusters of epithelioid cells (Fig.1). No macrophages with crescent nuclei were observed in the smear. The majority of the lymphoid cells were small to medium-sized lymphocytes with scattered large transformed lymphocytes and immunoblasts (Fig.1). On Giemsa staining of a smear, the immunoblasts had round nuclei with fine nuclear chromatin, and large central nucleoli, and relatively broad basophilic cytoplasm. Some of them had a perinuclear halo (Fig. 2). Moreover, mature plasma cells, binucleated plasma cells, and cells with plasma cell differentiation were also intermingled with these cells. The epithelioid cells had an oval or elongated vesicular nuclei, and abundant amphophilic cytoplasm (Fig. 1). The lesion contained only a few neutrophils.

Histologically, in a low-power field, the lesion contained a focally coagulative necrotic area (Fig. 2). Lymphoid follicles were not prominent. In a high-power field, the lesion was composed of small to medium-sized lymphocytes, large transformed lymphocytes, immunoblasts, tingible body macrophages, epithelioid cells, cells with plasma cell differentiation, and plasma cells (Fig. 5). CD3 and CD20 immunostain demonstrated the mixed natures of large transformed lymphocytes and immunoblasts. CD15 immunostain demonstrated only a few neutrophils. Scattered myeloperoxidase-positive

Received: December 5, 2016

Revised : December 23, 2016

Accepted: December 27, 2016

¹⁾Department of Diagnostic Pathology, Dokkyo University School of Medicine, Mibu, Japan.

²⁾Department of Pathology and Clinical Laboratories, Ashikaga Red Cross Hospital, Ashikaga, Japan.

³⁾Department of Clinical Laboratory, Gunma Prefectural Cancer Hospital, Ohta, Gunma.

Corresponding author: Masaru Kojima, M.D., Department of Diagnostic Pathology, Tokyo University School of Medicine, Mibu, 321-0293, Japan.

E-mail: k-masaru@dokkyomed.ac.jp

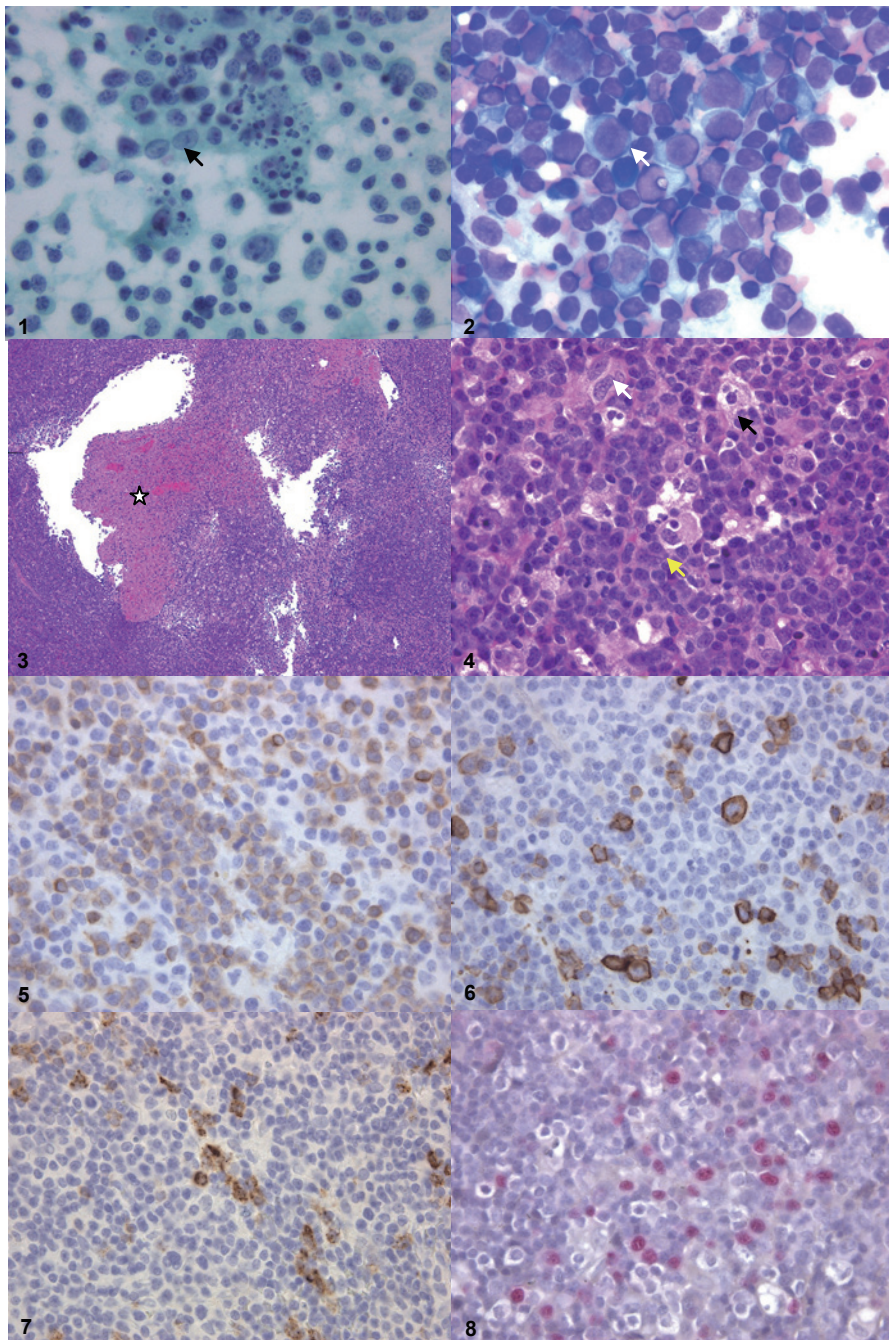


Fig. 1. Imprint smears demonstrated a polymorphic lymphoid cell population, including numerous tingible body macrophages, and isolated or small clusters of epithelioid cells (arrow). The majority of the lymphoid cells were small to medium-sized lymphocytes. Pap x100.

Fig. 2. The immunoblasts had round nuclei with fine nuclear chromatin, large central nucleoli, and relatively broad basophilic cytoplasm. Some of them had a perinuclear halo. Note the mature plasma cells, binucleated plasma cells, and cells with plasma cell differentiation (arrow).

Fig. 3. In a low-power field, the lesion contained a focally coagulative necrotic area (star). HEx10

Fig. 4. In a high-power field, the lesion was composed of small to medium-sized lymphocytes, large transformed lymphocytes, immunoblasts, tingible body macrophages (black arrow), epithelioid cells (white arrow), cells with plasma cell differentiation (yellow arrow), and plasma cells. HEx40

CD3 (Fig.5) and CD20(Fig.6) immunostain demonstrated mixed nature of large lymphoid cells.x40

Fig. 7. Myeloperoxidase immunostain demonstrated scattered positive macrophages. x40

Fig. 8. The ISH method demonstrated numerous EBER.

macrophages were present in the lesion (Fig. 5). Only a few CD30-positive cells were found in the lesion. However, plasmacytoid dendritic cells were absent in the lesion. The ISH method demonstrated numerous large EBER-positive lymphoid cells (Fig. 6).

Characteristic cytomorphological findings of IM are a polymorphous population of lymphocytes admixed with tingible body macrophages, as well as plasmacytoid lymphocytes.^{4,6,7} Stanley reported that an intermediate to large sized polymorphic immunoblastic proliferation is a diagnostic clue for IM lymphadenitis.⁶ However, the present case had some characteristic cytological findings of KD, including the presence of numerous large immunoblasts and tingible body macrophages, and only a few neutrophils.²⁻⁴ Moreover, histological specimens contained a focal necrotic area. Immunohistochemical study also demonstrated myeloperoxidase-positive macrophages, which is one of the characteristic immunological findings of KD.⁸⁻¹⁰ However, the presence of epithelioid histiocytes and cells with plasma cell differentiation, and absence of tingible body macrophages with crescent-shaped nuclei and plasmacytoid dendritic cells in this case are different from KD.^{9,10} Immunohistochemical study demonstrated mixed nature of large lymphoid cells are also different from KD.¹ Stanley described numerous tingible body macrophages in 2 of 10 cases by cytological examination.⁶ This case appears to show similar cytological findings to their cases.⁶ IM is an acute lymphoproliferative disorder (LPD) that typically occurs in young patients and is usually caused by EBV.^{7,11} The diagnosis of IM is usually based on clinical and serologic findings.⁷ However, lymphoid tissue biopsy or aspiration cytology may be performed when malignant lymphoma is a clinical consideration in patients demonstrating atypical clinical features.¹¹⁻¹² Atypical features include an age over 30 years, generalized lymphadenopathy or isolated lymphadenopathy at an unusual site, a negative heterophil antibody titer, or absence of atypical lymphocytosis in the peripheral blood.^{11,12} This case involved a 40-year-old Japanese female and only a few atypical lymphocytes were detected in the peripheral blood. In conclusion, the present case indicates that IM further confuses the differential diagnosis of KD.

CONFLICT OF INTEREST

The authors declare no conflict of interest in this study.

REFERENCES

- O'Malley DP, Gerorge TI, Orazi A, Abbondanzo SL. Atlas of Nontumor Pathology, first series, fascicle 7, Benign and Reactive Conditions of Lymph Node and Spleen. Washington DC, Armed Forces Institute of Pathology, pp. 150-155 2009
- Tong TRS, Chan OW, Lee K: Diagnosing Kikuchi disease on fine needle aspiration biopsy: a retrospective study of 44 cases diagnosed by cytology and 8 by histopathology. *Acta Cytol* 45:953-957, 2001
- Kishimoto K, Tate G, Kitamura T, Kojima M, Mitsuya T: Cytological features and frequency of plasmacytoid dendritic cells in the lymph nodes of patients with histiocytic necrotizing lymphadenitis (Kikuch-Fujimoto disease). *Diagn Cytopathol* 38:521-526, 2010
- Monaco SE, Pantanowitz L, Khalbuss WE: Cytopathology of Non-Neoplastic and Infectious Lymphadenopathy. In: Cualing HD, Bhargava P, Sandin RL (eds): Non-neoplastic Hematopathology and Infections. Hoboken, Wiley-Blackwell, pp. 481-510, 2012
- Chiu C-F, Chow K-C, Lin T-Y, Tsai M-H, Shih C-M: Virus infection in patients with histiocytic necrotizing lymphadenitis in Taiwan. Detection of Epstein-Barr virus, Type I human T-cell lymphotropic virus, and parvovirus B19. *Am J Clin Pathol* 113: 774-781, 2000
- Stanley MW, Steeper TA, Horwitz CA, Burton LG, Strickler J, *et al*: Fine-needle aspiration of lymph nodes in patients with acute infectious mononucleosis. *Diagn Cytopathol* 6: 323-329, 1990
- Ioachim HL, Medeiros LJ: Ioachachim's Lymph Node Pathology, 4th ed, Philadelphia, Lippincott Williams & Wilkins, pp.199-202, 2009
- Pileri SA, Facchetti F, Ascani S, Sabattini E, Poggi S, *et al*: Myeloperoxidase expression by histiocytes in Kikuchi's and Kicuchi-like lymphadenopathy. *Am J Pathol* 159:915-924, 2001
- Asano S, Mori K, Yamazaki K, Sata T, Kurata A, *et al*: Necrotizing lymphadenitis (NEL) is a systemic disease characterized by blastic transformation of CD8+ cells and apoptosis of CD4+ cells. *Virchows Arch* 464:95-103, 2014
- Sato H, Asano S, Mori K Yamazaki K, Wakasa H: Plasmacytoid dendritic cells producing interferon- α (IFN- α) and inducing Mx1 play an important role for CD4+ cells and CD8+ cells in necrotizing lymphadenitis. *JCEH* 55:127-135, 2015
- Strickler JG, Fedeli F, Horwitz CA, Copenhaver CM, Frizzera G: Infectious mononucleosis in lymphoid tissue-histopathology, in situ hybridization and differential diagnosis. *Arch Pathol Lab Med* 117:269-278, 1993
- Horwitz CA, Henle W, Henle G, Schapiro R, Borken S, *et al*: Infectious mononucleosis in patients aged 40 to 72 years: report of 27 cases, including 3 without heterophil-antibody responses. *Medicine* 62:256-262, 1983