

Conference Case

# A rare case of mixed phenotype acute leukemia- B/T cell type

**Keywords:** Mixed phenotype acute leukemia; B/T- cell phenotype; flowcytometric immunophenotyping.

## CASE REPORT

Mixed phenotype acute leukemia (MPAL) with B/T cell type is very rare. A 24-year-old male presented with fever, generalized body ache, cough and breathlessness, bleeding per rectum, epistaxis, and hepatosplenomegaly. His hemoglobin, total leukocyte count, and platelet count were 6.2 g/dL,  $29.06 \times 10^3/\mu\text{L}$ , and  $20 \times 10^3/\mu\text{L}$  respectively. Peripheral blood smear & bone marrow revealed > 80% blasts that were morphologically lymphoid. The blasts were negative for all cytochemical staining. Flow cytometry immunophenotyping was performed on peripheral blood using a 6- color flow cytometer Navios (Beckman Coulter) using CD1a, CD2, CD3, CD4, CD5, CD7, CD8, CD10, CD13, CD14, CD15, CD19, CD20, CD22, CD33, CD34, CD38, HLA-DR, CD45, CD56, CD61, CD64, Glycophorin A, CD117, cytoplasmicCD3, cytoplasmic CD79a, myeloperoxidase (MPO), and terminal deoxynucleotidyl transferase (TdT). The blast cells on CD45 vs SSC exhibited two distinct populations, one (45.9%) with weak and another (23.7%) with moderate expression of CD45 and low side scatter. The population of blasts with weak CD45 expression was positive for CD19 (strong), CD10 (strong), cCD79a (moderate), HLA-DR (moderate), CD38 (weak) and TdT. The population of blasts moderately positive for CD45 was positive for cytoplasmic CD3 (moderate), cCD79a, CD7 (strong), CD1a (moderate), CD4 (strong), TdT, CD5 (moderate), and CD38 (strong), and negative for surface CD3, HLA-DR, CD8, and CD2.

The final diagnosis of MPAL -B/T cell type was established.

The diagnostic criteria of MPAL are based on expression of strictly T-lymphoid (cytoplasmic CD3)- and myeloid (MPO)-specific antigens, the latter demonstrated by either flow cytometry (FCM) or cytochemistry, and/or evidence of monocytic differentiation. B-cell lineage assignment in MPAL relies on strong expression of CD19 together with another B-cell-associated marker or, in cases with weak CD19, on the strong expression of at least 2 B-lineage markers.<sup>1</sup> MPAL is very rare and constitutes <4% of all cases of acute leukemia. The most common type is MPAL- Myeloid/ B cell type. The leukemic blasts very rarely exhibit clear evidence of both T and B lineage commitment. However, as CD79a and CD10 are frequently reported in T-ALL, B/T MPAL should be differentially diagnosed.<sup>2</sup>

The precursor status of T lymphoblasts can be established by TdT, CD99, CD34, and/or CD1a positivity.<sup>3</sup> The panel of antibodies used is important in the identification of the

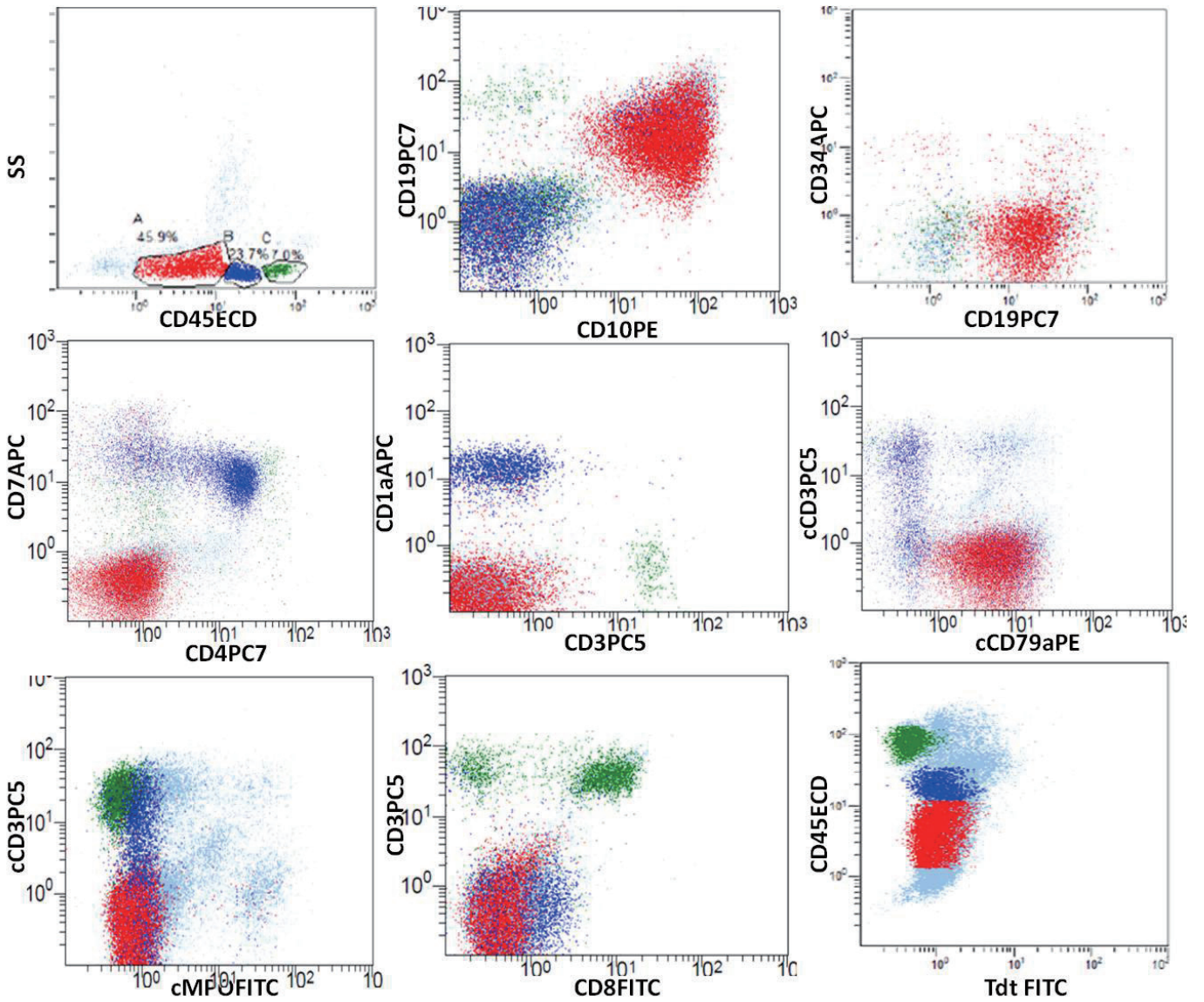
“mixed” phenotype. TdT and CD1a should be included in the panel when immaturity markers like CD34 are negative.

## CONFLICT OF INTEREST

The authors declare no conflict of interest in this study.

## REFERENCES

- 1 Swerdlow SH, Campo E, Harris NL, et al. World Health Organization Classification of Tumours: Pathology and Genetics of Tumours of Haematopoietic and Lymphoid Tissues. Lyon, France: IARC Press, pp. 150-155, 2008
- 2 Cherian S, Wood B: Case 35. In: Cherian S, Wood B (eds): Flow cytometry in evaluation of hematopoietic neoplasms: A case based approach. Northfield, Illinois, College of American Pathologists, pp.149-151, 2012
- 3 Borowitz MJ, Chan JKC. : Lymphoblastic leukaemia/lymphoma. In: Swerdlow SH, Campo E, Harris NL, Jaffe ES, Pileri SA, et al. (eds): WHO Classification of Tumours of Haematopoietic and Lymphoid Tissues. 4th ed, Lyon, France, IARC Press, pp. 176-178, 2008



**Fig. 1.** Dot plots with CD45 vs SSC showing two blast populations highlighted in red(B-blasts) and blue(T-blasts) & lymphocyte population in green. These dot plots demonstrate the expression of CD19, CD10 in B lineage blasts; CD7, CD4, cCD3, CD1a in T lineage blasts and cCD79a, TdT expression in both the lineage blasts.

**Jain Monica, Mittal Dipali, Shukla Pragya, Jena, Nihar**  
Delhi State Cancer Institute, New Delhi, India  
E-mail: drmonica123@gmail.com

Received: November 17, 2016.

Revised: February 1, 2017.

Accepted: March 27, 2017.

Kayano H

## EXPERT'S COMMENTS

The WHO classification of hematological malignancies<sup>1</sup> defines mixed phenotype acute leukemia (MPAL) as acute leukemia with blasts expressing antigens of more than one lineage. As *bona fide* acute leukemia may demonstrate aberrant blast antigen expression, MPAL diagnosis is based on exclusion. MPAL is further divided into four subtypes with specific chromosomal translocations, t(9;22)(q34.1;q11.2), or t(v;11q23.3), and those with mixed myeloid and lymphoid phenotypes (B or T-cell lineages). Multi-parameter flow-cytometry is the leading tool for MPAL diagnosis, and parallel molecular studies are also highly informative.

A large MPAL immunophenotyping study<sup>2</sup> found B-cell and myeloid lineages in 59% of cases, T-cell plus myeloid lineages in 35% of cases, B-cell plus T-cell lineages in 4% of cases, and trilineage combinations in 2% of cases. The current case may represent a rare example of MPAL with a blast population comprising two distinct phenotypes - one with weak CD45 expression by the B-lymphoid lineage and the other with moderate CD45 expression by the T-lymphoid lineage.

However, the lack of genetic information does not necessarily exclude the diagnosis of MPAL because in MPAL cases with two distinct blast populations it is not necessary for the specific markers to be present; rather, each individual population should meet the definition for either B, T, or myeloid leukemia.

## REFERENCES

- 1 Arber DA, Orazi A, Hasserjian R, *et al.*: The 2016 revision to the World Health Organization (WHO) classification of myeloid neoplasms and acute leukemia. *Blood* 127; 2391-2405, 2016
- 2 Matutes E, Pickl WF, van't Veer M, *et al.*: Mixed-phenotypic acute leukemia: clinical and laboratory features and outcome in 100 patients defined according to the WHO 2008 classification. *Blood* 117; 3163-3171, 2011

**Hidekazu Kayano**  
Saitama Medical University  
E-mail: [hidekazu@saitama-med.ac.jp](mailto:hidekazu@saitama-med.ac.jp)