

Review Article

# Current treatment approaches for NK/T-cell lymphoma

Motoko Yamaguchi, Kana Miyazaki

Extranodal NK/T-cell lymphoma, nasal type (ENKL), is a form of lymphoma characterized by preferential extranodal involvement, Epstein-Barr virus (EBV) association, and geographic diversity in incidence. ENKL tumor cells express P-glycoprotein, which is related to multidrug resistance (MDR). This MDR phenomenon is thought to be the major reason why ENKL is resistant to anthracycline-containing chemotherapies and has led researchers to explore novel therapeutic strategies. Since the early 2000s, next-generation therapies, including upfront radiotherapy, chemotherapy, or concurrent chemoradiotherapy using non-MDR-related drugs, have markedly changed the management of ENKL. However, a recent large retrospective study in Japan revealed several limitations of next-generation therapies, in particular that they resulted in almost no improvement of early disease progression. This review will summarize the current management of ENKL, primarily based on clinical trial results, and provide clues for better future management.

**Keywords:** NK/T-cell lymphoma, prognostic model, treatment, guidelines

## INTRODUCTION

Extranodal natural killer/T-cell lymphoma, nasal type (ENKL) is characterized by preferential extranodal involvement, angioinvasion or destruction, massive necrosis, expression of cytotoxic molecules, and Epstein-Barr virus (EBV) association.<sup>1</sup> It is much more common in Asia and Latin America than in Western countries; it comprises approximately 3 to 10% of all lymphomas in East Asia, but less than 1% in Western countries.<sup>2</sup> The NK-cell origin is more common than the cytotoxic T-cell origin in ENKL. More than 65% of patients with ENKL have lymphomatous involvement in the nasal area.

Before the 2000s, patients with ENKL were traditionally treated with anthracycline-containing chemotherapies, such as cyclophosphamide, doxorubicin, vincristine, and prednisone (CHOP), and the therapeutic outcomes were insufficient.<sup>3,4</sup> Since the early 2000s, next-generation therapies avoiding the use of anthracycline have been developed in prospective clinical trials and have markedly changed the management of ENKL. This review summarizes the results of clinical studies of ENKL, with some information on the current management of ENKL in Japan.

## CLINICAL FEATURES AT DIAGNOSIS

With the exception of age, the clinical features of ENKL at diagnosis are comparable among countries. The typical clinical features of ENKL at diagnosis are as follows: median

age, 40-58 years; male sex, 65%; stage I or II, 70-75%; serum lactate dehydrogenase (LDH) level > upper limit of normal (ULN), 45%; ECOG performance status (PS) > 1, 10-25%; B symptoms present, 35-45%; and nasal involvement, 87%.<sup>5-7</sup> The median age at diagnosis of patients with ENKL is approximately 10 years younger than that of patients with diffuse large B-cell lymphoma (DLBCL). Of note, the median age in reports from China is approximately 40 years,<sup>8</sup> which is almost 10 years younger than that reported in Japan and the United States.<sup>7,9</sup>

The diagnostic criteria of ENKL in the 2016 WHO classification are almost the same as those in the 2008 version.<sup>1,10</sup> However, attention should be paid to discriminate lymphomatoid gastropathy (LyGa)<sup>11</sup> and NK-cell enteropathy<sup>12</sup> from ENKL. Patients with these diseases are negative for EBV-encoded small RNA (EBER), and angioinvasion is rare. LyGa and NK-cell enteropathy are benign diseases and are curable without any treatment.

## BASELINE EVALUATION BEFORE TREATMENT

It is often difficult to identify the tumor extension of ENKL by computed tomography (CT) due to its low power resolution. ENKL sometimes involves the skin and subcutaneous tissue in extremities, which are not evaluated by routine CT. Considering that ENKL is a routinely fluorodeoxyglucose (FDG)-avid lymphoma,<sup>13,14</sup> whole-body positron emission tomography (PET)/CT is the most suitable procedure for staging in ENKL. Magnetic resonance imaging is superior to CT in resolution power and is useful for detecting

Received: April 10, 2017. Revised: April 26, 2017. Accepted: May 8, 2017. J-STAGE Advance Published: July 6, 2017

Department of Hematology and Oncology, Mie University Graduate School of Medicine, Tsu, Japan

**Corresponding author:** Motoko Yamaguchi, M.D., Ph.D. Department of Hematology and Oncology, Mie University Graduate School of Medicine, 2-174 Edobashi, Tsu, Mie 514-8507, Japan.

E-mail: myamaguchi@clin.medic.mie-u.ac.jp

lymphomatous involvement in the nasal area, and is frequently used in radiation planning.

The international prognostic index (IPI) is valid for the prognostication of ENKL as well as DLBCL or other lymphomas; however, it has the limitation that most patients with localized ENKL are classified in the low or low-intermediate risk categories.<sup>15</sup> Another limitation of the IPI is a lack of consensus regarding how to count the number of sites of extranodal involvement in ENKL. The NK/T-cell lymphoma prognostic index (NK-PI) was proposed as a risk model for ENKL in 2006<sup>16</sup> (Table 1). NK-PI risk factors include the presence of B symptoms, stage III or IV disease, serum LDH level > ULN, and regional lymph node involvement. The NK-PI has been validated by an international cooperative study<sup>5</sup> and widely used in clinical practice. Some studies have suggested that the NK-PI is not prognostic for patients receiving next-generation therapy because it was established using data from patients who were treated with conventional chemotherapies such as CHOP.<sup>17</sup>

The prognostic index of natural killer lymphoma (PINK) was proposed in 2016 as a prognostic model for patients with ENKL treated with non-anthracycline-containing chemotherapy with or without radiotherapy, or radiotherapy with curative intent.<sup>6</sup> Four independent risk factors of PINK are age > 60 years, stage III or IV disease, distant lymph node involvement, and non-nasal type disease (Table 1). In patients with localized nasal ENKL, the involvement of axillary, infraclavicular, and mediastinal lymph nodes is regarded as distant lymph node involvement, supporting the conventional thought that the treatment used for localized ENKL is not suitable for non-contiguous stage II ENKL. The NK-PI has been replaced by PINK as the pretreatment risk model of ENKL in the National Comprehensive Cancer Network (NCCN) guidelines of peripheral T-cell lymphoma since 2017 version 1.<sup>18</sup>

The EBV-DNA copy number in peripheral blood is a valid indicator of both the response to treatment and overall survival (OS) of patients with ENKL.<sup>19-21</sup> PINK-E, which is a combined model that uses the four risk factors of PINK and detectable pretreatment plasma EBV-DNA levels (Table 1), also predicts survival of ENKL patients.<sup>6</sup>

### GENERAL PRINCIPLES OF FRONT-LINE THERAPY

ENKL is an aggressive lymphoma and has been traditionally treated with the same strategy as other aggressive lymphomas, mainly with anthracycline-containing chemotherapy. The reported 5-year OS rates for patients with localized nasal ENKL treated with CHOP followed by involved-field radiotherapy are less than 50%. Tumor cells in ENKL express the multidrug resistance (MDR) 1/ABCB1 gene and its product, P-glycoprotein.<sup>22-24</sup> This MDR phenomenon is believed to be the major reason why ENKL is resistant to CHOP (-like) chemotherapies that consist mainly of MDR-related agents and has led to the development of novel therapeutic strategies such as upfront radiotherapy with or without non-MDR-related chemotherapy. These therapies have been developed in clinical trial settings since the early 2000s.

Current guidelines recommend treatments including local radiotherapy for newly diagnosed nasal ENKL patients with stage I and contiguous stage II disease with cervical lymph node involvement and chemotherapy with L-asparaginase (L-asp) and/or non-MDR-related agents for newly diagnosed advanced ENKL patients.<sup>18,25,26</sup> Due to the rarity of the disease and the difficulty of conducting randomized controlled trials, the optimal treatment regimen has not been determined. Treatment details differ among countries, especially for localized ENKL, and these differences are primarily due to preference and the logistics of radiotherapy. A treatment scheme for ENKL from the 2013 Japanese Society of

**Table 1.** Three prognostic models for ENKL

	NK-PI <sup>16</sup>	PINK <sup>6</sup>	PINK-E <sup>6</sup>
Treatment	Conventional therapy (e.g., CHOP)	Chemotherapy without anthracycline with or without local radiotherapy with curative intent	
Risk factors	<ul style="list-style-type: none"> <li>•B symptoms</li> <li>•Stage III or IV disease</li> <li>•Serum LDH &gt; ULN</li> <li>•Regional LN* involvement</li> </ul>	<ul style="list-style-type: none"> <li>•Age &gt; 60 years</li> <li>•Stage III or IV disease</li> <li>•Non-nasal type</li> <li>•Distant LN** involvement</li> </ul>	<ul style="list-style-type: none"> <li>•Four risk factors of PINK</li> <li>•Detectable EBV-DNA</li> </ul>
Number of risk factors in each risk group	Group 1: 0 Group 2: 1 Group 3: 2 Group 4: 3, 4	Low: 0 Intermediate: 1 High: 2 - 4	Low: 0 - 1 Intermediate: 2 High: 3 - 5
Survival in each risk group	OS rate at 5 years Group 1: 81% Group 2: 64% Group 3: 34% Group 4: 7%	OS rate at 3 years Low: 81% Intermediate: 62% High: 25%	OS rate at 3 years Low: 81% Intermediate: 55% High: 28%

\*Cervical lymph nodes in the case of nasal ENKL.

\*\*Axillary, infraclavicular, and mediastinal lymph nodes in the case of nasal ENKL.

EBV, Epstein-Barr virus; LDH, lactate dehydrogenase; LN, lymph node; NK-PI, NK/T-cell lymphoma prognostic index; OS, overall survival; PINK, prognostic index of natural killer lymphoma; ULN, upper normal limit.

Hematology (JSH) guidelines<sup>25</sup> is shown in Fig. 1.

## TREATMENT FOR NEWLY DIAGNOSED LOCALIZED NASAL ENKL

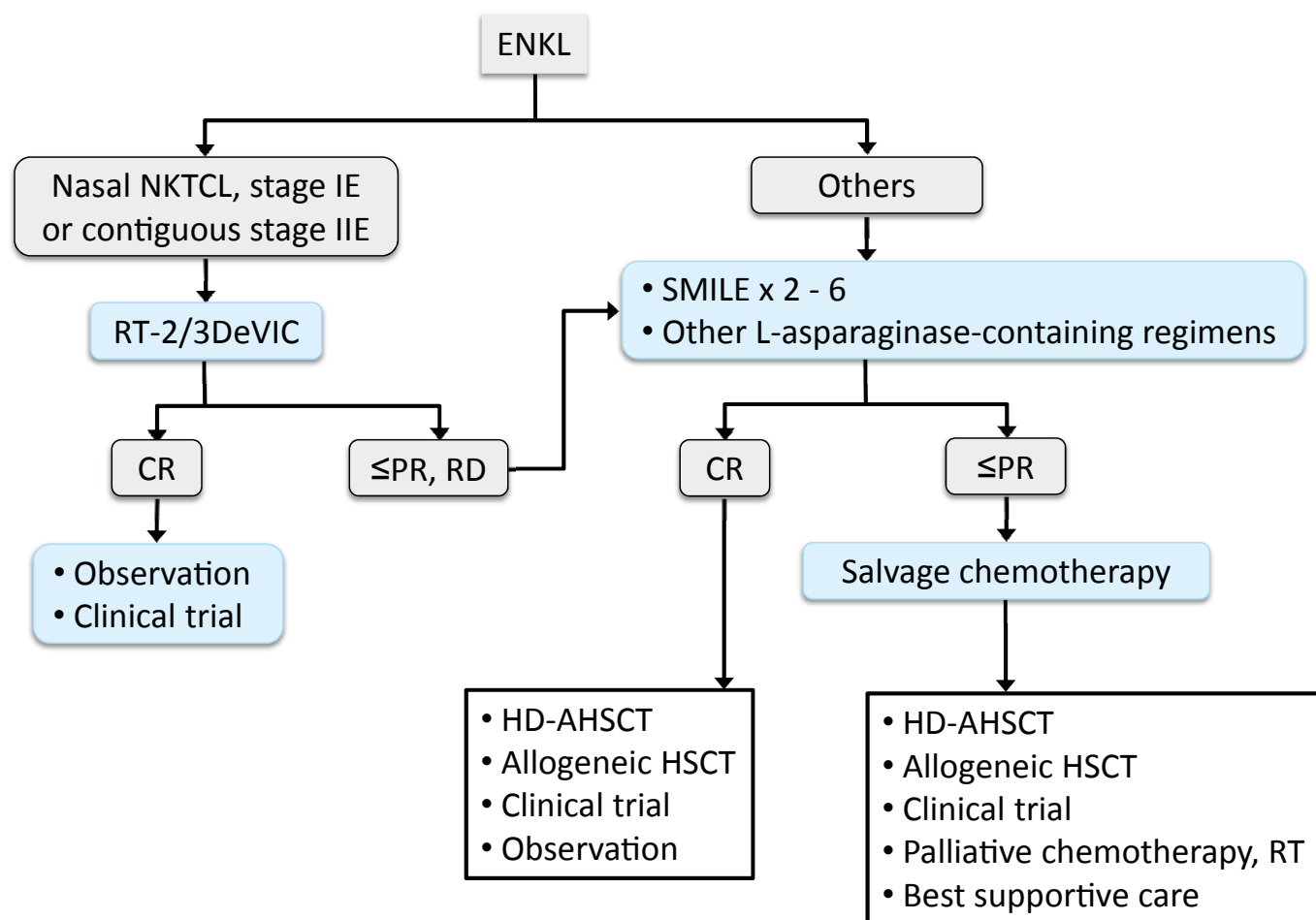
### Concurrent chemoradiotherapy

Concurrent chemoradiotherapy was the first treatment tested in a qualified clinical trial setting for ENKL. The combination of local radiotherapy and cisplatin or multi-agent chemotherapy consisting of non-MDR-related agents is common for the treatment of ENKL.

Concurrent chemoradiotherapy consisting of radiotherapy and DeVIC (dexamethasone, etoposide, ifosfamide, and carboplatin) chemotherapy (RT-DeVIC)<sup>27</sup> was explored in a phase I/II study for patients with newly diagnosed stage IE or contiguous stage IIE nasal ENKL (Japan Clinical Oncology Group [JCOG] 0211).<sup>28,29</sup> Radiotherapy at a dose of 50 Gy (3-dimensional conformal radiotherapy encompassing the primary site and organ with a 2-cm margin) and 3 cycles of DeVIC are initiated simultaneously (Fig. 2). A two-thirds dose of DeVIC was established as the recommended dose (Table 2). Phase II of the trial, which evaluated 27 patients treated with RT-2/3DeVIC, showed an overall response rate

(ORR) of 81%, complete response (CR) rate of 77%, 5-year OS rate of 70% (90% confidence interval [CI]:53-82%), 5-year progression-free survival (PFS) rate of 63%, and 5-year planned target volume control rate of 94% at a median follow-up of 67 months (range, 61-94).<sup>29</sup> The most frequent Grade 3 adverse event was mucositis due to radiotherapy (30%). A concomitant study of the trial demonstrated that the expression of latent membrane protein (LMP) 1 in tumor cells was a favorable prognostic factor.<sup>17</sup>

The results from the JCOG0211 study were confirmed by a retrospective study including patients diagnosed between 2000 and 2013 in 31 institutes in Japan (Next-generation therapy for NK/T-cell lymphoma in East Asia [NKEA] project, Part A).<sup>7</sup> Of 257 patients with localized ENKL, 66% received RT-DeVIC as first-line therapy (RT-2/3DeVIC, 54%; RT-100%DeVIC, 12%; Fig. 3). The proportion of patients receiving RT-DeVIC between 2010 and 2013 was 82%. The baseline clinical characteristics were comparable to those in the clinical trial. With a median follow-up of 5.6 years, the 5-year OS and PFS rates in 150 patients treated with RT-DeVIC in clinical practice were 72% (95% CI, 63-78%) and 61% (95% CI, 52-69%), respectively, confirming the results from the clinical trial. Only two of them



**Fig. 1.** Treatment algorithm for ENKL in the 2013 JSH Guidelines<sup>25</sup>

CR, complete response; ENKL, extranodal NK/T-cell lymphoma, nasal type; HD-AHSCT, high-dose chemotherapy with autologous hematopoietic stem cell transplantation; NKTCL, NK/T-cell lymphoma; PR, partial response; RD, relapsed disease; RT, radiotherapy.

received consolidative HD-AHSCT.<sup>7</sup> There was no difference in OS or PFS between the RT-2/3DeVIC and RT-100%DeVIC groups in clinical practice, supporting the results in phase I of the trial. The toxicity in practice was comparable to that in the trial. A multivariate analysis identified that an elevated pretreatment serum soluble interleukin-2 receptor level was a strong independent prognostic factor for OS and PFS.

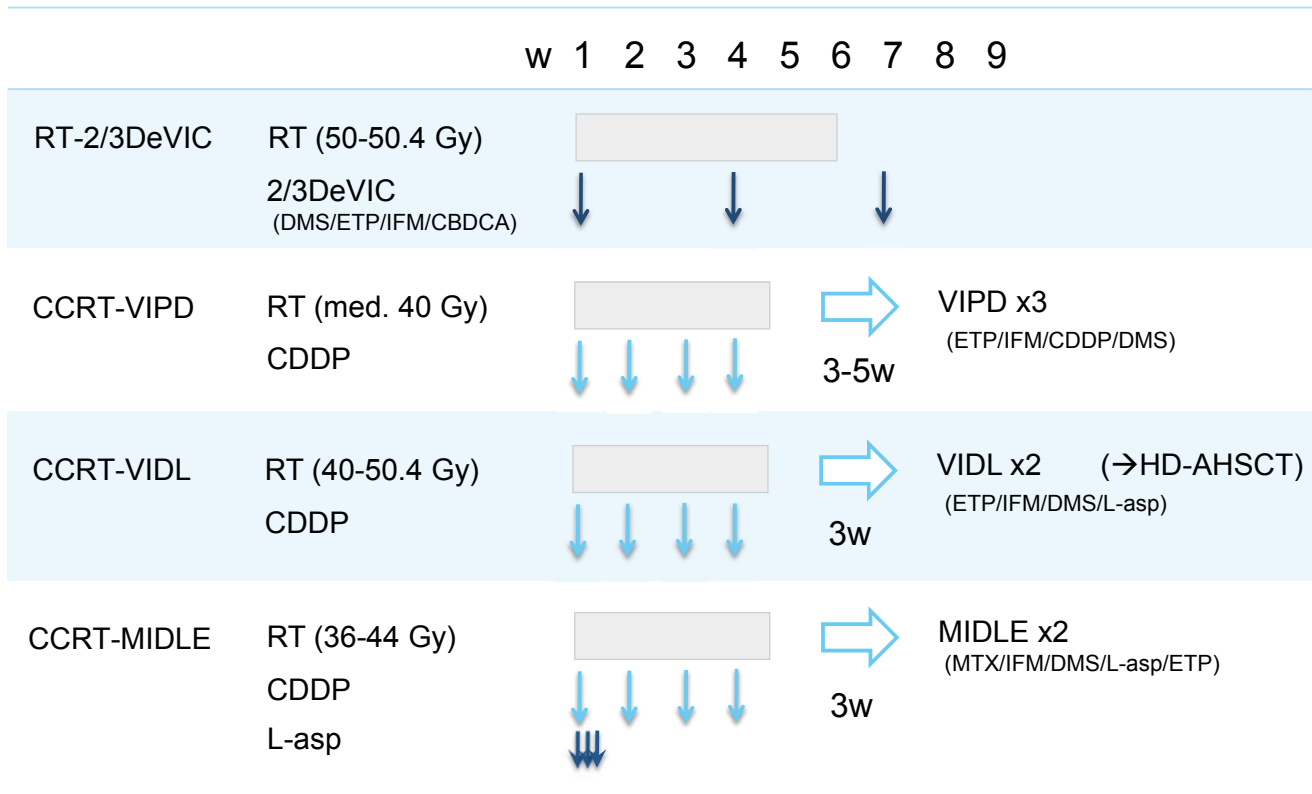
Since the mid-2000s, a study group in Korea (Consortium for Improving Survival of Lymphoma, CISL) has conducted three multicenter phase II studies of concurrent chemoradiotherapy followed by non-anthracycline-containing chemotherapy (Fig. 2).<sup>30-32</sup> In these treatments, cisplatin was selected for the concurrent chemoradiotherapy as a radiation sensitizer, and the median dose of radiotherapy was reduced to approximately 40-45 Gy (Fig. 2). The first study was a phase II trial

of concurrent chemoradiation (CCRT) combined with 3 courses of VIPD (etoposide, ifosfamide, cisplatin, and dexamethasone) chemotherapy for untreated localized nasal ENKL.<sup>30</sup> This study enrolled 30 patients and demonstrated a CR rate of 80%, and the estimated 3-year OS and PFS rates were 86 and 80%, respectively, at the median follow-up of 24 months (range, 17-37). The estimated 3-year local control rate was 93%. Two patients died of infection during VIPD chemotherapy. The next trial tested CCRT followed by 2 courses of VIDL (etoposide, ifosfamide, dexamethasone, and L-asp; Table 2) chemotherapy, and high-dose autologous hematopoietic stem cell transplantation (HD-AHSCT) was added for patients with two or three NK-PI risk factors.<sup>31</sup> The CR rate and the 5-year OS rate were 87% and 73%, respectively, and toxicity was acceptable. A subsequent phase II study evaluated CCRT-MIDLE (methotrexate,

**Table 2.** Examples of chemotherapeutic regimens in new-generation therapies of ENKL

Regimen (interval)	Drug	Dose (/day)	Route	Day
2/3DeVIC <sup>28</sup> (3 weeks)	CBDCA	200 mg/m <sup>2</sup>	IV	1
	ETP	67 mg/m <sup>2</sup>	IV	1-3
	IFM	1.0 g/m <sup>2</sup>	IV	1-3
	DMS	40 mg	IV	1-3
VIDL <sup>31</sup> (4 weeks)	ETP	100 mg/m <sup>2</sup>	IV	1-3
	IFM	1.2 g/m <sup>2</sup>	IV	1-3
	DMS	40 mg	IV	1-3
	L-asp	4,000 IU/m <sup>2</sup>	IM	8, 10, 12, 14, 16, 18, 20
SMILE <sup>38</sup> (4 weeks)	MTX	2 g/m <sup>2</sup>	IV (6 hours)	1
	Leucovorin	15 mg x 4	IV or PO	2, 3, 4
	IFM	1,500 mg/m <sup>2</sup>	IV	2, 3, 4
	Mesna	300 mg/m <sup>2</sup> x3	IV	2, 3, 4
	DMS	40 mg	IV or PO	2, 3, 4
	ETP	100 mg/m <sup>2</sup>	IV	2, 3, 4
	L-asp	6,000 U/m <sup>2</sup>	IV	8, 10, 12, 14, 16, 18, 20
	G-CSF		SC or IV	6 - WBC > 5,000/ $\mu$ L
AspaMetDex <sup>48</sup> (3 weeks)	L-asp	6,000 U/m <sup>2</sup>	IM	2, 4, 6, 8
	MTX	3 g/m <sup>2</sup>	IV	1
	DMS	40 mg	PO	1-4
P-gemox <sup>56</sup> (3 weeks)	GEM	1,000 mg/m <sup>2</sup>	IV	1,8
	OXP	130 mg/m <sup>2</sup>	IV	1
	Peg-asp	2,500 IU/m <sup>2</sup>	IM	1
GDP <sup>57</sup> (3 weeks)	GEM	1,000 mg/m <sup>2</sup>	IV	1,8
	CDDP	25 mg/m <sup>2</sup>	IV	1-3
	DMS	20 mg	PO	1-4, 11-14

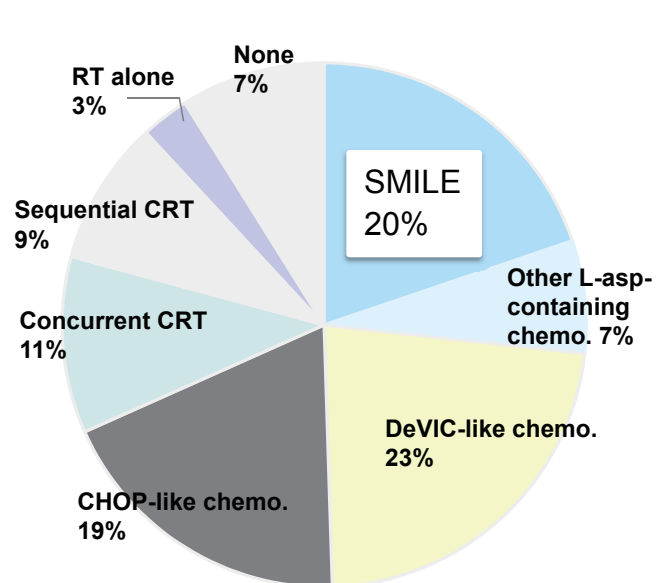
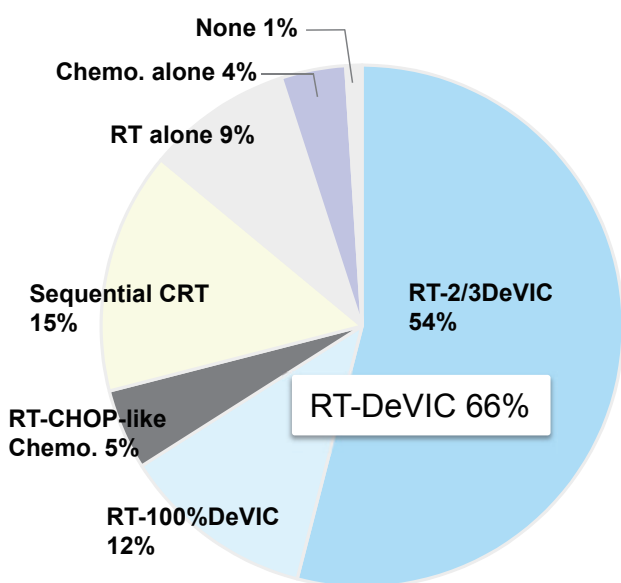
CBDCA, carboplatin; CDDP, cisplatin; DMS, dexamethasone; ETP, etoposide; G-CSF, granulocyte colony-stimulating factor; GEM, gemcitabine; IFM, ifosfamide; IM, intramuscular; IV, intravenous; L-asp, L-asparaginase; MTX, methotrexate; OXP, oxaliplatin; PEG-asp, pegaspargase; PO, orally; SC, subcutaneous; WBC, white blood cell.



**Fig. 2.** Examples of concurrent chemoradiotherapy for localized ENKL  
 CBDCA, carboplatin; CCRT, concurrent chemoradiation; CDDP, cisplatin; DMS, dexamethasone; ETP, etoposide; HD-AHSCT, high-dose chemotherapy with autologous hematopoietic stem cell transplantation; IFM, ifosfamide; L-asp, L-asparaginase; med., median; RT, radiotherapy; w, week.

Localized ENKL (n = 257)

Advanced ENKL (n = 101)



**Fig. 3.** First-line therapy among patients with ENKL diagnosed between 2000 and 2013 in 31 institutes in Japan<sup>7</sup>  
 chemo., chemotherapy; ENKL, extranodal NK/T-cell lymphoma, nasal type; CRT, concurrent chemoradiotherapy; L-asp, L-asparaginase; RT, radiotherapy.

ifosfamide, dexamethasone, L-asparaginase, and etoposide), which was designed to reduce early progression through the upfront use of L-asparaginase and a more intensive chemotherapeutic regimen; however, early progression was still documented.<sup>32</sup>

Among these four treatments, as well as other concurrent chemoradiotherapies,<sup>33,34</sup> RT-2/3DeVIC and CCRT-VIDL seemed to be best in terms of efficacy and acceptable toxicity, although it is difficult to determine the best treatment using randomized control trials. RT-2/3DeVIC is characterized by a short treatment duration (9 weeks) and the availability of long-term follow-up data, whereas CCRT-VIDL has the benefit of a lower dose of radiotherapy. Consolidative HD-AHSCT is not recommended when RT-(2/3) DeVIC is selected for first-line therapy, although upfront HD-AHSCT for patients who respond to initial therapy is generally feasible.<sup>35</sup>

### **Sequential chemoradiotherapy**

Sequential chemoradiotherapy combined with CHOP-like chemotherapy has limited efficacy for ENKL.<sup>3,4</sup> Several regimens with non-MDR-related agents and/or L-asparaginase have been developed.

A single-center phase II study of sandwiched chemoradiotherapy with LVP chemotherapy (L-asparaginase, vincristine, and prednisolone) in 26 patients with newly diagnosed localized ENKL reported that the ORR and CR rate were 89% and 81%, respectively.<sup>36</sup> Hematological toxicity was mild. The 5-year OS and PFS in 25 patients evaluated were both 64%.<sup>37</sup> A prospective observational study of sandwiched chemoradiotherapy with SMILE (steroid = dexamethasone, methotrexate, ifosfamide, L-asparaginase, and etoposide) chemotherapy (Table 2)<sup>38</sup> included 29 patients with newly diagnosed nasal ENKL.<sup>39</sup> The CR rate and ORR after 2 or 3 courses of SMILE were 69% and 86%, respectively. Hematological toxicity was manageable, although two treatment-related deaths were documented. The NCCN guidelines included sequential chemoradiotherapy using SMILE chemotherapy as an option for the first-line treatment of localized ENKL.

Several sequential chemoradiotherapies with gemcitabine-containing chemotherapies have been reported to exhibit lower toxicity and promising efficacy. A phase II study of sandwich chemoradiotherapy with GELOX (gemcitabine, L-asparaginase, oxaliplatin) in 27 patients reported a 5-year OS of 85% and a 5-year PFS of 74% with a median follow-up of 63 months (range, 31-83).<sup>40</sup>

### **Radiotherapy alone**

Early studies reported that radiotherapy alone yields a CR rate of > 65% and a 5-year OS rate of 40%.<sup>41</sup> Radiotherapy alone was believed to be insufficient to achieve a high cure rate for patients with localized ENKL; however, recent studies have reported more favorable therapeutic outcomes than before. For example, a large retrospective study conducted in China including 1,273 patients with localized ENKL reported that the 5-year OS and PFS rates of patients who

received radiotherapy alone were 70% and 65%, respectively. Progress in radiation planning and procedure during the last decade may be associated with the improved efficacy of radiotherapy alone.<sup>42,43</sup> The large retrospective study in China suggested that long-term remission after radiotherapy alone can be expected among patients having none of the following risk factors: age > 60 years, performance status (ECOG) > 1, stage II disease, serum LDH level > ULN, or primary tumor invasiveness (PTI: invasion to adjacent tissue/organs).<sup>8</sup> PTI was the strongest prognostic factor among them and was assessed by each participating institute in the study. Establishment of objective diagnostic criteria for PTI is awaited to identify patients who can be cured by radiotherapy alone.

## **CENTRAL NERVOUS SYSTEM (CNS) PROPHYLAXIS FOR LOCALIZED NASAL ENKL**

Some reports have recommended CNS prophylaxis during the front-line treatment of localized nasal ENKL. The largest retrospective study evaluating the significance of CNS prophylaxis in patients with ENKL, with 208 patients diagnosed between June 1995 and March 2008, reported that 12 patients (5.76%) experienced CNS relapse during the follow-up period and that NK-PI Group 3/4 was an independent risk factor for CNS relapse.<sup>44</sup> Based on a systematic review including this study, there is a Level C recommendation that patients with ENKL in NK-PI Group 3/4 should be regarded as having a high risk for CNS dissemination.<sup>45</sup> As most reports evaluating the risk of CNS relapse in ENKL included patients who were treated with anthracycline-containing chemotherapies, further studies are needed to confirm this recommendation. In terms of RT-DeVIC, CNS prophylaxis seems to be not mandatory because only one patient who had massive stage I disease experienced CNS relapse in the JCOG0211 study.<sup>29</sup>

## **TREATMENT FOR ADVANCED-STAGE OR RELAPSED/REFRACTORY ENKL**

The outcomes of newly diagnosed stage IV, relapsed or refractory ENKL treated with CHOP-like chemotherapy were extremely poor. For example, a retrospective study in Japan reported that the ORR achieved by conventional therapy was 36% for newly diagnosed stage IV ENKL and <10% for relapsed or refractory ENKL.<sup>46</sup> These outcomes have been improved by new non-MDR-related chemotherapeutic regimens with L-asparaginase such as SMILE<sup>38,47</sup> and AspaMetDex (L-asparaginase, methotrexate, and dexamethasone)<sup>48</sup> (Table 2).

A phase II study of SMILE chemotherapy for newly diagnosed relapsed/refractory ENKL evaluated in 38 patients reported that the ORR and CR rate after 2 cycles of SMILE were 79% and 45%, respectively, and the 5-year OS rate was 47%.<sup>49</sup> Myelosuppression was common and severe, causing more than half of the patients to experience Grade 3/4 infections. A multicenter phase II study of AspaMetDex<sup>50</sup> for

relapsed or refractory ENKL in 19 patients with a history of CHOP-like chemotherapy stopped early because of excellent efficacy. The CR rate and ORR were 61% and 78%, respectively, and the median OS was 12 months.<sup>48</sup> SMILE and AspaMetDex are recommended for the first-line treatment of advanced ENKL in the NCCN guidelines.<sup>18</sup> In the United States, pegaspargase is used instead of conventional *E. coli* L-asp and is administered as one dose per cycle.<sup>51</sup>

There are several reports concerning the toxicity of SMILE. A retrospective study in Singapore reported that one of 10 patients with ENKL who received SMILE died of septic shock.<sup>52</sup> A retrospective study in Korea evaluated SMILE chemotherapy for patients with newly diagnosed stage IV disease in clinical practice and reported frequent treatment-related death and disease progression during the regimen.<sup>53</sup> Another retrospective study in Korea noted that SMILE chemotherapy was rarely completed in patients with newly diagnosed advanced ENKL aged 60 years or more.<sup>54</sup> A modified regimen of SMILE administration of 3 weeks per cycle and seven doses of daily L-asp demonstrated severe toxicity.<sup>55</sup> As the half-life of L-asp is 1.2 days, L-asp in SMILE should not be given daily to reduce adverse drug reactions. On the other hand, the NKEA Part A reported that SMILE was manageable and that the common grade 3 or 4 non-hematologic adverse events observed during SMILE were not infection but abnormal liver tests.<sup>7</sup> In Japan, there is a consensus among hematologists that SMILE chemotherapy is not suitable for elderly or frail patients who do not fulfill the inclusion criteria of the SMILE phase II study.<sup>7</sup> Basically, SMILE is not selected for patients with a low lymphocyte count ( $< 500 /\mu\text{L}$ ).<sup>38</sup> Granulocyte colony-stimulating factor is started from day 6 of SMILE as per the protocol, irrespective of white blood cell count. This community consensus in Japan may have reduced the incidence of severe infection due to SMILE.

Gemcitabine-based chemotherapy is generally less toxic than L-asp-containing regimens. Several regimens have been explored by study groups in China. One of the regimens, P-gemox (gemcitabine, oxaliplatin and pegaspargase; Table 2), was originally designed as a two-week regimen and was modified to a three-week regimen.<sup>56</sup> A retrospective study of P-gemox in 117 patients with relapsed or refractory ENKL reported that the ORR was 89%. A retrospective study of GDP (gemcitabine, cisplatin, and dexamethasone; Table 2) in 41 patients with newly diagnosed stage IV and relapsed/refractory ENKL reported that the ORR and the 1-year PFS rate were 83% and 55%, respectively.<sup>57</sup> There is little information on the use of gemcitabine-based regimens for ENKL outside China, possibly because of the lower incidence of the disease and the limited use of oxaliplatin and pegaspargase for the treatment of ENKL in clinical practice. The promising therapeutic outcomes of gemcitabine-based chemotherapy need further evaluation.

## MANAGEMENT AFTER FIRST-LINE THERAPY

There is no consensus on the best consolidative therapy in patients with disseminated ENKL who responded to induction therapy. A retrospective study in Korea reported the limitations of a treatment approach of SMILE followed by HD-AHSCT.<sup>53</sup> Experts in Hong Kong recommended allogeneic HSCT based on experiences in practice.<sup>58</sup> Only HD-AHSCT is listed in the flow chart of the treatment of ENKL in the European Society of Medical Oncology Clinical Practice guidelines.<sup>26</sup> Based on the results of a retrospective analysis using data from the Japan Society for hematopoietic cell transplantation lymphoma working party<sup>59</sup>, the JSH guidelines recommend HD-AHSCT or allogeneic HSCT for patients in the first CR who are eligible for SCT and recommend HSCT as an option for patients who do not demonstrate CR (Fig. 1).<sup>25</sup>

The most established marker for disease monitoring in ENKL is the EBV-DNA load in the peripheral blood.<sup>19-21</sup> It is widely used in current clinical practice, although the test is not reimbursed by the health insurance system in some countries, including Japan. A predictive model combining the Deauville score of FDG-PET and EBV-DNA load after first-line next-generation therapy was proposed by the Asia Lymphoma Study Group.<sup>60</sup> The model stratified the following three groups of different treatment-failure probabilities: a low-risk group (post-treatment EBV negativity and post-treatment Deauville score of 1–2), a high-risk group (post-treatment EBV negativity with a Deauville score 3–4, or post-treatment EBV positivity with a Deauville score 1–2), and treatment failure (Deauville score of 5 or post-treatment EBV positivity with a Deauville of score 3–4). Frequency of treatment failure in the last group was 100% in the study.

A relapse of ENKL more than 10 years after the initial CR is rare. A retrospective study identified 10 patients with very late relapse ENKL. The patients were diagnosed between 1980 and 2009, and the time from initial diagnosis to relapse ranged from 11 to 29 years. Nine had nasal ENKL, and the sites of relapse were systemic in two patients and in the nasal area in 8 patients.<sup>61</sup> As no patient in the study received next-generation ENKL therapy, it is not known whether very late ENKL relapse could occur after treatment with the next-generation therapies.

## TREATMENT FOR EXTRANASAL ENKL

The prognosis of patients with extranasal ENKL treated with conventional approaches is suboptimal.<sup>5</sup> The skin and soft tissue are the second most common primary sites of involvement in ENKL. A retrospective study including 48 patients suggested survival benefits of radiotherapy among patients with localized cutaneous involvement alone.<sup>62</sup> The gastrointestinal tract is the third most common site of involvement in ENKL, and the large intestine is frequently involved.<sup>63,64</sup> Intestinal perforation can be a complication of chemotherapy. Treatment for extranasal ENKL is considered to be the same as that for nasal ENKL in the current

practice; however, it is unknown whether the next-generation treatments improve its clinical outcome. There are some reports regarding patients with extranasal ENKL who experienced a relapse in the nasal area, suggesting that nasal and non-nasal ENKL are different clinical forms of the same disease process.<sup>65,66</sup>

## NOVEL TREATMENT APPROACHES

To improve local control and reduce late toxicities due to radiotherapy for localized nasal ENKL, there has been an increased use of intensity-modulated radiotherapy or other modern radiotherapy.<sup>43</sup> Concurrent chemoradiotherapy with intra-arterial infusion of chemotherapy showed promising efficacy for localized nasal ENKL.<sup>67</sup>

Some new agents for other types of lymphomas or cancers have been tested in ENKL. A prospective observational study of pembrolizumab, an anti-PD-1 antibody, for relapsed or refractory ENKL after L-asp-containing chemotherapy reported very promising efficacy in seven patients. The ORR was 100%, and five achieved CR after the median seven courses of pembrolizumab (range, 2 - 13). Among them, two were EBER positive, and EBV-DNA was detectable in the peripheral blood of one patient after the treatment.<sup>68</sup> As ENKL cells frequently express PD-L1,<sup>69</sup> this approach will be more actively explored in the near future. Moreover, there have been several reported cases of ENKL that have demonstrated the promising efficacy of the anti-CD38 antibody daratumumab,<sup>70</sup> the anti-CD30 antibody-drug conjugate brentuximab vedotin,<sup>71,72</sup> lenalidomide,<sup>40</sup> and vorinostat.<sup>73</sup> Eleven patients with active ENKL received LMP-cytotoxic T lymphocytes as an adjuvant therapy, and three of them achieved long-term remission.<sup>74</sup>

Next-generation sequencing has revealed genes frequently mutated in patients with ENKL, including *BCOR*,<sup>75</sup> *DDX3X*,<sup>76</sup> *JAK3*, *STAT3*, and *STAT5B*. There are conflicting results regarding the frequency of *JAK3* mutations in ENKL.<sup>75</sup> A recent study identified a specific *JAK3* mutation in ENKL that can induce lymphomagenesis *in vitro*.<sup>77</sup> These findings warrant the development of new treatment approaches targeting components of the JAK-STAT pathway.

## FUTURE PERSPECTIVE

The OS of patients with localized ENKL has improved since the early 2000s.<sup>7</sup> Continuous supportive care for late toxicities, such as mucositis and dry mouth, or secondary malignancies, is needed for long-term survivors. The 1-year PFS has not improved, and approximately 20% of patients die or experience relapse in the first year after diagnosis. The 5-year OS (24%) and PFS (16%) in patients with advanced ENKL in the NKEA Part A remain dismal.<sup>7</sup> These outcomes clearly indicate the current limitations of the next-generation therapy for ENKL. More innovative, risk-stratified therapeutic approaches should be explored.

Evidence generated in East Asia has been referred to in the management of ENKL in Western countries. There are

considerable differences in the logistics of radiotherapy and the availability of new drugs among countries. The development of innovative treatment approaches could be advanced through international cooperation utilizing the advantages of each country.

## ACKNOWLEDGEMENTS

This work was supported by the Japan Society for the Promotion of Science Grant-in-Aid for Scientific Research (JSPS KAKENHI; Grant Number 26461418, 17K09924).

## AUTHOR CONTRIBUTIONS

Conception and design: Motoko Yamaguchi, Financial support: Motoko Yamaguchi, Manuscript writing: All authors, Final approval of manuscript: All authors

## CONFLICT OF INTEREST

Motoko Yamaguchi - Honoraria: Chugai Pharmaceutical, Eisai, Kyowa Hakko Kirin, Bristol-Myers Squibb, Takeda Pharmaceuticals, Nippon Shinyaku; Kana Miyazaki - Honoraria: Chugai Pharmaceutical, Takeda Pharmaceuticals, Eisai

## REFERENCES

- 1 Swerdlow SH, Campo E, Harris NL, *et al.*: WHO classification of tumours of haematopoietic and lymphoid tissues. Lyon, IARC, 2008
- 2 Yamaguchi M: Current and future management of NK/T-cell lymphoma based on clinical trials. *Int J Hematol* 96:562-571, 2012
- 3 Oshimi K: Progress in understanding and managing natural killer-cell malignancies. *Br J Haematol* 139:532-544, 2007
- 4 Liang R: Advances in the management and monitoring of extranodal NK/T-cell lymphoma, nasal type. *Br J Haematol* 147:13-21, 2009
- 5 Au WY, Weisenburger DD, Intragumtornchai T, *et al.*: Clinical differences between nasal and extranasal natural killer/T-cell lymphoma: a study of 136 cases from the International Peripheral T-Cell Lymphoma Project. *Blood* 113:3931-3937, 2009
- 6 Kim SJ, Yoon DH, Jaccard A, *et al.*: A prognostic index for natural killer cell lymphoma after non-anthracycline-based treatment: a multicentre, retrospective analysis. *Lancet Oncol* 17:389-400, 2016
- 7 Yamaguchi M, Suzuki R, Oguchi M, *et al.*: Treatments and outcomes of patients with extranodal natural killer/T-cell lymphoma diagnosed between 2000 and 2013: A cooperative study in Japan. *J Clin Oncol* 35:32-39, 2017
- 8 Yang Y, Zhu Y, Cao JZ, *et al.*: Risk-adapted therapy for early-stage extranodal nasal-type NK/T-cell lymphoma: analysis from a multicenter study. *Blood* 126:1424-1432, 2015
- 9 Karkera A, Parsons B, Borgert A, *et al.*: NK/T cell lymphoma in the U.S: a population-based study using the National Cancer



- Database from 1998-2012. *J Clin Oncol* 34:suppl; abstr e19038, 2016
- 10 Swerdlow SH, Campo E, Pileri SA, *et al.*: The 2016 revision of the World Health Organization classification of lymphoid neoplasms. *Blood* 127:2375-2390, 2016
  - 11 Takeuchi K, Yokoyama M, Ishizawa S, *et al.*: Lymphomatoid gastropathy: a distinct clinicopathologic entity of self-limited pseudomalignant NK-cell proliferation. *Blood* 116:5631-5637, 2010
  - 12 Mansoor A, Pittaluga S, Beck PL, *et al.*: NK-cell enteropathy: a benign NK-cell lymphoproliferative disease mimicking intestinal lymphoma: clinicopathologic features and follow-up in a unique case series. *Blood* 117:1447-1452, 2011
  - 13 Fujiwara H, Maeda Y, Nawa Y, *et al.*: The utility of positron emission tomography/computed tomography in the staging of extranodal natural killer/T-cell lymphoma. *Eur J Haematol* 87:123-129, 2011
  - 14 Moon SH, Cho SK, Kim WS, *et al.*: The role of 18F-FDG PET/CT for initial staging of nasal type natural killer/T-cell lymphoma: a comparison with conventional staging methods. *J Nucl Med* 54:1039-1044, 2013
  - 15 Chim CS, Ma SY, Au WY, *et al.*: Primary nasal natural killer cell lymphoma: long-term treatment outcome and relationship with the International Prognostic Index. *Blood* 103:216-221, 2004
  - 16 Lee J, Suh C, Park YH, *et al.*: Extranodal natural killer T-cell lymphoma, nasal-type: a prognostic model from a retrospective multicenter study. *J Clin Oncol* 24:612-618, 2006
  - 17 Yamaguchi M, Takata K, Yoshino T, *et al.*: Prognostic biomarkers in patients with localized natural killer/T-cell lymphoma treated with concurrent chemoradiotherapy. *Cancer Sci* 105:1435-1441, 2014
  - 18 NCCN Guidelines T-Cell Lymphomas Version 1.2017. [https://www.nccn.org/professionals/physician\\_gls/f\\_guidelines.asp](https://www.nccn.org/professionals/physician_gls/f_guidelines.asp) (Access date: December 19, 2016)
  - 19 Suzuki R, Yamaguchi M, Izutsu K, *et al.*: Prospective measurement of Epstein-Barr virus-DNA in plasma and peripheral blood mononuclear cells of extranodal NK/T-cell lymphoma, nasal type. *Blood* 118:6018-6022, 2011
  - 20 Ito Y, Kimura H, Maeda Y, *et al.*: Pretreatment EBV-DNA copy number is predictive of response and toxicities to SMILE chemotherapy for extranodal NK/T-cell lymphoma, nasal type. *Clin Cancer Res* 18:4183-4190, 2012
  - 21 Kwong YL, Pang AW, Leung AY, *et al.*: Quantification of circulating Epstein-Barr virus DNA in NK/T-cell lymphoma treated with the SMILE protocol: diagnostic and prognostic significance. *Leukemia* 28:865-870, 2014
  - 22 Yamaguchi M, Kita K, Miwa H, *et al.*: Frequent expression of P-glycoprotein/MDR1 by nasal T-cell lymphoma cells. *Cancer* 76:2351-2356, 1995
  - 23 Drenou B, Lamy T, Amiot L, *et al.*: CD3- CD56+ non-Hodgkin's lymphomas with an aggressive behavior related to multidrug resistance. *Blood* 89:2966-2974, 1997
  - 24 Egashira M, Kawamata N, Sugimoto K, *et al.*: P-glycoprotein expression on normal and abnormally expanded natural killer cells and inhibition of P-glycoprotein function by cyclosporin A and its analogue, PSC833. *Blood* 93:599-606, 1999
  - 25 The Japanese Society of Hematology, eds. The 2013 JSH guidelines for the management of hematologic malignancies. Tokyo, Kanehara, 2013
  - 26 d'Amore F, Gaulard P, Trumper L, *et al.*: Peripheral T-cell lymphomas: ESMO Clinical Practice Guidelines for diagnosis, treatment and follow-up. *Ann Oncol* 26 Suppl 5:v108-115, 2015
  - 27 Yamaguchi M, Ogawa S, Nomoto Y, *et al.*: Treatment outcome of nasal NK-cell lymphoma: A report of 12 consecutively-diagnosed cases and a review of the literature. *J Clin Exp Hematop* 41:93-99, 2001
  - 28 Yamaguchi M, Tobinai K, Oguchi M, *et al.*: Phase I/II study of concurrent chemoradiotherapy for localized nasal natural killer/T-cell lymphoma: Japan Clinical Oncology Group Study JCOG0211. *J Clin Oncol* 27:5594-5600, 2009
  - 29 Yamaguchi M, Tobinai K, Oguchi M, *et al.*: Concurrent chemoradiotherapy for localized nasal natural killer/T-cell lymphoma: an updated analysis of the Japan clinical oncology group study JCOG0211. *J Clin Oncol* 30:4044-4046, 2012
  - 30 Kim SJ, Kim K, Kim BS, *et al.*: Phase II trial of concurrent radiation and weekly cisplatin followed by VIPD chemotherapy in newly diagnosed, stage IE to IIE, nasal, extranodal NK/T-Cell Lymphoma: Consortium for Improving Survival of Lymphoma study. *J Clin Oncol* 27:6027-6032, 2009
  - 31 Kim SJ, Yang DH, Kim JS, *et al.*: Concurrent chemoradiotherapy followed by L-asparaginase-containing chemotherapy, VIDL, for localized nasal extranodal NK/T cell lymphoma: CISL08-01 phase II study. *Ann Hematol* 93:1895-1901, 2014
  - 32 Oh D, Ahn YC, Kim SJ, *et al.*: Concurrent chemoradiation therapy followed by consolidation chemotherapy for localized extranodal natural killer/T-cell lymphoma, nasal type. *Int J Radiat Oncol Biol Phys* 93:677-683, 2015
  - 33 Tsai HJ, Lin SF, Chen CC, *et al.*: Long-term results of a phase II trial with frontline concurrent chemoradiotherapy followed by consolidation chemotherapy for localized nasal natural killer/T-cell lymphoma. *Eur J Haematol* 94:130-137, 2015
  - 34 Michot JM, Mazon R, Danu A, *et al.*: Concurrent Etoposide, Steroid, High-dose Ara-C and Platinum chemotherapy with radiation therapy in localised extranodal natural killer (NK)/T-cell lymphoma, nasal type. *Eur J Cancer* 51:2386-2395, 2015
  - 35 Yhim HY, Kim JS, Mun YC, *et al.*: Clinical Outcomes and Prognostic Factors of Up-Front Autologous Stem Cell Transplantation in Patients with Extranodal Natural Killer/T Cell Lymphoma. *Biol Blood Marrow Transplant* 21:1597-1604, 2015
  - 36 Jiang M, Zhang H, Jiang Y, *et al.*: Phase 2 trial of "sandwich" L-asparaginase, vincristine, and prednisone chemotherapy with radiotherapy in newly diagnosed, stage IE to IIE, nasal type, extranodal natural killer/T-cell lymphoma. *Cancer* 118:3294-3301, 2012
  - 37 Zhang L, Jiang M, Xie L, *et al.*: Five-year analysis from phase 2 trial of "sandwich" chemoradiotherapy in newly diagnosed, stage IE to IIE, nasal type, extranodal natural killer/T-cell lymphoma. *Cancer Med* 5:33-40, 2016
  - 38 Yamaguchi M, Kwong YL, Kim WS, *et al.*: Phase II study of SMILE chemotherapy for newly diagnosed stage IV, relapsed, or refractory extranodal natural killer (NK)/T-cell lymphoma, nasal type: the NK-Cell Tumor Study Group study. *J Clin Oncol*

- 29:4410-4416, 2011
- 39 Kwong YL, Kim WS, Lim ST, *et al.*: SMILE for natural killer/T-cell lymphoma: analysis of safety and efficacy from the Asia Lymphoma Study Group. *Blood* 120:2973-2980, 2012
  - 40 Wang L, Wang ZH, Chen XQ, *et al.*: First-line combination of GELOX followed by radiation therapy for patients with stage IE/IIe ENKTL: An updated analysis with long-term follow-up. *Oncol Lett* 10:1036-1040, 2015
  - 41 Kim GE, Cho JH, Yang WI, *et al.*: Angiocentric lymphoma of the head and neck: patterns of systemic failure after radiation treatment. *J Clin Oncol* 18:54-63, 2000
  - 42 Wang H, Li YX, Wang WH, *et al.*: Mild toxicity and favorable prognosis of high-dose and extended involved-field intensity-modulated radiotherapy for patients with early-stage nasal NK/T-cell lymphoma. *Int J Radiat Oncol Biol Phys* 82:1115-1121, 2012
  - 43 Oguchi M, Yamaguchi M, Suzuki R, *et al.*: The multi-institutional retrospective study of radiation therapy for NK/T-cell lymphoma in Japan. *Radiat Oncol* 119:S309, 2016
  - 44 Kim SJ, Oh SY, Hong JY, *et al.*: When do we need central nervous system prophylaxis in patients with extranodal NK/T-cell lymphoma, nasal type? *Ann Oncol* 21:1058-1063, 2010
  - 45 Ferreri AJ: Risk of CNS dissemination in extranodal lymphomas. *Lancet Oncol* 15:e159-169, 2014
  - 46 Suzuki R, Suzumiya J, Yamaguchi M, *et al.*: Prognostic factors for mature natural killer (NK) cell neoplasms: aggressive NK cell leukemia and extranodal NK cell lymphoma, nasal type. *Ann Oncol* 21:1032-1040, 2010
  - 47 Yamaguchi M, Suzuki R, Kwong YL, *et al.*: Phase I study of dexamethasone, methotrexate, ifosfamide, L-asparaginase, and etoposide (SMILE) chemotherapy for advanced-stage, relapsed or refractory extranodal natural killer (NK)/T-cell lymphoma and leukemia. *Cancer Sci* 99:1016-1020, 2008
  - 48 Jaccard A, Gachard N, Marin B, *et al.*: Efficacy of L-asparaginase with methotrexate and dexamethasone (AspaMetDex regimen) in patients with refractory or relapsing extranodal NK/T-cell lymphoma, a phase 2 study. *Blood* 117:1834-1839, 2011
  - 49 Suzuki R, Kwong Y, Maeda Y, *et al.*: 5-year follow-up of the SMILE phase II study for newly-diagnosed stage IV, relapsed or refractory extranodal NK/T-cell lymphoma, nasal type. *Hematol Oncol* 33(Suppl S1):140, 2015
  - 50 Jaccard A, Petit B, Girault S, *et al.*: L-asparaginase-based treatment of 15 western patients with extranodal NK/T-cell lymphoma and leukemia and a review of the literature. *Ann Oncol* 20:110-116, 2009
  - 51 Qi S, Yahalom J, Hsu M, *et al.*: Encouraging experience in the treatment of nasal type extra-nodal NK/T-cell lymphoma in a non-Asian population. *Leuk Lymphoma* 57:2575-2583, 2016
  - 52 Chan A, Tang T, Ng T, *et al.*: To SMILE or not: supportive care matters. *J Clin Oncol* 30:1015-1016; author reply 1016-1017, 2012
  - 53 Kim SJ, Park S, Kang ES, *et al.*: Induction treatment with SMILE and consolidation with autologous stem cell transplantation for newly diagnosed stage IV extranodal natural killer/T-cell lymphoma patients. *Ann Hematol* 94:71-78, 2015
  - 54 Kim SM, Park S, Oh DR, *et al.*: Extra-nodal natural killer/T cell lymphoma in elderly patients: the impact of aging on clinical outcomes and treatment tolerability. *Ann Hematol* 95:581-591, 2016
  - 55 Li X, Cui Y, Sun Z, *et al.*: DDGP versus SMILE in newly diagnosed advanced natural killer/T-cell lymphoma: A randomized controlled, multicenter, open-label study in China. *Clin Cancer Res* 22:5223-5228, 2016
  - 56 Wang JH, Wang H, Wang YJ, *et al.*: Analysis of the efficacy and safety of a combined gemcitabine, oxaliplatin and pegaspargase regimen for NK/T-cell lymphoma. *Oncotarget* 7:35412-35422, 2016
  - 57 Wang JJ, Dong M, He XH, *et al.*: GDP (Gemcitabine, Dexamethasone, and Cisplatin) is highly effective and well-tolerated for newly diagnosed stage IV and relapsed/refractory extranodal natural killer/T-cell lymphoma, nasal type. *Medicine (Baltimore)* 95:e2787, 2016
  - 58 Tse E, Kwong YL: How I treat NK/T-cell lymphomas. *Blood* 121:4997-5005, 2013
  - 59 Suzuki R, Kako S, Hyo R, *et al.*: Hematopoietic stem cell transplantation for extranodal NK/T-cell lymphoma, nasal type: the Japan Society for Hematopoietic Cell Transplantation (JSHCT) lymphoma working party. *Ann Oncol* 22(Suppl S1):iv95, 2011
  - 60 Kim SJ, Choi JY, Hyun SH, *et al.*: Risk stratification on the basis of Deauville score on PET-CT and the presence of Epstein-Barr virus DNA after completion of primary treatment for extranodal natural killer/T-cell lymphoma, nasal type: a multicentre, retrospective analysis. *Lancet Haematol* 2:e66-74, 2015
  - 61 Au WY, Kim SJ, Yiu HH, *et al.*: Clinicopathological features and outcome of late relapses of natural killer cell lymphomas 10-29 years after initial remission. *Am J Hematol* 85:362-363, 2010
  - 62 Ahn HK, Suh C, Chuang SS, *et al.*: Extranodal natural killer/T-cell lymphoma from skin or soft tissue: suggestion of treatment from multinational retrospective analysis. *Ann Oncol* 23:2703-2707, 2012
  - 63 Ko YH, Cho EY, Kim JE, *et al.*: NK and NK-like T-cell lymphoma in extranasal sites: a comparative clinicopathological study according to site and EBV status. *Histopathology* 44:480-489, 2004
  - 64 Zheng S, Ouyang Q, Li G, *et al.*: Primary intestinal NK/T cell lymphoma: a clinicopathologic study of 25 Chinese cases. *Arch Iran Med* 15:36-42, 2012
  - 65 Tse E, Leung R, Khong PL, *et al.*: Non-nasal natural killer cell lymphoma: not non-nasal after all. *Ann Hematol* 88:185-187, 2009
  - 66 Sakaguchi H, Miyazaki K, Tono Y, *et al.*: [Relapse in the nasal cavity of a patient with extranodal NK/T-cell lymphoma initially presenting as plantar subcutaneous tumor]. *Rinsho Ketsueki* 56:1076-1081, 2015
  - 67 Takahara M, Nagato T, Kishibe K, *et al.*: Novel treatment for early-stage nasal natural killer/T-cell lymphoma: intra-maxillary arterial infusion chemotherapy with concomitant radiotherapy. *Hematol Oncol*, 2015
  - 68 Kwong YL, Chan TS, Tan D, *et al.*: PD1 blockade with pembrolizumab is highly effective in relapsed or refractory NK/T-cell lymphoma failing L-asparaginase. *Blood*, 2017
  - 69 Wang H, Wang L, Liu WJ, *et al.*: High post-treatment serum

- levels of soluble programmed cell death ligand 1 predict early relapse and poor prognosis in extranodal NK/T cell lymphoma patients. *Oncotarget* 7:33035-33045, 2016
- 70 Hari P, Raj RV, Olteanu H: Targeting CD38 in refractory extranodal natural killer cell-T-cell lymphoma. *N Engl J Med* 375:1501-1502, 2016
- 71 Kim HK, Moon SM, Moon JH, *et al.*: Complete remission in CD30-positive refractory extranodal NK/T-cell lymphoma with brentuximab vedotin. *Blood Res* 50:254-256, 2015
- 72 Poon LM, Kwong YL: Complete remission of refractory disseminated NK/T cell lymphoma with brentuximab vedotin and bendamustine. *Ann Hematol* 95:847-849, 2016
- 73 McEachron TA, Kirov I, Wungwattana M, *et al.*: Successful treatment of genetically profiled pediatric extranodal NK/T-cell lymphoma targeting oncogenic STAT3 mutation. *Pediatr Blood Cancer* 63:727-730, 2016
- 74 Bollard CM, Gottschalk S, Torrano V, *et al.*: Sustained complete responses in patients with lymphoma receiving autologous cytotoxic T lymphocytes targeting Epstein-Barr virus latent membrane proteins. *J Clin Oncol* 32:798-808, 2014
- 75 Dobashi A, Tsuyama N, Asaka R, *et al.*: Frequent BCOR aberrations in extranodal NK/T-Cell lymphoma, nasal type. *Genes Chromosomes Cancer* 55:460-471, 2016
- 76 Jiang L, Gu ZH, Yan ZX, *et al.*: Exome sequencing identifies somatic mutations of DDX3X in natural killer/T-cell lymphoma. *Nat Genet* 47:1061-1066, 2015
- 77 Sim SH, Kim S, Kim TM, *et al.*: Novel JAK3-activating mutations in extranodal NK/T-cell lymphoma, nasal type. *Am J Pathol* 187:980-986, 2017