

Letter to the editor

## Hyaline vascular Castleman's disease representing 18 trisomy

**Keywords:** Castleman's disease, Hyaline vascular type, 18 trisomy, nodal marginal zone B-cell lymphoma

### TO THE EDITOR

We herein report a case of Castleman's disease (CD) hyaline vascular (HV) type representing 18 trisomy.

A 69-year-old Japanese male was admitted with a history of right cervical lymphadenopathy lasting for several months. CT demonstrated right cervical and bilateral hilar lymphadenopathy. The results of the full blood count with differential analysis were normal. The biochemical profile, including serum lactate dehydrogenase and interleukin-2 receptor serum levels, was normal. An excisional biopsy was performed. After the lymph node biopsy, he received rituximab therapy.

The biopsied specimen was 2.0 cm in diameter. In the low-power field, the lymphoid sinuses were absent (Fig. 1). Numerous lymphoid follicles were present throughout the cortex and medulla (Fig. 1). In the medium-power field, small atrophic germinal centers were surrounded by a broad mantle zone composed of concentric rings (Fig. 2a). Moreover, some of the lymphoid follicles contained more than one atrophic germinal center (Fig. 2a). Only a few germinal centers were penetrated by a sclerotic blood vessel (Fig. 2a). In the high-power field in small germinal centers, germinal center lymphocytes decreased in number and some of the follicular dendritic cells (FDCs) exhibited nuclear pleomorphism (Fig. 2b). In the interfollicular area, there were numerous high endothelial vessels with plump endothelial cells and sclerotic walls (Fig. 2a); small foci of plasmacytoid dendritic cells were also present (Fig. 2c). CD21 immunostaining demonstrated FDC networks with tight/concentric and expanded/disrupted patterns (Fig. 2d) in some of the lymphoid follicles.

Flow cytometry data from the biopsied specimen revealed a polyclonal B-cell population. However, conventional G-banded karyotype analysis demonstrated 46, X,-Y, +18, i(18)(q10) in 8 of the 20 cells examined (Fig. 3). A clonal band was observed by Southern blot analysis of the immunoglobulin heavy (IgH) chain gene (data not shown).

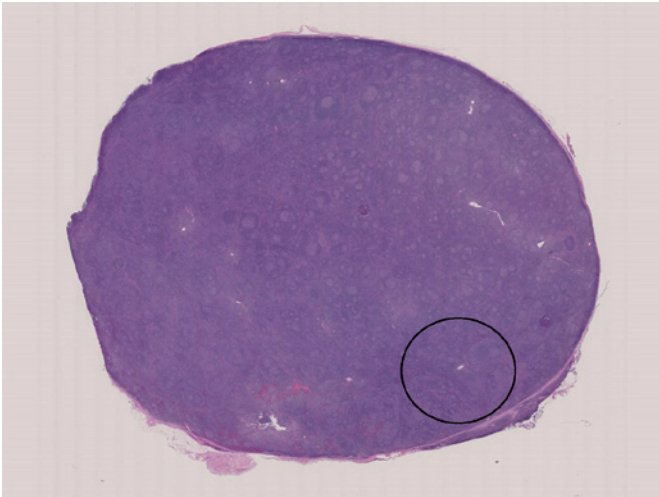
The immunohistochemical studies were re-examined. In a portion of the lymph node, (Fig. 1, ring), aggregates of small lymphocytes (Fig. 4a) were positive for CD20 (Fig. 4b), CD43 (Fig. 4c), and bcl-2, but negative for CD3, CD5 (Fig. 4d), CD10, bcl-6, and CyclinD1.

In 1956, Castleman *et al.* described an entity involving localized mediastinal lymph node hyperplasia resembling thymoma.<sup>1</sup> Since this original description, CD has been extended to include two entities: the classic HV type and a rare plasma cell (PC) type.<sup>2</sup> The present case had

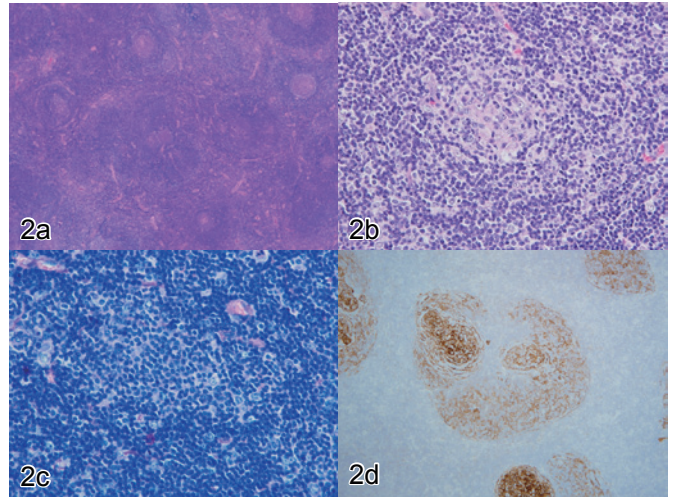
characteristic histomorphological and immunohistochemical findings of HV type CD: (i) absence of lymphoid sinuses in the lesion, (ii) presence of abnormal lymphoid follicles, (iii) nuclear pleomorphism of FDCs, (iv) interfollicular vascularity, (v) presence of plasmacytoid dendritic cell clusters, and (vi) abnormal proliferation of FDCs.<sup>2-5</sup> However, karyotype analysis demonstrated +18, which is one of the common clonal cytogenetic abnormalities of nodal marginal zone B-cell lymphoma (NMZBL).<sup>6</sup> Southern blot analysis of the immunoglobulin heavy (IgH) chain gene also revealed a clonal band. CD20+ CD43+ aggregates in small lymphocytes in a portion of the lymph node were observed on immunohistochemical studies. Aberrant CD43+ expression by B cells suggested NMZBL.<sup>6</sup> The etiology of HV CD remains unknown. Some authors have suggested that HV CD may be a FDC tumor.<sup>7</sup> Indeed, clonal cytogenetic abnormalities in the FDCs in HV CD have been reported.<sup>8,9</sup> Furthermore, HV CD and FDC sarcomas were found to be associated.<sup>7,10</sup> However, the cytogenetic, molecular, and immunohistochemical findings indicate that this case may have been early stage NMZBL.<sup>6</sup> Several malignant B-cell lymphomas have HV-CD-like morphology, including follicular lymphoma, mantle cell lymphoma, NMZBL, and diffuse large cell lymphoma.<sup>11</sup> This case suggests that NMZBL may exhibit the same histomorphological findings as HV CD.

### CONFLICT OF INTEREST

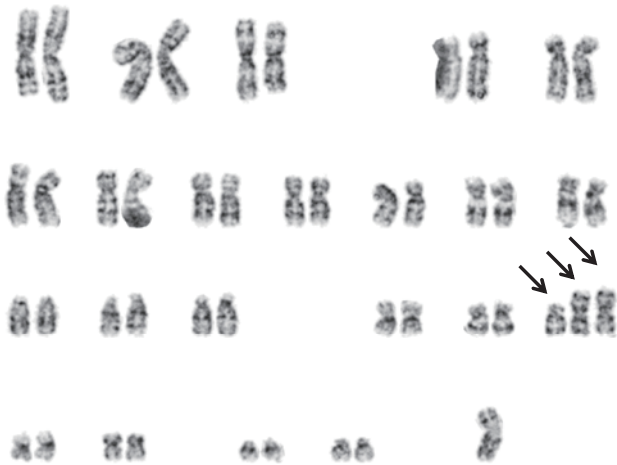
The authors declare no conflict of interest regarding this study.



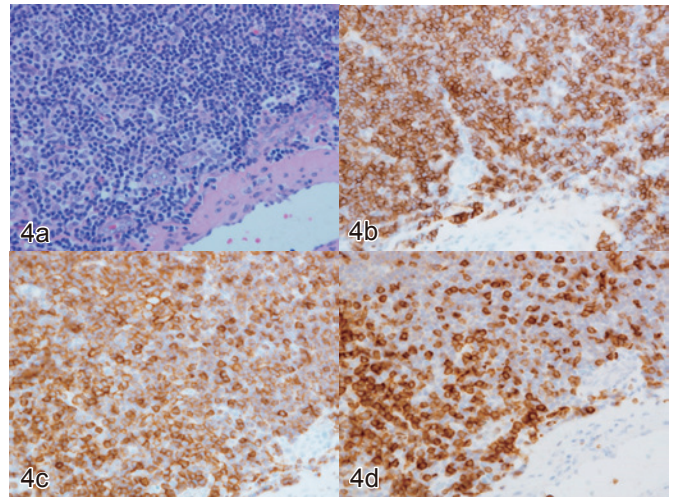
**Fig. 1.** Numerous lymphoid follicles were seen throughout the cortex and medulla. Note the absence of lymphoid sinuses. The ring indicates aggregates of CD43-positive small lymphocytes. HE



**Fig. 2.** *a.* In the medium-power field, small atrophic germinal centers were surrounded by a broad mantle zone composed of concentric rings. Note that the lymphoid follicle contained two atrophic germinal centers. The germinal center was penetrated by a sclerotic blood vessel. Numerous high endothelial vessels exhibited plump endothelial cells and sclerotic walls in the interfollicular area. HE  
*b.* In the high power field, note the decrease in germinal center cells and nuclear pleomorphism of FDCs. HE  
*c.* Note the foci of plasmacytoid dendritic cells in the interfollicular area. Giemsa  
*d.* CD21 immunostaining demonstrated the proliferation of FDCs (expanded/disrupted pattern).



**Fig. 3.** G-banded karyotype analysis demonstrated +18 (arrows).



**Fig. 4.** *a.* In a portion of the lymph node, aggregates of small lymphocytes without cytological atypia were observed. They were positive for CD20 (*b*) and CD43 (*c*) but negative for CD5 (*d*).

## REFERENCES

- 1 Castleman B, Iveerson L, Menendez VP. Localized mediastinal lymph node hyperplasia resembling lymphoma. *Cancer*. 1956; 9 : 822-830.
- 2 Keller AR, Hochholzer L, Castleman B. Hyaline-vascular and plasma-cell types of giant lymph node hyperplasia of the mediastinum and other locations. *Cancer*. 1972; 29 : 670-683.
- 3 Cronin DMP, Warnke RA. Castleman disease. An update on classification and the spectrum of associated lesions. *Adv Anat Pathol*. 2009; 16 : 236-246.
- 4 Ioachim HL, Medeiros LJ. Ioachim's Lymph Node Pathology. 4th ed, Philadelphia, Lippincott Williams & Wilkins. 2009; pp. 227-237.
- 5 Nguyen DT, Diamond LW, Hansmann ML, *et al*. Castleman's disease. Differences in follicular dendritic network in the hyaline vascular and plasma cell variants. *Histopathology*. 1994; 24 : 437-441.
- 6 Campo E, Pileri SA, Jaffe ES, *et al*. Nodal marginal zone B-cell lymphoma. In Swerdlow SH, Campo E, Harris NL, *et al*. WHO Classification of Tumours of Haematopoietic and Lymphoid Tissues. Revised 4th ed, Lyon, IARC Press. 2017; pp. 262-265.
- 7 O'Malley DP and Grimm KE. Atypical lymphoproliferative disorders. In Orazi A, Weiss LM, Foucar K, *et al*. Knowles's Neoplastic Hematopathology. 3rd ed, Philadelphia, Lippincott Williams & Wilkins. 2014; pp. 340-353.
- 8 Chen WC, Jones D, Ho CL, *et al*. Cytogenetic abnormalities in hyaline vascular Castleman disease: report of two cases with reappraisal of histogenesis. *Cancer Genet Cytogenet*. 2006; 164 : 110-117.
- 9 Chang KC, Wang YC, Hung LY, *et al*. Monoclonality and cytogenetic abnormalities in hyaline-vascular Castleman disease. *Mod Pathol*. 2014; 27 : 823-831.
- 10 Chan JK, Tsang WY, Ng CS. Follicular dendritic cell tumor and vascular neoplasm complicating hyaline vascular Castleman's disease. *Am J Surg Pathol*. 1994; 18 : 517-525.
- 11 Siddiqi IN, Brynes RK, Wang E. B-cell lymphoma with hyaline-vascular Castleman disease-like features: A clinicopathologic study. *Am J Clin Pathol*. 2011; 135 : 901-914.

**Masaru Kojima, M.D., Ph.D.,<sup>1)</sup>**  
**Seiichi Shimizu, M.D., Ph.D.<sup>2)</sup>**

<sup>1)</sup>Department of Diagnostic Pathology, Dokkyo Medical University School of Medicine, Mibu, Japan, <sup>2)</sup>Division of Hematological Oncology, Tsuchiura Kyodo Hospital, Tsuchiura, Japan.

**Corresponding author:** Masaru Kojima, M.D.,  
 Department of Diagnostic Pathology, Dokkyo Medical University School of Medicine, Mibu, Tochigi 321-0293,  
 Japan.

E-mail: [k-masaru@dokkyomed.ac.jp](mailto:k-masaru@dokkyomed.ac.jp)

Received: October 10, 2017.

Revised: October 27, 2017.

Accepted: November 6, 2017.

J-STAGE Advance Published: February 8, 2018

DOI:10.3960/jslrt.17034

Copyright © 2018 The Japanese Society for Lymphoreticular Tissue Research