

Original Article

# The clinical impact of human T-lymphotropic virus type 1 (HTLV-1) infection on the development of adult T-cell leukemia-lymphoma (ATL) or HTLV-1-associated myelopathy (HAM) / atypical HAM after allogeneic hematopoietic stem cell transplantation (allo-HSCT) and renal transplantation

Noriaki Kawano,<sup>1)</sup> Shuro Yoshida,<sup>1)</sup> Sayaka Kawano,<sup>1)</sup> Takuro Kuriyama,<sup>1)</sup> Yoshihiro Tahara,<sup>1)</sup> Atsushi Toyofuku,<sup>2)</sup> Tatsuya Manabe,<sup>2)</sup> Atsushi Doi,<sup>2)</sup> Soushi Terasaka,<sup>2)</sup> Kiyoshi Yamashita,<sup>1)</sup> Yuji Ueda,<sup>2)</sup> Hidenobu Ochiai,<sup>3)</sup> Kousuke Marutsuka,<sup>4)</sup> Yoshihisa Yamano,<sup>5)</sup> Kazuya Shimoda,<sup>6)</sup> Ikuo Kikuchi<sup>1)</sup>

Because there are limited clinical reports on the impact of human T-lymphotropic virus type 1 (HTLV-1) on organ transplantation, its effects on the development of adult T-cell leukemia-lymphoma (ATL), post-transplantation lymphoproliferative disorder (PTLD) and HTLV-1-associated myelopathy (HAM) or atypical HAM after organ transplantation remain unclear.

We retrospectively analyzed the impact of HTLV-1 in 54 allogeneic hematopoietic stem cell transplantation (allo-HSCT) cases and 31 renal transplantation cases between January 2006 and December 2016.

Among the 54 allo-HSCT cases, nine recipients with ATL tested positive for HTLV-1, and one was found to be an HTLV-1 carrier. All donors tested negative for HTLV-1. Only one HTLV-1 carrier did not present with ATL or HAM development after allo-HSCT. Among nine ATL cases after allo-HSCT, four eventually relapsed due to proliferation of recipient-derived ATL cells. However, in one ATL case, atypical HAM developed rapidly at 5 months after allo-HSCT.

Among the 31 renal transplantation cases, all donors tested negative for HTLV-1, and only recipients tested positive. Only one HTLV-1 carrier recipient did not present with ATL or HAM development after renal transplantation. However, one HTLV-1-negative recipient developed PTLD in the brain 10 years after renal transplantation.

In clinical practice, careful follow-up of HTLV-1 infected recipients after organ transplantation is important because atypical HAM can develop in ATL patients after allo-HSCT. Furthermore, to clarify the risk of ATL or HAM development in HTLV-1 infected recipients, we prospectively followed up our cohort.

**Keywords:** HTLV-1, ATL, atypical HAM, PTLD, organ transplantation

## INTRODUCTION

HTLV-1 infection is rare, serious, and life-threatening, and leads to the development of adult T-cell leukemia-lymphoma (ATL) or HTLV-1-associated myelopathy (HAM) in

patients undergoing immunosuppressive treatment after bone marrow transplantation (BMT) and organ transplantation because of HTLV-1 reactivation in recipient or donor cells.<sup>1</sup>


Regarding the ATL development mechanism, the major pathogenesis is proviral genome mutations, such as HTLV-1

Received: April 4, 2018. Revised: June 12, 2018. Accepted: June 19, 2018. J-STAGE Advance Published: August 8, 2018  
DOI:10.3960/jslrt.18011

<sup>1)</sup>Department of Internal Medicine, Miyazaki Prefectural Miyazaki Hospital, Miyazaki, Japan, <sup>2)</sup>Department of Surgery, Miyazaki Prefectural Miyazaki Hospital, Miyazaki, Japan, <sup>3)</sup>Trauma and Critical Care Center, Faculty of Medicine, University of Miyazaki, Miyazaki, Japan, <sup>4)</sup>Department of Pathology, Miyazaki Prefectural Miyazaki Hospital, Miyazaki, Japan, <sup>5)</sup>Department of Rare Diseases Research, Institute of Medical Science, St. Marianna University Graduate School of Medicine, Kawasaki, Japan, <sup>6)</sup>Division of Gastroenterology and Hematology, Department of Internal Medicine, Faculty of Medicine, University of Miyazaki, Miyazaki, Japan

**Corresponding author:** Dr. Noriaki Kawano, Department of Internal Medicine, Miyazaki Prefectural Miyazaki Hospital, 5-30 Kitatakamatsu, Miyazaki 880-8510, Japan.  
E-mail: kawanoriaki@yahoo.co.jp

Copyright © 2018 The Japanese Society for Lymphoreticular Tissue Research

 This work is licensed under a Creative Commons Attribution-NonCommercial-ShareAlike 4.0 International License.

tax or HTLV-1 bZIP factor (HBZ), and host gene mutations such as the activation of TCR/NF- $\kappa$ B signaling.<sup>2,3</sup>

As for the mechanism of HAM development, the major pathogenesis is chronic myelitis because of inflammation caused by CD4<sup>+</sup> CXCR3<sup>+</sup> CCR4<sup>+</sup> cells, and the production of Th1 cytokines such as CXCL10 and neopterin.<sup>4,5</sup>

ATL development after allogeneic hematopoietic stem cell transplantation (allo-HSCT) and organ transplantation has been reported in three and 13 cases, respectively.<sup>6-20</sup> Similarly, the development of HAM-mimicking myelitis after allo-HSCT and HAM after organ transplantation has been reported in one and 13 cases, respectively.<sup>21-33</sup> On the other hand, the clinical impact of HTLV-1 infection after allo-HSCT and organ transplantation is unclear and controversial.

Previously, we reported three cases of acute-type ATL development that originated from a recipient in eight HTLV-1 carriers among 164 living-donor liver transplant recipients undergoing immunosuppressive treatment.<sup>13</sup> In this study, we retrospectively analyzed the clinical impact of HTLV-1 on organ transplantation in 54 allo-HSCT cases and 31 renal transplantation cases.

## PATIENTS AND METHODS

We retrospectively analyzed the impact of HTLV-1 in patients who underwent organ transplantation, including 54 allo-HSCT cases and 31 renal transplantation cases, for an 11-year period from January 2006 to December 2016.

Among the 54 allo-HSCT cases, the HTLV-1 status of the allo-HSCT recipients was ATL in nine and one HTLV-1 carrier. All donors for allo-HSCT tested negative for HTLV-1. We previously reported nine patients with aggressive-type ATL who underwent allo-HSCT at a single institution in Miyazaki between January 2006 and July 2015.<sup>31</sup> Of the nine patients with ATL, three received mogamulizumab therapy before allo-HSCT due to the poor control of refractory ATL.<sup>34</sup>

At our institution, based on the allo-HSCT treatment guidelines by the Fukuoka Bone Marrow Transplantation Group (FBMTG),<sup>35</sup> the indications for allo-HSCT were as follows: age, <65 years; Eastern Cooperative Oncology Group PS, 0–2; adequate liver and kidney function; serum bilirubin, <2.0 mg/dl; and serum creatinine, <2.0 mg/dl. Patients <55 years old were preconditioned with a myeloablative conditioning regimen (MAC) consisting of total body irradiation (TBI) of 12 Gray (Gy) and cyclophosphamide administration (CPA; 120 mg/kg), whereas patients aged between 55 and 65 years were preconditioned with a reduced intensity (RI) conditioning regimen, consisting of fludarabine (Flu; 180 mg/m<sup>2</sup>), busulfan (BU; 6.4 mg/kg), and low-dose TBI (2 Gy), for myeloid malignancy and Flu (125 mg/m<sup>2</sup>), melphalan (L-PAM; 150 mg/m<sup>2</sup>), and low-dose TBI (2 Gy) for lymphoid malignancy. For those with poor disease control (PD) before allo-HSCT, high-dose cytarabine (HDAC) or etoposide (VP-16) was additionally administered during the conditioning regimen for lymphoid malignancy. Eligible donors included human leukocyte antigen (HLA)-identical

related and HLA-identical unrelated donors from the Japan Marrow Donation Program [unrelated bone marrow (UR-BM)] as well as cord blood (CB) from the Japan Cord Blood Bank Network (JCBBN). Prophylaxis for graft-versus-host disease (GVHD) was performed using short-term methotrexate (MTX) plus cyclosporine (CSP) on CB donors for allo-HSCT, and short-term MTX plus tacrolimus (FK 506) on UR-BM donors for allo-HSCT.

Regarding renal transplantation, the 31 cases comprised 22 living-donor and nine cadaveric-donor renal transplants. The status of HTLV-1 infection among the recipients and donors, and the protocol of immunosuppressive pharmacotherapy to prevent graft rejection after renal transplantation are described below. All donors for renal transplantation tested negative for HTLV-1, and we excluded an HTLV-1 positive donor based on the recommendation of the Japanese Society for Clinical Renal Society and the Ministry of Health, Labour and Welfare in 2014. Thus, two HTLV-1 carrier donors were excluded as renal transplantation donors at the health check-up. Only one recipient undergoing renal transplantation tested positive for HTLV-1. The immunosuppressive pharmacotherapy protocol to prevent graft rejection in patients after renal transplantation was as follows: induction therapy with basiliximab (20 mg daily at transplant and on postoperative day 4), followed by mycophenolate mofetil (MMF; 1000 mg twice daily, tapered to 500 mg twice daily at approximately 3 months post-transplant), and corticosteroids (250-mg bolus injection intraoperatively, 24 mg daily in the first week, tapered to 4 mg daily by 1 month post-transplant). Rituximab was administered 1 week before transplant to patients who received repeat transplants and ABO-incompatible transplants.<sup>36</sup>

This retrospective study was conducted in compliance with good clinical practice and the ethical principles of the Declaration of Helsinki. The appropriate ethics committees and institutional review boards approved this study.

## RESULTS

We retrospectively analyzed the impact of HTLV-1 on organ transplantation in 54 allo-HSCT BMT cases and 31 renal transplantation cases (Table 1).

### *The impact of HTLV-1 after allo-HSCT*

Among the 54 allo-HSCT cases, the HTLV-1 status of the allo-HSCT recipients was ATL in nine and one HTLV-1 carrier (Table 2). All donors for allo-HSCT tested negative for HTLV-1. Among the nine ATL cases after allo-HSCT, four eventually relapsed due to proliferation of recipient-derived ATL cells, as confirmed by PCR analysis for donor chimerism. Only one HTLV-1 carrier recipient who underwent allo-HSCT did not present with ATL or HAM development after allo-HSCT during follow-up. However, HAM-mimicking myelitis developed in the absence of anti-HTLV-1 antibody production with rapid development and progression of clinical symptoms at 5 months after allo-HSCT.

**Table 1.** The impact of HTLV-1 on organ transplantation [allogeneic hematopoietic stem cell transplantation (allo-HSCT) or renal transplantation] at our institution

Organ transplantation	Cases (an 11-year period from January 2006 to December 2016)	HTLV-1 status of organ transplantation	After organ transplantation		
			ATL development	atypical HAM	PTLD
Bone Marrow Transplantation	54 cases	Recipient : ATL (9) HTLV-1 carrier (1) Donor (0)	ATL relapse (recipient) 4	+ 5 months	-
Renal Transplantation	31 cases Living donor :22, cadaveric donor :9 (cardiopulmonary arrest donor 6, brain-dead donor 3)	Recipient (1) HTLV-1 carrier (1) Donor(0)	-	-	+ 10 years brain

We retrospectively analyzed the impact of HTLV-1 in 54 allo-HSCT cases and 31 renal transplantation cases.

In the 54 allo-HSCT cases, the HTLV-1 status of the organ transplantation recipients was as follows: nine ATL cases and one HTLV-1 case. All donors tested negative for HTLV-1. After allo-HSCT, ATL development was not observed. However, atypical HAM developed demonstrating the absence of anti-HTLV-1 antibodies and the presence of HTLV-1 proviral DNA, with rapid development and progression of the symptoms at 5 months.

Of the 31 renal transplantation cases, 22 were living-donor and nine were cadaveric-donor transplants. All donors tested negative for HTLV-1. One recipient was an HTLV-1 carrier. We excluded an HTLV-1-positive donor according to the recommendation of the Japanese Society for Clinical Renal Society and the Ministry of Health, Labour and Welfare in 2014. At our institution, one HTLV-1 carrier who underwent renal transplantation did not develop ATL or HAM during careful follow-up. One HTLV-1 non-carrier developed PTLN in the brain 10 years after renal transplantation.

#### ***HTLV-1 carrier who underwent allo-HSCT: case 10***

A 60-year-old male HTLV-1 carrier was diagnosed with myelodysplastic syndrome (MDS)-derived AML, and was subsequently treated with azacitidine (AZA) for bridging therapy after allo-HSCT with 30 mg/m<sup>2</sup> of fludarabine (FLU) for 6 days, 0.8 mg/kg of intravenous busulfan (BU) every 6 hr for a total of eight dose, and 2 Gy of total body irradiation (TBI). Moreover, for GVHD prophylaxis, the patient received FK plus short-term MTX (Table 2). The patient did not develop ATL or HAM after allo-HSCT during follow-up.

#### ***A patient with atypical HAM after allo-HSCT: case 2***

A 46-year-old woman was diagnosed with atypical HAM at 5 months post-allo-HSCT with acute-type ATL (Figures 1A and 1B). Complete remission (CR) of ATL was observed after one cycle of modified LSG15 therapy, four cycles of mogamulizumab therapy, and three cycles of CHOP therapy. Allo-HSCT was performed by MAC consisting of TBI 12 Gy and CPA 120 mg/kg for the patient from an unrelated donor of the Japan Marrow Donor Program with one locus HLA mismatch in a DNA allele. The number of days from the last mogamulizumab administration to allo-HSCT was 140. The patient developed tremors at 3 months, anuresis at 4 months, and bilateral lower-limb paralysis at 5 months after allo-HSCT for ATL.

Laboratory testing of cerebrospinal fluid (CSF) demonstrated upregulation of inflammatory cells (82/mm<sup>3</sup>) and the total protein level (150 mg/dl), an oligoclonal band by immunoelectrophoresis (IEF), elevation of Th1 cytokines (neopterin, 95 pmol/ml; CXCL10, 41556 pg/ml), the absence of anti-HTLV-1 antibodies, and the presence of HTLV-1 DNA by PCR (Table 3A). Transition of an anti-HTLV-1 antibody revealed that serum anti-HTLV-1 antibodies had disappeared

before the onset of atypical HAM (Table 3B). On flow cytometry (FCM) analysis, the proliferating inflammatory cells were CD4<sup>+</sup> CXCR3<sup>+</sup> (mostly CCR4<sup>-</sup> and partially CCR4<sup>+</sup>) (Figure 2A). Cytological analysis of CSF revealed the absence of ATL cells. On MRI, cervical (lower than C5/C6), thoracic, and lumbar areas of the spinal cord exhibited diffuse swelling with an enhanced irregular T2 high-intensity signal (Figures 2B–F).

Thus, we made a final diagnosis of acute-onset atypical HAM based on the following findings: the symptoms of tremors, anuresis, and paralysis, the upregulation of inflammatory cells (82/mm<sup>3</sup>), the total protein level (150 mg/dl), and Th1 cytokine levels [neopterin, 95 pmol/ml; CXCL10 (also known as IP-10), 41556.8 pg/ml] in the CSF, radiological findings (swelling of the spinal cord with enhancement), the absence of an anti-HTLV-1 antibody and ATL cells, and the presence of HTLV-1 DNA in the CSF according to PCR analysis. The criteria of HAM were not fulfilled due to the lack of anti-HTLV-1 antibodies in the CSF after allo-HSCT. The bone marrow after allo-HSCT was found to contain donor-derived hematopoietic cells by PCR analysis for donor chimerism, but the inflammatory cells in the CSF in this case were not subjected to PCR analysis for donor chimerism. Treatment with two cycles of mPSL pulse therapy and maintenance PSL therapy with rehabilitation led to remission of the symptoms, and normalization of laboratory and radiological findings without relapse. However, atypical HAM relapsed during PSL tapering. Thus, we again administered mPSL pulse therapy with cyclosporine for atypical HAM. These treatments resolved the clinical symptoms, and returned the laboratory and radiological findings to CR of acute-type ATL.

**Table 2.** Nine ATL cases and one HTLV-1 carrier among allo-HSCT cases

Case	Age	Sex	Subtype	Chemo-therapy	Disease status	Allo-HSCT (Source)	Allo-HSCT (Conditioning)	GVHD prophylaxis	Acute GVHD	Survival
1	63	F	Lymphoma	CHOP (1) +Mog (8)	SD	Unrelated HLA full matched BM	TBI/CY	CSP+sMTX	Grade 2 skin	355 days (dead)
2	46	F	acute	VCAP- VMPV-ECP (1)+Mog (4)	CR	Unrelated HLA full matched BM	TBI/CY	FK+sMTX	Grade 2 skin	295 days (alive)
3	54	M	acute	VCAP- VMPV-ECP (1)+Mog (8)	CR	Unrelated HLA full matched BM	TBI/CY	FK+sMTX	Grade 2 skin	546 days (alive)
4	49	F	Lymphoma	CHOP-VMMV	CR	CB	TBI/CY	CSP+sMTX	-	138 days (dead, relapse)
5	42	M	Lymphoma	CHOP-VMMV	CR	CB	TBI/CY	CSP+sMTX	-	135 days (dead, relapse)
6	61	F	acute	CHOP-VMMV	PR	CB	BU/FLU/TBI	CSP+sMTX	-	28 days (dead, relapse)
7	44	F	acute	VCAP- VMPV-ECP	CR	Unrelated HLA full matched BM	TBI/CY	FK+sMTX	-	1084 days (alive)
8	56	F	acute	VCAP- VMPV-ECP	CR	Unrelated HLA full matched BM	TBI/CY	FK+sMTX	-	1156 days (alive)
9	41	F	acute	VCAP- VMPV-ECP	CR	Unrelated HLA full matched BM	TBI/CY	FK+sMTX	-	122 days (dead)
10	60	M	HTLV-1 carrier AML	AZA	PR	UR-BMT	FLU/BU/TBI	FK+sMTX	-	1080 days (alive)

Abbreviations: F:female, M:male, allo-HSCT: allogeneic hematopoietic stem cell transplantation, CR: complete response, PR: partial response, TBI: total body irradiation, CY: cyclophosphamide, FLU: Fludarabine, BU: busulfan, CB: cord blood, BM: bone marrow

### ***The impact of HTLV-1 on renal transplantation***

Regarding renal transplantation, the 31 cases comprised 22 living-donor and nine cadaveric-donor renal transplants. All donors for renal transplantation tested negative for HTLV-1. One recipient was an HTLV-1 carrier. We excluded HTLV-1-positive donors according to the recommendation of the Japanese Society for Clinical Renal Society and the Ministry of Health, Labour and Welfare in 2014. Thus, two HTLV-1 carrier donors were excluded as renal transplantation donors at the health check-up. At our institution, only one recipient did not present with ATL or HAM development after renal transplantation during follow-up. Only one HTLV-1-negative recipient developed PTLD in the brain 10 years after renal transplantation.

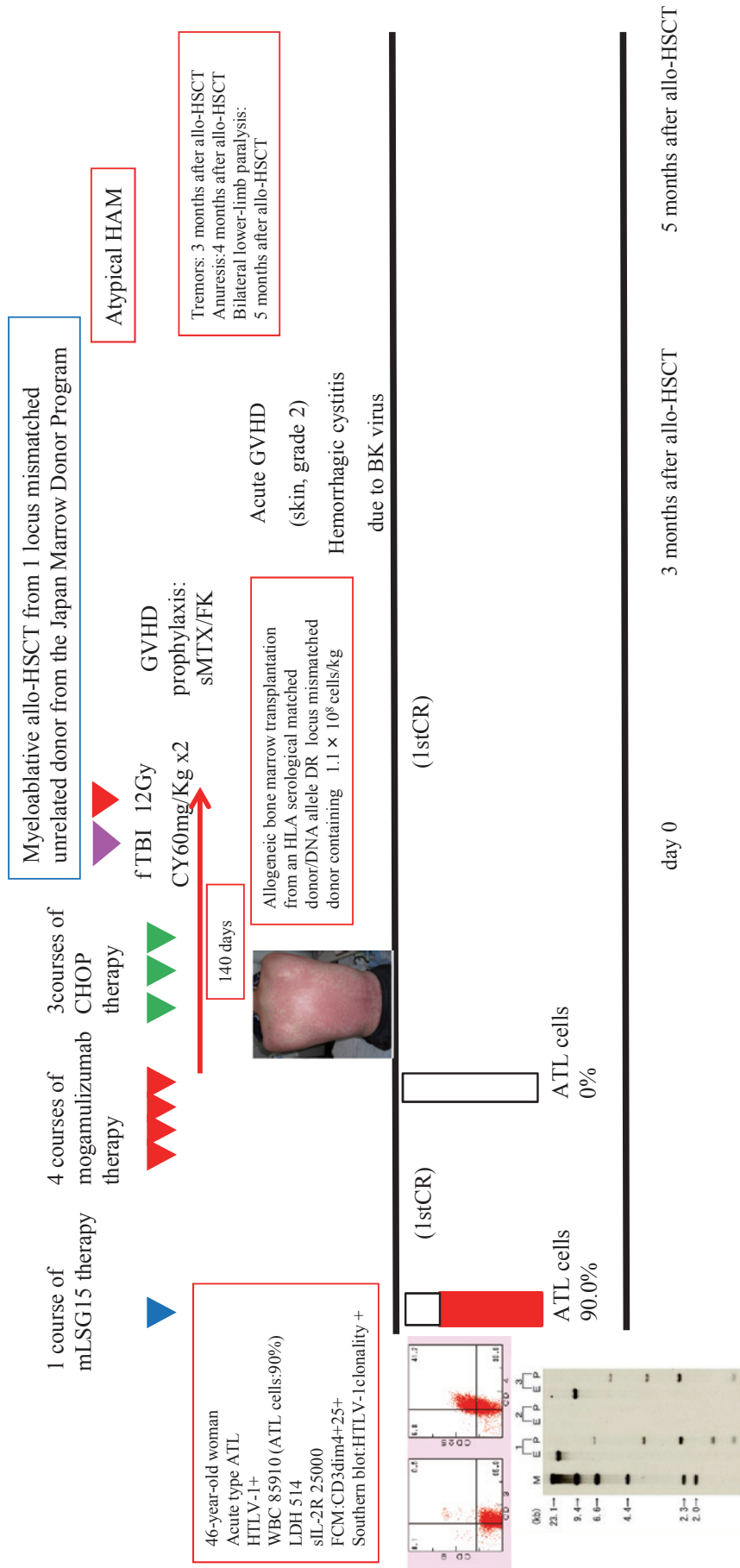
### ***An HTLV-1 carrier with renal transplantation: case 11***

We present the clinical course of one HTLV-1 carrier recipient who underwent renal transplantation (Table 4). A 65-year-old male was diagnosed with end stage renal disease

(ESRD, unknown etiology) and subsequently underwent renal transplantation. The patient was found to be an HTLV-1 carrier before renal transplantation. Laboratory tests confirmed the HTLV-1 carrier status, and approximately 1% of the proliferating ATL cells in the peripheral blood expressed CD4 and CD25. He had normal lactate dehydrogenase (LDH) levels, upregulation of soluble IL-2 receptor (sIL-2R) (2257 U/ml), no clonality of the HTLV-1 genome according to Southern blot analysis, and no systemic lymphadenopathy/splenomegaly. Thus far, the patient has not developed ATL or HAM during careful follow-up at 120 days after renal transplantation.

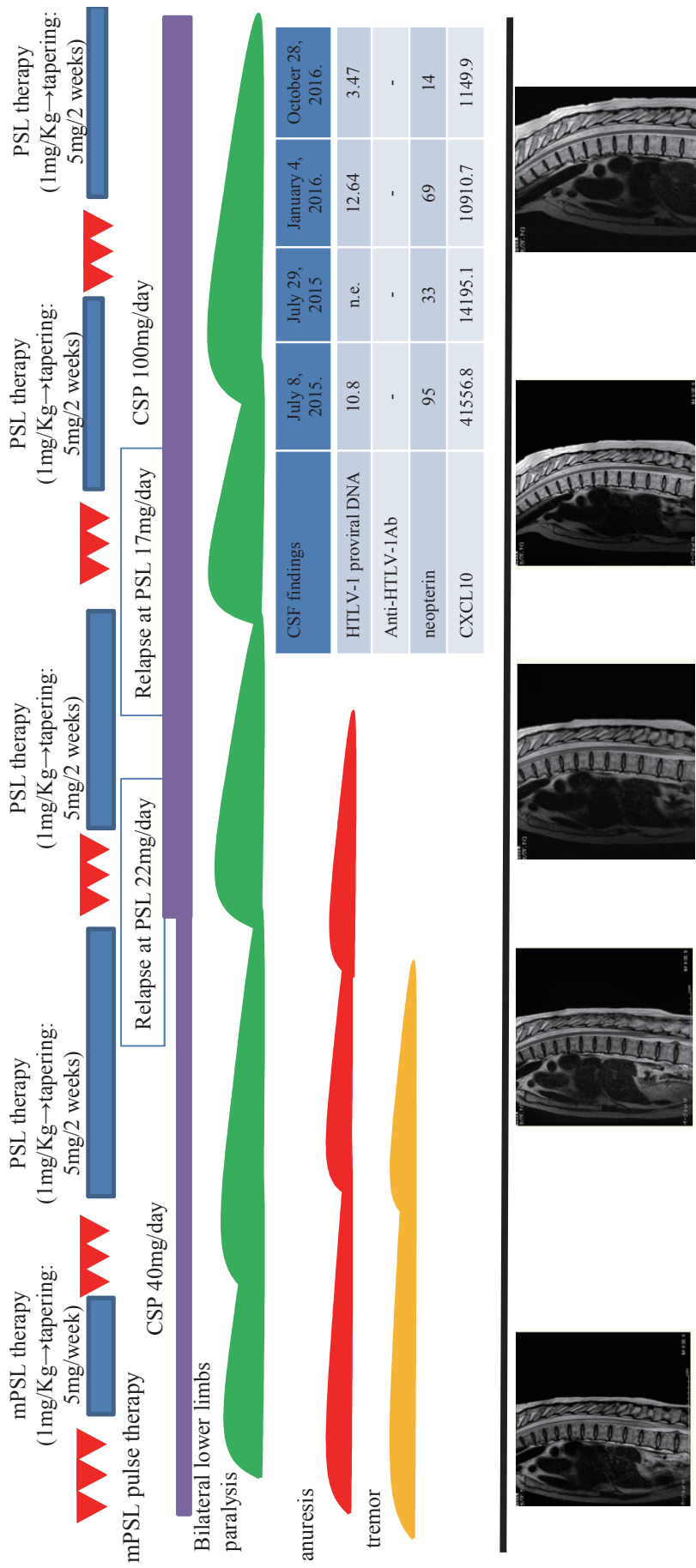
### ***Development of PTLD in the brain of a patient 10 years after renal transplantation: case 12***

A 60-year-old male HTLV-1 non-carrier was diagnosed with ESRD due to diabetes mellitus (DM) and subsequently underwent renal transplantation on June 23, 2006. During follow-up, the patient developed aggressive lower-limb paralysis on January 6, 2016. CT demonstrated a 3-cm,



**Fig. 1A.** The outline of chemotherapy and allo-HSCT for acute-type ATL (case 2). We describe the case of a 46-year-old woman who was diagnosed with atypical HAM at 5 months after allo-HSCT for acute-type ATL. She demonstrated CR of ATL after one cycle of modified LSG15 therapy, four cycles of mogamulizumab therapy, and three cycles of CHOP therapy. Allo-HSCT was performed by MAC consisting of TBI 12 Gy and CPA 120 mg/kg for the patient from an unrelated donor of the Japan Marrow Donor Program with one locus HLA mismatch in a DNA allele. The number of days from the last mogamulizumab administration to allo-HSCT was 140. The patient developed tremors at 3 months, anuresis at 4 months, and bilateral lower-limb paralysis at 5 months after allo-HSCT for ATL.





**Fig. 1B.** The timing of diagnosis and treatment for atypical HAM (case 2). We made a final diagnosis of acute-onset atypical HAM based on the following findings: the symptoms of tremors, enuresis, and paralysis, the upregulation of inflammatory cells (82/mm<sup>3</sup>), the total protein level (150 mg/dl), and Th1 cytokine levels [neopterin, 95 pmol/ml; CXCL10 (also known as IP-10), 41556.8 pg/ml] in the CSF, radiological findings (swelling of the spinal cord with enhancement), the absence of anti-HTLV-1 antibodies and ATL cells, and the presence of HTLV-1 DNA in the CSF according to PCR analysis. The criteria of HAM were not fulfilled due to the lack of anti-HTLV-1 antibodies in the CSF after allo-HSCT. Treatment with two cycles of mPSL pulse therapy and maintenance PSL therapy with rehabilitation led to remission of the symptoms, and normalization of laboratory and radiological findings without relapse. However, atypical HAM relapsed during PSL tapering. Thus, we again administered mPSL pulse therapy with cyclosporine for atypical HAM. These treatments resolved the symptoms and returned the laboratory and radiological findings to CR status of acute-type ATL.

**Table 3A.** Laboratory testing of cerebrospinal fluid (CSF) at admission (case 2)

	Laboratory data	Results
CSF at admission	CSF cells	82 Multi-nucleated cells 23 % Mononucleated cells 77 %
	TP	150
	Sugar	67
	Cl	118
	HSV/CMV/HHV-6/VZV DNA	<100
	MBP	114 (normal range: <102 )
	IEF	Oligoclonal band
	IgG (CSF)	14.9 mg/dl
	Aquaporin 4(AQP4) Ab	<1.3
	Proviral DNA in CSF	10.80 copies/100 cells
	Anti-HTLV-1 Ab (PA method)	Negative (over 16:positive)
	Neopterin	95 (pmol/mL) (control < 5 pmol/mL)
	CXCL10	41556.8 (pg/mL) (control <200.0 pg/mL)

**Table 3B.** Laboratory findings regarding anti-HTLV-1 antibody transition in serum (case 2)

	March, 2015	April, 2015	May, 2015	June, 2015
HTLV-1 antibody in serum chemistry	2 <sup>+</sup> 7	2 <sup>+</sup> 7	2 <sup>+</sup> 5	-

low-density area with a ring enhancement lesion in the right anterior lobe, and multiple low-density areas in the right occipital, left anterior, and temporary lobes (Figure 3A). Furthermore, MRI revealed a 3-cm, heterogeneous high-intensity area, and multiple T2 high-intensity lesions in the right occipital, left anterior, and temporary lobes (Figure 3B). These observations suggested multiple brain metastases or PTLD in the brain. On subsequent histological analysis of a brain biopsy specimen, diffuse proliferation of abnormal lymphoid cells expressing B-cell markers (CD20 and CD79a) and Epstein-Barr virus (EBV) infection markers were noted [EBV-encoded small RNA (EBER) according to fluorescence *in situ* hybridization (FISH)] (Figures 3C–E). We diagnosed him with PTLD (EBV+) based on the results of the brain biopsy. Therefore, FK and MMF administration was immediately ceased. PTLD in the brain remained unchanged, and he was treated with rituximab at a dose of 375 mg/m<sup>2</sup> and high-dose cytarabine (HDAC) at 3 g/body every 12 hr for a total of four doses during hemodialysis. Even after one cycle of HDAC therapy, PTLD in the brain progressed aggressively. The patient was given rituximab (375 mg/m<sup>2</sup>) and high-dose methotrexate (HD-MTX) at 3.5 g/body during hemodialysis. However, PTLD in the brain continued progressing aggressively, and he died.

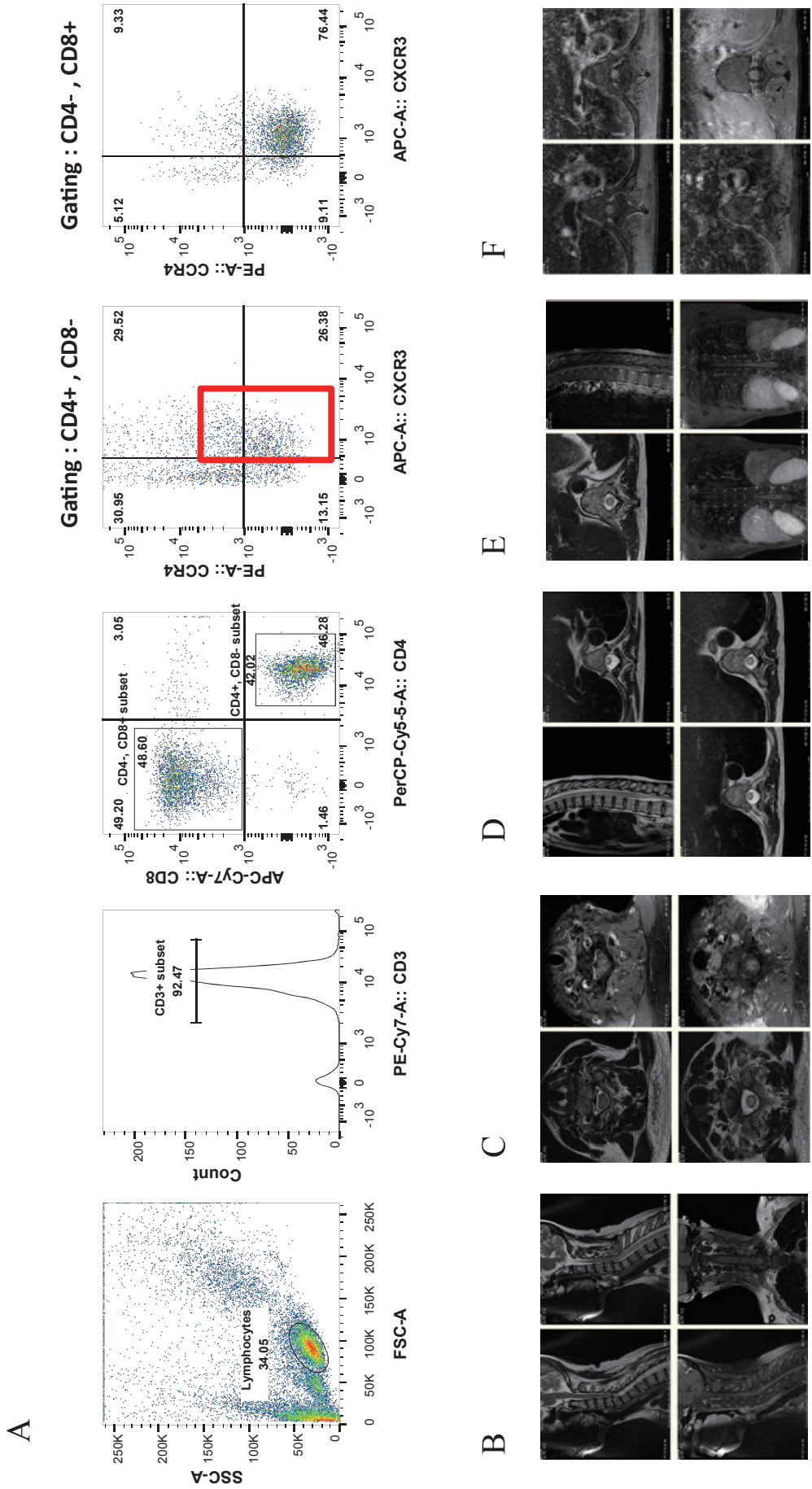
## DISCUSSION

In our retrospective study on 54 cases of allo-HSCT, one HTLV-1 carrier who underwent allo-HSCT for MDS-derived AML did not develop ATL or HAM during the follow-up period. Among nine ATL cases after allo-HSCT, four eventually relapsed due to proliferation of recipient-derived ATL cells. Of note, only one patient with ATL who underwent allo-HSCT presented with rapid and progressive development of atypical HAM at 5 months post-allo-HSCT.

In our retrospective study on 31 cases of renal transplantation, one HTLV-1 carrier recipient who underwent renal transplantation did not develop ATL or HAM during follow-up, one HTLV-1 non-carrier recipient developed PTLD in the brain 10 years after renal transplantation, and two HTLV-1 carrier donors were excluded based on the recommendation of the Japanese Society for Clinical Renal Society and the Ministry of Health, Labour and Welfare in 2014.

Our clinical study demonstrated the following:

- (i) No development of ATL or HAM in 2 HTLV-1 carriers after organ transplantation (allo-HSCT and renal transplantation).
- (ii) The development of atypical HAM after allo-HSCT in one ATL case during the follow-up period.



**Fig. 2.** Flow-cytometry analysis of CSF (**A**) and MRI findings (**B–F**) at admission (case 2).



**Table 4.** An HTLV-1 carrier with renal transplantation (case 11)

Case	Age	Sex	Subtype	ATL cells in peripheral blood	FCM analysis	sIL-2R	Southern blot analysis	CT (Chest/Abdominal CT)	Renal transplantation (source)	ATL development	HAM development	Survival
11	65	M	HTLV-1 carrier	1%	CD4 +CD 25+	2257	No clonality	No systemic lymphadenopathy /no splenomegaly	Living donor	-	-	120 days (alive)

A 65-year-old male (case 11) was diagnosed with ESRD (unknown etiology) and underwent renal transplantation before the health check-up. The patient was found to be an HTLV-1 carrier before renal transplantation examination. Laboratory testing confirmed the HTLV-1 carrier status, and approximately 1% of the proliferating ATL cells in the peripheral blood expressed CD4 and CD25. He had a normal LDH level, upregulation of sIL-2R, no clonality of the HTLV-1 genome according to Southern blot analysis, and no systemic lymphadenopathy/splenomegaly. After renal transplantation, the patient did not develop ATL or HAM during careful follow-up.

(iii) No new HTLV-1 infection via organ transplantation from HTLV-1 carrier donors to HTLV-1 negative recipients (allo-HSCT and renal transplantation).

We focused on HTLV-1 infection and HTLV-1-associated diseases, including ATL and HAM or atypical HAM, after organ transplantation.

We observed no development of ATL or HAM in two HTLV-1 carriers after organ transplantation (allo-HSCT or renal transplantation) during the follow-up period.

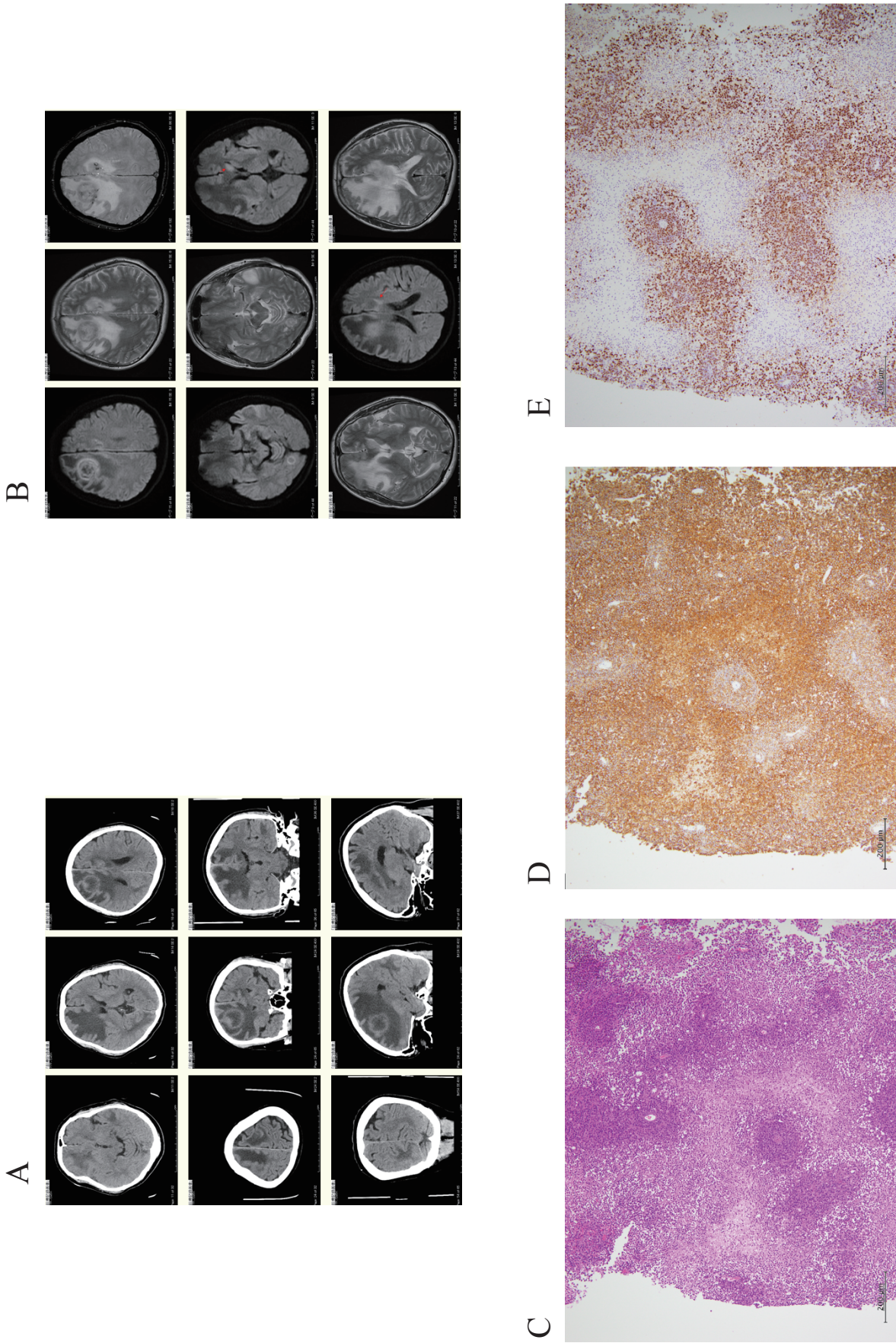
Regarding HAM development, one case after allo-HSCT and 13 cases after organ transplantation, including 10 cases after renal transplantation, two cases after liver transplantation, and one case after heart transplantation have been reported (Table 5).<sup>21-33</sup> The majority of the cases were due to donor-derived HAM.<sup>22, 23, 28</sup> Thus, the Japanese Society for Clinical Renal Society and the Ministry of Health, Labour and Welfare in 2014 recommended the exclusion of HTLV-1 positive carriers from renal transplantation donors based on the high incidence of HAM after renal transplantation. The presence of anti-HTLV-1 antibodies, and rapid development and progression during several months to several years were characteristic of HAM after organ transplantation, differing from the slowly progressing HAM generally observed in patients aged 40 to 60 years.<sup>21-33</sup> In our study, one HTLV-1 carrier who underwent allo-HSCT and one HTLV-1 carrier who underwent renal transplantation did not develop HAM during careful follow-up.

Regarding ATL development after allo-HSCT and organ transplantation (renal or liver transplantation), two cases were reported after allo-HSCT and 11 cases after organ transplantation, including six cases after renal transplantation and five cases after liver transplantation (Table 6).<sup>6-20</sup> The majority of the cases were recipient-derived ATL,<sup>7, 8, 13</sup> except for two cases of ATL that developed after allo-HSCT.<sup>17, 18</sup> The rapid development and progression of ATL during several months to several years is characteristic of ATL after allo-HSCT and organ transplantation, different from the slowly progressing ATL generally observed in patients aged 40 to 60 years.<sup>6-20</sup> We previously reported three cases of acute-type ATL development that originated from a recipient in eight HTLV-1 carriers among 164 living-donor liver transplant recipients undergoing immunosuppressive treatment.<sup>13</sup> At our institution, among nine ATL cases after allo-HSCT, four

eventually relapsed because of recipient-derived ATL cells confirmed to have recipient chimerism by PCR analysis. This is different from the study of donor-derived ATL development by Kitamura *et al.*, in which the development of HTLV-1-associated donor-derived PTLD occurred after allo-HSCT by virus transmission from recipient to donor cells.<sup>19</sup> Moreover, one HTLV-1 carrier who underwent allo-HSCT and one HTLV-1 carrier who received renal transplantation did not develop ATL or HAM during careful follow-up. Further follow-up is needed for early detection and immediate treatment of ATL or HAM after allo-HSCT or renal transplantation. One HTLV-1 non-carrier in our study developed PTLD (EBV+) in the brain after renal transplantation instead of ATL. Immediate diagnosis and subsequent treatment, including rituximab plus HDAC or HD-MTX, did not improve PTLD in the brain according to a review by Nagel *et al.*,<sup>37</sup> a previous report of PTLD in the brain,<sup>15, 38</sup> and previous reports on PTLD treatments.<sup>39-46</sup> Thus, careful follow-up may also be necessary to detect the development of PTLD after renal transplantation.

In the present study, negative clinical data was considered to indicate the absence of ATL or HAM development in 2 HTLV-1 carrier cases after organ transplantation. Although our study population was small and the cohort study period was too short, the clinical data of two HTLV-1 carriers who did not develop ATL or HAM after organ transplantation may help clarify the impact of HTLV-1 infection on organ transplantation. In the future, further accumulation of cases or systemic review of HTLV-1 carriers after organ transplantation is needed.

Second, in one ATL case after allo-HSCT, atypical HAM rapidly developed at five months after allo-HSCT. Kawamata *et al.* first reported HAM-mimicking myelitis after allo-HSCT for ATL.<sup>21</sup> In this report, the patient developed crural paresis 14 months after allo-HSCT. Initially, she was diagnosed with CNS relapse of ATL, and was treated by intrathecal injection and whole-brain and spine irradiation. However, the neurological symptoms recurred 5 months later. She was diagnosed with HAM-mimicking myelitis based on her symptoms, MRI findings, CSF analysis demonstrating increased CD4<sup>+</sup> CXCR3<sup>+</sup> CCR4<sup>+</sup> cell numbers and Th1 cytokine levels [neopterin and CXCL10 (also known as IP-10)], without anti-HTLV-1 antibodies or HTLV-1 proviral DNA.



**Fig. 3.** *A* and *B.* CT for case 11 demonstrated a 3-cm, low-density area with a ring enhancement lesion in the right anterior lobe, and multiple low-density areas in the right occipital, left anterior, and temporal lobes (*A*). Furthermore, MRI revealed a 3-cm, heterogeneous high-intensity area, and multiple T2 high-intensity lesions in the right occipital, left anterior, and temporal lobes (*B*). These observations suggested multiple brain metastases or PTLD in the brain. *C, D* and *E.* On histology the brain biopsy specimen of case 11, the abnormal lymphoid cells had larger and hyperchromatic nuclei, and had diffusely proliferated predominantly in the perivascular region with marked necrosis (*C*). Immunohistochemically, the cells were positive for L26 (CD20), CD79a, MUM1, and Bcl-2, and negative for CD3, UCHL1 (CD45Ro), CD5, CD10, and Bcl-6, indicating non-GC type diffuse large B-cell lymphoma (DLBCL) (*D*). Moreover, all lymphoid cells expressed EBV markers, as assessed by EBER-FISH (*E*). Thus, these findings are consistent with monomorphic post-transplant lymphoproliferative disorders [DLBCL with EBV (+)].

**Table 5.** Previous reports of HAM-mimicking myelitis after allo-HSCT and HAM after organ transplantation

Year	HAM	Recipient after OTP	Development of HAM	Age, sex	Transplantation	Recipient HTLV-1	Donor HTLV-1	Recipient HTLV-1 after organ transplantation	HTLV-1 DNA	Neopterin	Immune suppression	Donor cells	Therapy	Outcome
Kawamata <i>et al.</i>	2014	HAM-mimicking myelitis	-	20 months	63, F	BMT	+	-	-	8	CSP	CD4+ CXCR3+ CCR4+	mPSL	Imp
Present case	2017	Atypical HAM	-	5 months	46, F	BMT	+	-	10.8 copies/1000 cells	95	FK+sMTx →CSP	CD4+ CXCR3+ partially CCR4+	mPSL	Imp
Nagamine <i>et al.</i>	2014	HAM	+	2 months	38, F	RTP	-	+	15/1000(PB)	51	FK/MMF	CD4+:54%	IFN $\alpha$	Imp
Ramanan <i>et al.</i>	2014	HAM	+	5 months	56, M	RTP	-	+	n.d.	n.d.	FK/MMF PSL	n.d.	PSL AZT	Imp
Inose <i>et al.</i>	2010	HAM	+	10 months	51, M	RTP	-	n.e.	7.4%	n.d.	CY/PSL	n.d.	IFN $\alpha$	Imp
Kuroki <i>et al.</i>	2007	HAM	n.e.	17 months	40, M	RTP	n.e.	n.e.	0.83%	n.d.	CY/MMF/PSL	n.d.	PSL	Imp
Toro C <i>et al.</i>	2003	HAM	+	24 months	54, F	RTP	-	+	12.44% (164.4/1000)	n.d.	CY	n.d.	PSL	PD
Zarranz Imirizaidu JJ <i>et al.</i>	2003	HAM	+	20 months	57, M	RTP	-	+	16.44% (124.4/1000)	n.d.	CY	n.d.	PSL	PD
Nakamura N <i>et al.</i>	2001	HAM	+	< 1 year	48, M	RTP	n.e.	n.e.	n.d.	121	n.d.	n.d.	PE	Imp
Shintani <i>et al.</i>	2001	HAM	+	7 years	56, M	RTP	n.e.	n.e.	n.d.	n.d.	n.d.	n.d.	PSL	n.d.
Nakatsuji Y <i>et al.</i>	2010	HAM	+	4 years	50, M	RTP	-	n.e.	n.d.	n.d.	CY/MMF/PSL	n.d.	n.d.	n.d.
Kuroda Y <i>et al.</i>	1992	HAM	+	11 months	32, M	RTP	n.e.	+	n.d.	n.d.	CY/MZR PSL.AZA	n.d.	PSL	Imp
Soyama A	2008	HAM	+	20 months	58, M	Liver TRP	+	+	180/1000	n.d.	TAC/PSL	n.d.	IFN $\alpha$ ribavirin	unchange
Toro C <i>et al.</i>	2003	HAM	+	18 months	44, F	Liver TRP	-	+	+	n.d.	TAC	n.d.	PSL IFN $\alpha$	SD
Zarranz Imirizaidu JJ <i>et al.</i>	2001	HAM	+	5 months	41, M	Heart TRP	-	+	n.d.	n.d.	n.d.	n.d.	PSL	Imp

In the present and previous reports of HAM-mimicking myelitis or atypical HAM after allo-HSCT and of HAM after organ transplantation (renal, liver, or heart transplantation), two cases were after allo-HSCT, and 13 cases were after organ transplantation, including 10 cases after renal transplantation, two cases after liver transplantation, and one case after heart transplantation. The majority of cases were donor-derived HAM. The presence of anti-HTLV-1 antibodies, and rapid development and progression of HAM were characteristic of HAM after organ transplantation. In one case after allo-HSCT, HAM-mimicking myelitis developed in the absence of anti-HTLV-1 antibodies and the presence of HTLV-1 proviral DNA, with rapid development and progression of the symptoms. In our case after allo-HSCT, atypical HAM developed in the absence of anti-HTLV-1 antibodies and presence of HTLV-1 proviral DNA, with rapid



**Table 6.** Previous reports of ATL development after allo-HSCT and organ transplantation

	Year	ATL	Development of ATL	Age, sex	Transplantation	Recipient HTLV-1	Donor HTLV-1	Immune suppression	Therapy for ATL	Outcome
Tamaki <i>et al.</i>	2006	ATL	2 months	63, F	BMT	+	+	CSP/PSL	Irradiation of 3060 cGy and rapid reduction of immunosuppressive agents	32months alive
Nakamizo <i>et al.</i>	2011	ATL	6 years	46, F	BMT	+	+	CSP	Whole brain irradiation and localised irradiation	27 months alive
Kitamura <i>et al.</i>	2017	ATL	16 months	52, M	BMT	+	-	FK/PSL	PSL	Several months, PD
Kawano and Yoshizumi <i>et al.</i>	2006	ATL	6 months	39, F	Liver trp	+	+	FK/PSL	Discontinuation of immune suppression agents	15 days dead
Kawano and Yoshizumi <i>et al.</i>	2006	ATL	2 years	45, M	Liver trp	+	+	FK/PSL	Chemotherapy LSG 15 ③	3 months dead
Kawano and Yoshizumi <i>et al.</i>	2006	ATL	9 months	67, M	Liver trp	+	+	FK/PSL	Chemotherapy CHOP① and CHOV-VMMV③	5 months dead
Yoshizumi <i>et al.</i>	2012	ATL	4 years	48, M	Liver trp	-	+	CSP/PSL	Chemotherapy	15 months dead
Iiona <i>et al.</i>	2013	ATL	2 years	59, M	Liver trp	-	+	FK/PSL	Chemotherapy	27 months dead
Zanke <i>et al.</i>	1989	ATL	2 years	43, M	Renal trp	n.d.	n.d.	CSP/PSL	Chemotherapy CVP④	20 months alive
Tsurumi <i>et al.</i>	1992	ATL	4 years	32, M	Renal trp	+	-	CSP/mizoribine	Chemotherapy CHOP⑥, KM2210	13 months alive
Willizms <i>et al.</i>	1994	ATL	13 years	42, M	Renal trp	n.d.	n.d.	Azathioprine/PSL	No treatment	1 day dead
Jenks <i>et al.</i>	1995	ATL	9 months	61, M	Renal trp	+	-	CSP/azathioprine/PSL	Chemotherapy CHOP①	5 days dead
Mouri <i>et al.</i>	2000	ATL	3 years	49, F	Renal trp	n.d.	n.d.	FK/azathioprine/PSL	Chemotherapy CHOP①	1month dead
Ichikawa <i>et al.</i>	2000	ATL	10 years	42, M	Renal trp	-	n.d.	CSP/azathioprine/PSL	Chemotherapy CHOP+radiation	3months dead
Glowacka <i>et al.</i>	2013	ATL	2 years	59, M	Liver trp	-	+	FK	PSL	alive
Glowacka <i>et al.</i>	2013	ATL	3 years	28, M	Renal trp	-	n.d.	FK/MMF	PSL	alive

In the present and previous reports of ATL development after allo-HSCT and organ transplantation (renal or liver transplantation), three cases were after allo-HSCT and 13 cases were after organ transplantation, including six cases after renal transplantation and five cases after liver transplantation. The majority of the cases were recipient-derived ATL, except for ATL development after allo-HSCT. Rapid development and progression were characteristic of ATL development after allo-HSCT and organ transplantation. At our institution, two HTLV-1 carriers who underwent allo-HSCT and renal transplantation did not develop ATL or HAM during careful follow-up.



Based on the diagnosis of HAM-mimicking myelitis, the reported patient was successfully treated with PSL.

Although we noted similar clinical findings, MRI results, and CSF findings as those reported by Kawamata *et al.*, the HTLV-1 proviral genome in CSF was detected in our case. Thus, it may have been a neurodegenerative disease caused by HTLV-1 infection. As anti-HTLV-1 antibodies were not detected in the CSF, we made a diagnosis of atypical HAM without anti-HTLV-1 antibodies in the CSF instead of HAM-mimicking myelitis. Previous reports regarding ATL development after organ transplantation have demonstrated that the transmission of HTLV-1 between donor cells and recipient cells can occur in organ transplantation patients.<sup>19,20</sup> In particular, Kitamura *et al.* reported HTLV-1-associated PTLD after allo-HSCT by virus transmission from recipient to donor cells.<sup>19</sup> Similar with the report by Kitamura *et al.*, the patient in our study may have developed atypical HAM after HTLV-1 transmission from recipient to donor cells based on the following findings: an HTLV-1-positive recipient and HTLV-1-negative donor before allo-HSCT, and the presence of HTLV-1 proviral DNA in the CSF and donor-derived hematopoietic cells after allo-HSCT.

Moreover, Yamano *et al.* proposed the following pathogenesis for HAM: HTLV-1 induces formation of CD4<sup>+</sup>CXCR3<sup>+</sup>CCR4<sup>+</sup> cells, designated as HAM/tropical spastic paraparesis (TSP) cells, which produce IFN- $\gamma$  and subsequently activate astrocytes. These cells then produce Th1 cytokines, which consequently damage neuronal cells.<sup>5</sup> In our case, atypical HAM donor cells with CD4<sup>+</sup>CXCR3<sup>+</sup> (mostly CCR4<sup>-</sup> and partially CCR4<sup>+</sup>) may have played a role in the pathogenesis of atypical HAM by inducing astrocytes to produce Th1 cytokines. Markedly high Th1 activity may be related to the development of atypical HAM. Thus, immediate diagnosis and immediate PSL treatment are necessary to improve the symptoms and reverse the radiological findings of atypical HAM after allo-HSCT. At present, caution is needed regarding the implications of this case for organ transplantation because only a few cases of HAM-mimicking myelitis or atypical HAM after allo-HSCT have been reported. Thus, further accumulation of similar cases after organ transplantation are required in the future.

In endemic areas of HTLV-1 infection, such as our institution in Miyazaki prefecture, we did not perform organ transplantation from HTLV-1 carrier donors to HTLV-1-negative recipients in order to prevent newly HTLV-1 infection. In our study on 54 patients who underwent allo-HSCT, including nine ATL patients and one HTLV-1 carrier, and 31 patients who underwent renal transplantation, all donors tested negative for HTLV-1. In 2014, the Japanese Society for Clinical Renal Society and the Ministry of Health, Labour and Welfare recommended the exclusion of HTLV-1-positive donors for renal transplantation. Thus, to prevent new HTLV-1 infection, organ transplantation from HTLV-1 carrier donors to HTLV-1-negative recipients should be avoided in clinical practice.

In conclusion, in our study, only one of 54 patients who underwent allo-HSCT developed atypical HAM. Furthermore,

of the 31 patients who underwent renal transplantation, one HTLV-1 non-carrier developed PTLD in the brain. One HTLV-1 carrier who received renal transplantation and one HTLV-1 carrier who underwent allo-HSCT did not develop ATL or HAM during follow-up. Although our study population was small and the cohort study period was too short, careful follow-up of HTLV-1 infected recipients after organ transplantation is important because atypical HAM can develop in ATL patients after allo-HSCT. In addition, to determine the risk for ATL or HAM development in HTLV-1 infected recipients, we prospectively followed up our cohort. In the future, further accumulation of cases or systemic review of HTLV-1 carriers after organ transplantation may clarify the clinical impact of HTLV-1 on organ transplantation.

## CONFLICT OF INTEREST

None of the authors has any conflicts of interest.

## REFERENCES

- 1 Taylor GP. Human T-lymphotropic virus type 1 infection and solid organ transplantation. *Rev Med Virol.* 2018; 28 : e1970.
- 2 Miyoshi H, Oshima K. Epidemiology of malignant lymphoma and recent progress in research on adult T-cell leukemia-lymphoma in Japan. *Int J Hematol.* 2018; 107 : 420-427.
- 3 Kogure Y, Kataoka K. Genetic alterations in adult T-cell leukemia/lymphoma. *Cancer Sci.* 2017; 108 : 1719-1725.
- 4 Osame M, Usuku K, Izumo S, *et al.* HTLV-1 associated myelopathy, a new clinical entity. *Lancet.* 1986; 1 : 1031-1032.
- 5 Yamano Y, Coler-Reilly A. HTLV-1 induces a Th1-like state in CD4<sup>+</sup>CCR4<sup>+</sup> T cells that produces an inflammatory positive feedback loop via astrocytes in HAM/TSP. *J Neuroimmunol.* 2017; 304 : 51-55.
- 6 Zanke BW, Rush DN, Jeffery JR, Israels LG. HTLV-1 T cell lymphoma in a cyclosporine-treated renal transplant patient. *Transplantation.* 1989; 48 : 695-697.
- 7 Tsurumi H, Tani K, Tsuruta T, *et al.* Adult T-cell leukemia developing during immunosuppressive treatment in a renal transplant recipient. *Am J Hematol.* 1992; 41 : 292-294.
- 8 Jenks PJ, Barrett WY, Raftery MJ, *et al.* Development of human T-cell lymphotropic virus type I-associated adult T-cell leukemia/lymphoma during immunosuppressive treatment following renal transplantation. *Clin Infect Dis.* 1995; 21 : 992-993.
- 9 Williams NP, Buchner LM, Shah DJ, Williams W. Adult T-cell leukemia/lymphoma in a renal transplant recipient: an opportunistic occurrence. *Am J Nephrol.* 1994; 14 : 226-229.
- 10 Mori J, Kamiryō Y, Yano S, *et al.* Adult T-cell leukemia following ABO incompatible renal transplant patients in Japan. *Renal Transplantation Vascular Surgery.* 2000; 12 : 137-141.
- 11 Yoshida Y, Ting L, Zhiming D, *et al.* lymphoproliferative disorders in renal transplant patients in Japan. *Int J Cancer.* 2001; 91 : 869-875.
- 12 Ichikawa Y, Iida M, Ebisui C, *et al.* A case study of adult T-cell lymphoma in a kidney transplant patient. *Transplant Proc.* 2000; 32 : 1982-1983.
- 13 Kawano N, Shimoda K, Ishikawa F, *et al.* Adult T-cell leukemia

- development from a human T-cell leukemia virus type 1 carrier after a living-donor liver transplantation. *Transplantation*. 2006; 82 : 840-843.
- 14 Yoshizumi T, Shirabe K, Ikegami T, *et al.* Impact of human T cell leukemia virus type 1 in living donor liver transplantation. *Am J Transplant*. 2012; 12 : 1479-1485.
  - 15 Yoshizumi T, Takada Y, Shirabe K, *et al.* Impact of human T-cell leukemia virus type 1 on living donor liver transplantation: a multi-center study in Japan. *J Hepatobiliary Pancreat Sci*. 2016; 23 : 333-341.
  - 16 Nakamura N, Tamaru S, Ohshima K, *et al.* Prognosis of HTLV-1-positive renal transplant recipients. *Transplant Proc*. 2005; 37 : 1779-1782.
  - 17 Tamaki H, Matsuoka M. Donor-derived T-cell leukemia after bone marrow transplantation. *N Engl J Med*. 2006; 354 : 1758-1759.
  - 18 Nakamizo A, Akagi Y, Amano T, *et al.* Donor-derived adult T-cell leukaemia. *Lancet*. 2011; 377 : 1124.
  - 19 Kitamura N, Nakanishi T, Yoshida Y, Higashi T, Tsukada J. HTLV-1-associated posttransplant lymphoproliferative disorder following virus transmission from recipient to donor cells. *Blood*. 2017; 130 : 84-86.
  - 20 Glowacka I, Korn K, Potthoff SA, *et al.* Delayed seroconversion and rapid onset of lymphoproliferative disease after transmission of human T-cell lymphotropic virus type 1 from a multiorgan donor. *Clin Infect Dis*. 2013; 57 : 1417-1424.
  - 21 Kawamata T, Ohno N, Sato K, *et al.* A case of post-transplant adult T-cell leukemia/lymphoma presenting myelopathy similar to but distinct from human T-cell leukemia virus type 1 (HTLV-1)-associated myelopathy. *Springerplus*. 2014; 3 : 581.
  - 22 Nagamine Y, Hayashi T, Kato Y, Horiuchi Y, Tanahashi N. Human T lymphotropic virus type-1-associated myelopathy manifesting shortly after living-donor renal transplantation. *Intern Med*. 2015; 54 : 75-78.
  - 23 Ramanan P, Deziel PJ, Norby SM, *et al.* Donor-transmitted HTLV-1-associated myelopathy in a kidney transplant recipient—case report and literature review. *Am J Transplant*. 2014; 14 : 2417-2421.
  - 24 Nakatsuji Y, Sugai F, Watanabe S, *et al.* HTLV-I-associated myelopathy manifested after renal transplantation. *J Neurol Sci*. 2000; 177 : 154-156.
  - 25 Kuroda Y, Takashima H, Yukitake M, Sakemi T. Development of HTLV-I-associated myelopathy after blood transfusion in a patient with aplastic anemia and a recipient of a renal transplant. *J Neurol Sci*. 1992; 109 : 196-199.
  - 26 Inose Y, Akiyama S, Mochizuki A, *et al.* Case report of HTLV-1 associated myelopathy (HAM) manifested after renal transplantation. *Rinsho Shinkeigaku (in Japanese)*. 2010; 50 : 241-245. (Review, Japanese.)
  - 27 Kuroki N, Kin M, Tateishi T. *Rinsho Shinkei (in Japanese)*. 2007; 48 : 222. Japanese (abstract)
  - 28 Toro C, Rodés B, Poveda E, Soriano V. Rapid development of subacute myelopathy in three organ transplant recipients after transmission of human T-cell lymphotropic virus type 1 from a single donor. *Transplantation*. 2003; 75 : 102-104.
  - 29 Zarranz Imirizaldu JJ, Gomez Esteban JC, Rouco Axpe I, *et al.* Post-transplantation HTLV-1 myelopathy in three recipients from a single donor. *J Neurol Neurosurg Psychiatry*. 2003; 74 : 1080-1084.
  - 30 Shintani Y, Napou Y, Fujii R, *et al.* One case of HAM after cadaveric renal transplantation. *Ishoku*. 2001; 36 : 286.
  - 31 Soyama A, Eguchi S, Takatsuki M, *et al.* Human T-cell leukemia virus type 1-associated myelopathy following living-donor liver transplantation. *Liver Transpl*. 2008; 14 : 647-650.
  - 32 Ozden S, Seilhean D, Gessain A, Hauw JJ, Gout O. Severe demyelinating myelopathy with low human T cell lymphotropic virus type 1 expression after transfusion in an immunosuppressed patient. *Clin Infect Dis*. 2002; 34 : 855-860.
  - 33 Narukawa N, Shiizaki K, Kitabata Y, *et al.* Plasma exchange for the treatment of human T-cell lymphotropic virus type 1 associated myelopathy. *Ther Apher*. 2001; 5 : 491-493.
  - 34 Kawano N, Kuriyama T, Yoshida S, *et al.* The impact of a humanized CCR4 antibody (Mogamulizumab) on patients with aggressive-type adult T-cell leukemia-lymphoma treated with allogeneic hematopoietic stem cell transplantation. *J Clin Exp Hematop*. 2017; 56 : 135-144.
  - 35 Nagafuji K, Miyamoto T, Eto T, *et al.* Monitoring of minimal residual disease (MRD) is useful to predict prognosis of adult patients with Ph-negative ALL: results of a prospective study (ALL MRD2002 Study). *J Hematol Oncol*. 2013; 6 : 14.
  - 36 Terasaka S, Kitada H, Okabe Y, *et al.* Living-donor kidney transplant in T-cell and B-cell flow cytometry crossmatch-positive patients. *Exp Clin Transplant*. 2014; 12:227-232.
  - 37 Nagle SJ, Reshef R, Tsai DE. Posttransplant lymphoproliferative disorder in solid organ and hematopoietic stem cell transplantation. *Clin Chest Med*. 2017; 38 : 771-783.
  - 38 Morris J, Smith C, Streicher A, *et al.* A rare presentation of isolated CNS posttransplantation lymphoproliferative disorder. *Case Rep Oncol Med*. 2017; 2017 : 7269147.
  - 39 Dotti G, Fiocchi R, Motta T, *et al.* Lymphomas occurring late after solid-organ transplantation: influence of treatment on the clinical outcome. *Transplantation*. 2002; 74 : 1095-1102.
  - 40 Caillard S, Porcher R, Provot F, *et al.* Post-transplantation lymphoproliferative disorder after kidney transplantation: report of a nationwide French registry and the development of a new prognostic score. *J Clin Oncol*. 2013; 31 : 1302-1309.
  - 41 Choquet S, Trappe R, Leblond V, *et al.* CHOP-21 for the treatment of post-transplant lymphoproliferative disorders (PTLD) following solid organ transplantation. *Haematologica*. 2007; 92 : 273-274.
  - 42 Choquet S, Oertel S, LeBlond V, *et al.* Rituximab in the management of post-transplantation lymphoproliferative disorder after solid organ transplantation: proceed with caution. *Ann Hematol*. 2007; 86 : 599-607.
  - 43 Trappe RU, Choquet S, Reinke P, *et al.* Salvage therapy for relapsed posttransplant lymphoproliferative disorders (PTLD) with a second progression of PTLD after Upfront chemotherapy: the role of single-agent rituximab. *Transplantation*. 2007; 84 : 1708-1712.
  - 44 Trappe R, Oertel S, Leblond V, *et al.* Sequential treatment with rituximab followed by CHOP chemotherapy in adult B-cell post-transplant lymphoproliferative disorder (PTLD): the prospective international multicentre phase 2 PTLD-1 trial. *Lancet Oncol*. 2012; 13 : 196-206.

- 45 Gross TG, Bucuvalas JC, Park JR, *et al.* Low-dose chemotherapy for Epstein-Barr virus-positive post-transplantation lymphoproliferative disease in children after solid organ transplantation. *J Clin Oncol.* 2005; 23 : 6481-6488.
- 46 Dierickx D, Tousseyn T, Gheysens O. How I treat posttransplant lymphoproliferative disorders. *Blood.* 2015; 126 : 2274-2283.