

Review Article

## Anaplastic Large Cell Lymphoma : A Critical Reappraisal

Stefano A. Pileri, Claudio Agostinelli, Laura Bodega,  
Rocio Orduz, Francesco Bacci, Elena Sabattini,  
Alessandro Pileri Jr, Marco Giunti, Pier Luigi Zinzani  
and Brunangelo Falini#

A revised concept of anaplastic large cell lymphoma (ALCL) on both historical and practical grounds is presented. The main histological findings are illustrated with special reference to the cytological spectrum that is characteristic of the tumor. The phenotype is described in detail. The expression of the ALK protein as well as the chromosomal abnormalities that sustain it, are discussed along with potential pathogenetic implications. The clinical features of ALCL are presented by underlying the dramatic difference in terms of response to therapy and survival between ALK-positive and ALK-negative forms. The possibility of limiting the term ALCL to systemic ALK<sup>+</sup> anaplastic tumors with T/null phenotype is considered.

**Key words** anaplastic large cell lymphoma ; peripheral T-cell lymphoma ; ALK protein ; fusion gene ; chimeric protein ; phenotype ; molecular biology ; cytogenetics ; clinics ; therapy.

Anaplastic large cell lymphoma (ALCL) represents 2-3% of all lymphoid neoplasms, according to World Health Organization (WHO) estimates<sup>1</sup>. In children, ALCL makes up to 20-30% of lymphoid neoplasms<sup>1</sup>. Originally described by Stein et al. in 1985<sup>2</sup>, categorizations of this malignancy have undergone a series of revisions, which have led to a more refined and restrictive definition of the process<sup>3</sup>.

### DEFINITION

The International Lymphoma Study Group (ILSG) first<sup>3</sup> and the WHO later<sup>1</sup> stated that the term ALCL should be applied to tumors with a T-cell or null phenotype, thus modifying the

definition originally given in 1985<sup>2</sup>. The latter reflected the way by which the neoplasm had been identified. Following the production of the Ki-1 monoclonal antibody<sup>4</sup>, Stein and co-workers validated the hypothesis that it specifically reacted with Hodgkin and Reed-Sternberg cells (HRSC) of Hodgkin's Lymphoma (HL)<sup>2</sup>. In the process, they showed that besides HRSC, the antibody stained activated normal B- and T-lymphocytes, a variety of non-Hodgkin's lymphomas, and a group of tumors that in the past had often been interpreted as metastatic undifferentiated carcinoma or malignant histiocytosis<sup>2</sup>. The latter cases consisted of very large cells with kidney-shaped nuclei, rod-shaped nucleoli, and a wide rim of deeply basophilic cytoplasm, which tended to produce a cohesive growth pattern and to diffuse through sinuses (Fig. 1 : a)<sup>5</sup>. They all expressed the Ki-1 molecule (later included in the 30<sup>th</sup> cluster of lymphoid differentiation antigens and termed CD30), but displayed variable phenotypes (B-cell, T-cell, null, or hybrid)<sup>5</sup>. Further studies revealed the presence of recurrent chromosomal abnormalities among ALCL with T/null phenotype (see below), which were never detected among B-cell

---

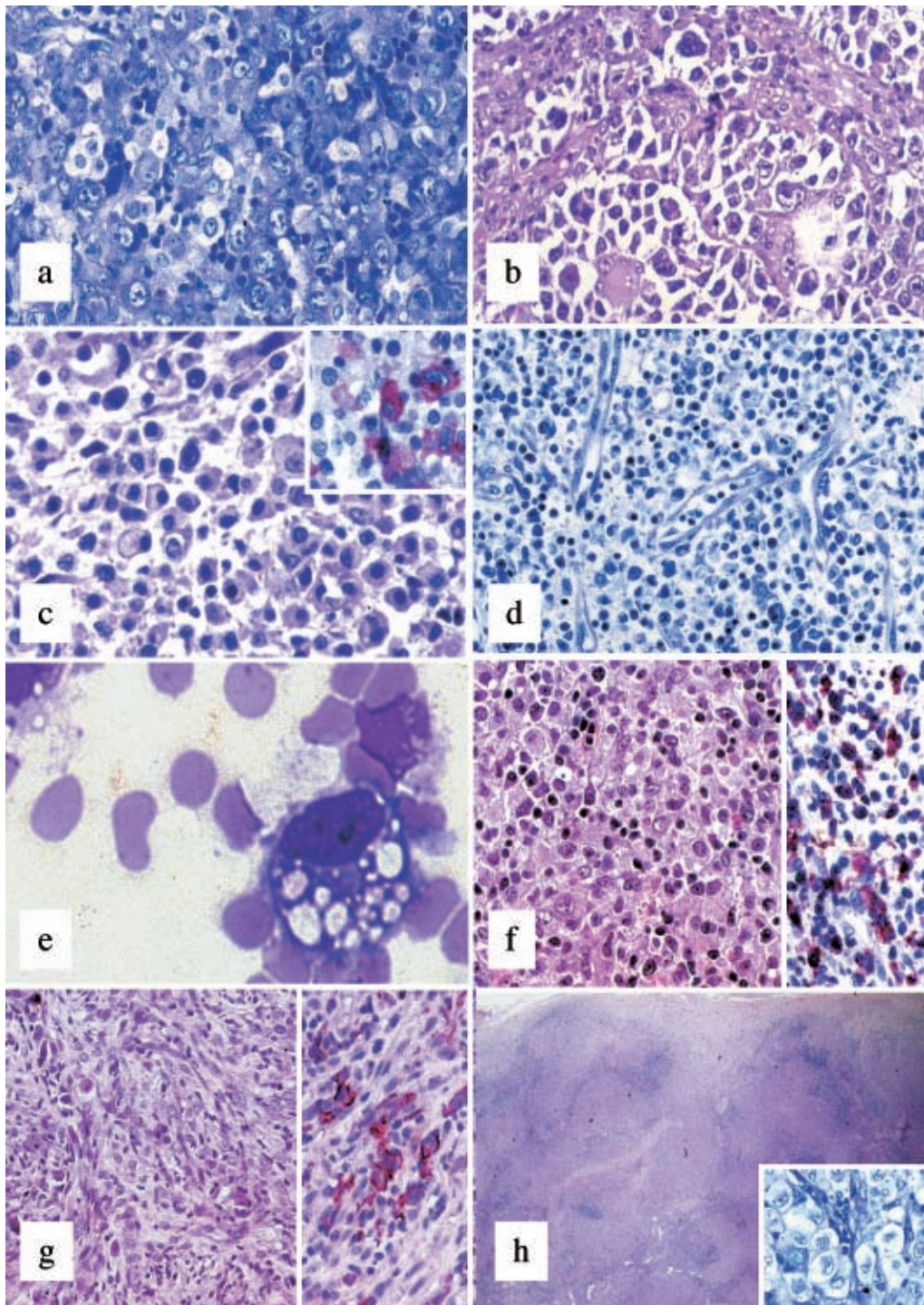
Received : Nov 9, 2004

Accepted : Nov 9, 2004

Institute of Haematology and Clinical Oncology "L. and A. Seragnoli", Bologna University School of Medicine, Via Massarenti 9, 40138 Bologna, Italy.

#Haematology and Haematopathology Lab, Perugia University School of Medicine, Policlinico Monteluce, 06100 Perugia, Italy.

Address correspondence and reprint requests to Stefano A. Pileri, Cattedra di Anatomia Patologica, Unità Operativa di Ematopatologia, Istituto di Ematologia ed Oncologia Medica "L. e A. Seragnoli", Policlinico S. Orsola, Via Massarenti 9, 40138 Bologna, Italy.



**Fig. 1.**

- a. Anaplastic large cell lymphoma, common type : Hallmark cells are shown with large size, irregular nuclear contour (kidney-shaped), prominent inclusion-like nucleoli, and a wide rim of greyish-violet cytoplasm (Giemsa,  $\times 400$ ).
- b. Anaplastic large cell lymphoma, giant-cell rich : Neoplastic elements often showing multiple nuclei diffuse through open sinuses (Hematoxylin and eosin,  $\times 300$ ).
- c. Anaplastic large cell lymphoma, lympho-histiocytic type : lymphomatous cells are comprised of a reactive population, mainly consisting of histiocytes with eccentric, pyknotic nuclei (Hematoxylin and eosin,  $\times 400$ ). Inset: Anti-CD30 staining highlights the tumor cells (Immunoalkaline phosphatase technique; Ber-H2 monoclonal antibody ; Gill's hematoxylin nuclear counterstain ;  $\times 500$ ).
- d. Anaplastic large cell lymphoma, small-cell variant : The neoplastic population is characterized by a morphologic spectrum, small element predominating over the anaplastic ones (Giemsa,  $\times 400$ ).



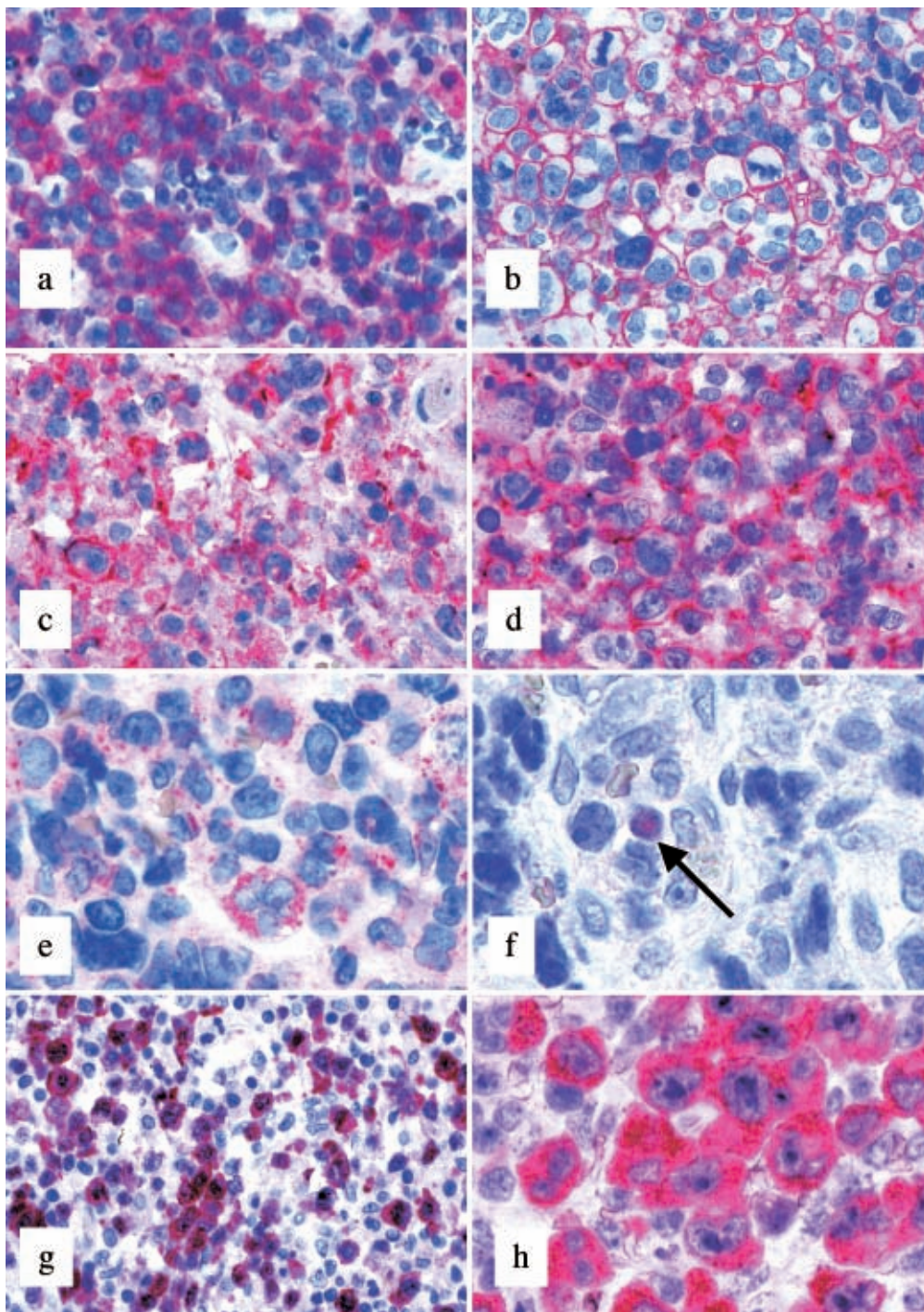
tumors, including those with an anaplastic profile<sup>6</sup>. At present, there is broad consensus that lymphomas showing anaplastic morphology, but carrying a B-cell phenotype, represent a subtype of diffuse large B-cell lymphoma (DLBCL) that do not significantly differ on clinicopathologic grounds from other tumors within this category<sup>7</sup>. In addition, most authors tend to discard the term “Ki-1 cell lymphoma”<sup>8,9</sup>, used in the late eighties as a synonym for ALCL, as it refers to a phenotypic attribute which is shared by many other lymphoid tumors (e.g. most Hodgkin’s lymphoma and some peripheral T-cell lymphomas unspecified, nodal marginal zone lymphomas, and follicular lymphomas). The Revised European-American Lymphoma (REAL) Classification<sup>3</sup> and the WHO scheme derived from it<sup>1</sup> have further refined the concept of ALCL, by limiting it to T/null-cell tumors with systemic presentation. The forms with limited cutaneous involvement have been included within the group of CD30<sup>+</sup> lymphoproliferative disorders of the skin, because of their distinctive clinical behavior<sup>10</sup>. Tumors with anaplastic morphology, but secondary to another lymphoma (e.g. Hodgkin’ lymphoma, mycosis fungoides, peripheral T-cell lymphoma), are regarded as progression of the originally diagnosed process and should not be diagnosed as ALCL<sup>1,3</sup>.

### MORPHOLOGY

With time, it has become evident that ALCL is not sustained by a unique histotype, but actually includes several morphologic variants (classical, giant cell-rich, lymphohistiocytic, small-cell type, and mixed) (Fig. 1 : a-h)<sup>6</sup>. Classical ALCL corresponds to the description of the tumor given by Stein and co-workers in 1985 (Fig. 1 : a) (see above)<sup>2</sup>. The giant cell-rich type is characterized

by several multinucleated elements, often provided with Reed-Sternberg-like features and prominent intra-sinusoidal diffusion (Fig. 1 : b)<sup>6</sup>. The small and lymphohistiocytic variants<sup>11,12</sup> display a marked variability in neoplastic cell size that ranges from small to large (Fig. 1 : c-d). The main difference between the two forms consists of a huge amount of reactive histiocytes with eccentric nuclei in the latter (Fig. 1 : c)<sup>6</sup>. Such a reactive population tends to obscure the neoplastic component (Fig. 1 : c inset) and can lead to a misdiagnosis of hyper-immune reaction<sup>12</sup>. Interestingly, transition from one histotype to another has been recorded within the same node (mixed variant) or in different nodes taken from the same patient at the time of diagnosis or at relapse. These modifications might correspond to intra-clonal modulation or differential interactions between the tumor and micro-environment<sup>13</sup>. Further variants have been reported in the literature including signet-ring cell-like, epithelioid cell-rich, sarcomatoid, and eosinophil-rich (Fig. 1 : e-g)<sup>14-17</sup>. These are very rare and may indeed represent a diagnostic challenge. Finally, the so-called ALCL of the Hodgkin-like type deserves special attention<sup>18</sup>. It was originally described as a form of the tumor, presenting in young people with a bulky mediastinal mass and consisting of anaplastic cells arranged in nodules surrounded by sclerotic bands (Fig. 1 : h), as seen in nodular sclerosing Hodgkin’s lymphoma (NSHL)<sup>19-24</sup>. Following the introduction of the REAL Classification<sup>3</sup>, which regarded it as a provisional entity, this diagnosis was by no means also applied to cases of aggressive HL that could not be easily differentiated from ALCL, both on morphologic and phenotypic grounds<sup>18</sup>. This led to a diffuse skepticism regarding the existence of such a variant. It was considered a collection of tumors that could

- e. Anaplastic large cell lymphoma, signet-ring cell type : At high power, a neoplastic cell contains numerous cytoplasmic vacuoles producing a signet-ring like appearance (Giemsa, ×1000).
- f. Anaplastic large cell lymphoma, epithelioid-cell rich : The lymphomatous population is obscured by a huge granulomatous reaction (Hematoxylin and eosin, ×400). The search for the ALK protein allows the easy identification of neoplastic cells (Immunoalkaline phosphatase technique ; ALK<sub>c</sub> monoclonal antibody ; Gill’s hematoxylin nuclear counterstain ; ×400).
- g. Anaplastic large cell lymphoma, sarcomatous variant : the growth displays a storiform pattern (Hematoxylin and eosin, ×250). The anti-CD30 antibody reacts with lymphomatous elements, at times provided with fusiform shape (Immunoalkaline phosphatase technique ; Ber-H2 monoclonal antibody ; Gill’s hematoxylin nuclear counterstain ; ×400).
- h. Anaplastic large cell lymphoma, Hodgkin’s-like : Nodules of cohesive large anaplastic cells (Inset ; Giemsa, ×400) are surrounded by thick collagen bands originating from the lymph node capsule (Hematoxylin and eosin, ×25).



**Fig. 2.**

- a. Anaplastic large cell lymphoma, common type: CD30 is strongly expressed, mainly at the cytoplasmic membrane level (Immunoalkaline phosphatase technique; Ber-H2 monoclonal antibody; Gill's hematoxylin nuclear counterstain;  $\times 400$ ).
- b. Anaplastic large cell lymphoma, common type: EMA-positivity (Immunoalkaline phosphatase technique; E29 monoclonal antibody; Gill's hematoxylin nuclear counterstain;  $\times 500$ ).
- c. Anaplastic large cell lymphoma, common type: Neoplastic cells express CD3 both at the membrane and cytoplasmic level (Immunoalkaline phosphatase technique; anti-CD3 polyclonal antibody; Gill's hematoxylin nuclear counterstain;  $\times 400$ ).
- d. Anaplastic large cell lymphoma, common type: in the same case, CD2 positivity (Immunoalkaline phosphatase technique; AB75 monoclonal antibody; Gill's hematoxylin nuclear counterstain;  $\times 400$ ).



not be classified rather than as a specific entity and was thus not listed in the WHO scheme. In reality, *bona fide* examples of ALCL of the Hodgkin's-like type have been described. These are characterized by ALK protein-expression, homogeneous CD30-positivity, lack of CD15 and B-cell activator protein (BSAP), possible T-cell antigen expression, and variable positivity for the leukocyte common antigen/CD45 and epithelial membrane antigen (EMA)<sup>18,25</sup>.

## PHENOTYPE

Neoplastic ALCL cells carry a distinctive phenotypic profile irrespective of the histotype<sup>18</sup>. Notably, they regularly express CD30 (Fig. 2: a)<sup>18</sup>. This molecule is a 120 kD glycoprotein expressed by lymphoid elements following activation and formed by three distinct domains (intracytoplasmic, transmembranic, and external)<sup>26,27</sup>. It is encoded by a gene located at chromosome 1p36, whose activity is modulated by the number of ATCC-repeats in the 5' region of the promoter, and represents a member of the tumor necrosis factor (TNF) receptor superfamily<sup>28</sup>. Recently, CD30 overexpression has been reported to induce constitutive NF- $\kappa$ B activation<sup>29</sup>. As expected, the CD30 ligand (CD30L) belongs to a group of molecules, which show homology with TNF<sup>28</sup>. The external domain of CD30 is steadily cleaved by a metalloproteinase so that it can be detected and measured in the serum<sup>30</sup>. Immunohistochemical analysis of paraffin and frozen sections using antibodies against CD30 produce different patterns of positivity including membrane-bound, dot-like in the Golgi area (corresponding to accumulation of the 90 kD precursor), and diffuse<sup>31</sup>. The first two patterns are exclusive of lymphoid elements with the exception of embryonic carcinoma<sup>32,33</sup>, while the third can occur in a variety of malignant tumors other

than lymphomas, including pancreatic carcinoma, nasopharyngeal undifferentiated carcinoma, mesothelioma, and malignant melanoma<sup>33</sup>. Therefore, the immunophenotypic diagnosis of ALCL should always be based on the application of a panel of antibodies, including anti-cytokeratins, melanoma-associated antigens, CEA, and PLAP<sup>33</sup>. In 60–70% of cases, ALCL expresses the epithelial membrane antigen<sup>34</sup>, which is more easily detected in Bouin-fixed samples (Fig. 1: b). CD3 expression is appreciated in about half of cases (Fig. 1: c) and usually occurs at the cytoplasmic level as expected in activated cells<sup>35</sup>. All T-cell associated antigens should be assayed, as CD3 negative tumors may express CD2, CD5, and/or CD7 (Fig. 1: d)<sup>1</sup>. The expression of CD4 and CD8 is variable<sup>1</sup>. Positivity for TIA-1, granzyme B, and perforin is recorded in about 85% of instances (Fig. 1: e)<sup>36</sup>. NK-antigens have at times been detected, both in spontaneous and experimental tumors<sup>37</sup>. About 20% of ALCLs lack CD45 and/or express CD15<sup>38,39</sup>. Notably, BSAP (the PAX5 gene product) expression is absent (Fig. 1: f)<sup>40</sup>, making it useful for differentiating ALCL from common HL and DLBCL, which are both BSAP-positive<sup>40</sup>. The recent development of antibodies against the anaplastic large cell lymphoma kinase (ALK) has further refined the immunohistochemical analysis of ALCL<sup>6,18,25,41–43</sup>. In fact, expression of this molecule characteristically occurs in cases carrying translocations that involve the corresponding gene (see below)<sup>6</sup>. In principle, the most common t(2; 5) causes strong positivity of neoplastic cells at the cytoplasmic and nuclear levels (Fig. 1: g), while the other translocations produce accumulation of the protein in the cytoplasm (Fig. 1: h). These different staining patterns correspond to overexpression of the *ALK* gene product and bear diagnostic relevance, since ALK is not detected in normal

- e. Anaplastic large cell lymphoma, giant-cell rich: lymphomatous elements express TIA-1 (Immunoalkaline phosphatase technique; 24 monoclonal antibody; Gill's hematoxylin nuclear counterstain;  $\times 500$ ).
- f. Anaplastic large cell lymphoma, common type: Neoplastic cells lack BSAP expression; please note an internal central control (arrowed) (Immunoalkaline phosphatase technique; 2-G9 monoclonal antibody; Gill's hematoxylin nuclear counterstain;  $\times 600$ ).
- g. Anaplastic large cell lymphoma, lympho-histiocytic type, carrying t(2; 5): Small and large neoplastic cells express ALK protein at the nuclear and cytoplasmic and nuclear level, respectively (Immunoalkaline phosphatase technique; ALK<sub>c</sub> monoclonal antibody; Gill's hematoxylin nuclear counterstain;  $\times 250$ ).
- h. Anaplastic large cell lymphoma, common type, carrying a variant translocation: Lymphomatous elements reveal a strong cytoplasmic ALK protein positivity (Immunoalkaline phosphatase technique; ALK<sub>c</sub> monoclonal antibody; Gill's hematoxylin nuclear counterstain;  $\times 500$ ).

lymphocytes or in HL<sup>6,25,44,45</sup>. Recently, this kinase has been identified in some lymphoid and non-lymphoid neoplasms that have nothing in common with ALCL<sup>46-50</sup>. In particular, it can be detected, more often at the cytoplasmic level, in B-plasmablastic lymphomas bearing a distinctive phenotype (ALK<sup>+</sup>, CD138<sup>+</sup>, EMA<sup>+</sup>, IgA<sup>+/-</sup>, Bcl-2 protein<sup>+/-</sup>, CD4<sup>-/+</sup>, CD57<sup>-/+</sup>, CD20<sup>-</sup>, CD3<sup>-</sup>, and CD30<sup>-</sup>). Like ALCL, these tumors also carry cytogenetic abnormalities involving the *ALK* gene<sup>50</sup>. Interestingly, ALK protein is never detected in anaplastic lymphoid tumors confined to the skin, thus further legitimizing their exclusion from the ALCL body<sup>1</sup>. Among non-hematopoietic neoplasms, ALK positivity is found in inflammatory myofibroblastic tumors (IMT) as well as some neuroblastomas and rhabdomyosarcomas<sup>46,47,51</sup>. Recently, ALK has been shown to have immunogenic properties, causing the production of antibodies that can be easily detected in the serum which might be relevant to the relatively good prognosis of ALK<sup>+</sup> ALCL<sup>52</sup>. These immunogenic properties should be taken into account for two additional reasons: 1) they might be employed for vaccination strategies<sup>53</sup> and 2) might cause extensive tumor destruction, hypocellularity, and edema of the affected nodes, thus mimicking an inflammatory lesion<sup>54</sup>. Notably, ALK expression is felt to play a relevant role in the process of lymphomagenesis, as suggested by experimental data<sup>55</sup>. In this respect, experimental and *in vivo* studies have provided evidence that the chimeric protein NPM/ALK, produced by t(2; 5), causes profound dysregulation of cell kinetics. In fact, it mediates phosphorylation of JAK3 with consequent STAT3 activation, and the latter induces expression of TIMP1 and Bcl-X<sub>L</sub> that in turn lead to increased activated caspase-3 levels and activation of the anti-apoptotic pathway<sup>56-58</sup>. Within this context, one should keep in mind that NPM/ALK causes *BCL-3* overexpression with consequent production of a nuclear protein belonging to the I kappa B family of inhibitors of the nuclear factor-kappa B (NF- $\kappa$ B) transcription factors<sup>59,60</sup>. In other words, ALCL with t(2; 5) behaves unlike HL with constitutional NF- $\kappa$ B activation<sup>29,61</sup>. In addition, the NPM/ALK chimeric protein facilitates proliferation via activation of a series of factors, including PLC- $\gamma$ , type IA phosphoinositide 3-kinase, Src-kinases, AKT, and FOXO3a<sup>62,63</sup>. Interestingly, the above mentioned alterations are not

observed to the same extent in ALK-negative ALCLs, a fact that further emphasizes the need to definitively clarify whether ALK-positive and negative cases should be grouped together<sup>64,65</sup>. In line with this, the differential expression of the lymphocyte specific protein (LSP1) is detected in all ALK<sup>+</sup> ALCLs but only 25% of ALK<sup>-</sup> ALCLs<sup>66</sup>. Expression of retinoblastoma protein, survivin, and MUC-1 highly glycosylated transmembrane protein can occur in both ALK<sup>+</sup> and ALK<sup>-</sup> ALCLs, in either case representing independent unfavorable prognostic indicators<sup>67-70</sup>. Finally, the assay for Epstein-Barr virus (EBV) is negative in most if not all ALCLs both by *in situ* hybridization (ISH) and immunohistochemistry. Such negativity is regarded as one of the distinguishing features between ALCL and HL in unclear cases<sup>71</sup>. Recently, however, rare cases of ALK<sup>+</sup> ALCLs showing EBV integration in their genome have been reported in patients with a previous history of solid organ transplant<sup>72</sup>.

## MOLECULAR AND CYTOGENETIC FINDINGS

The t(2; 5) (p23; q35) was originally described in patients with malignant histiocytosis (MH)<sup>73,74</sup>. These actually represent ALCL cases diagnosed according to dated criteria. In fact, it soon became evident that this translocation characteristically occurred in ALCL<sup>75,76</sup>. At the beginning, the real incidence of this phenomenon was uncertain. The need for fresh or frozen material for cytogenetic studies or Southern blot analysis prevented a systematic analysis<sup>77</sup>. This aberration produced a hybrid gene, formed by the segment of the *ALK* gene encoding the transmembrane portion of the corresponding kinase and the NH<sub>2</sub>-terminal region of the *NPM* gene<sup>78</sup>. Under physiologic conditions, the latter encodes nucleophosmin, a shuttle-protein that undergoes dimerization in the cytoplasm and subsequently moves to the nucleus<sup>18,25,79</sup>. Due to the production of highly specific (polyclonal and monoclonal) antibodies raised against the transmembranic portion of the ALK protein, as well as the NH<sub>2</sub>- and COOH-terminal regions of NPM, the identification of the chimeric NPM/ALK protein (also termed p80 because of its molecular weight) became easily feasible in routine samples (formalin-fixed, paraffin-embedded)<sup>6,42,80,81</sup>. This allowed the determination that a large majority of cases diagnosed as ALCL according to the

REAL/WHO Classification do carry t(2; 5). The staining produced by the anti-ALK antibodies is typically cytoplasmic and nuclear, because the NPM/ALK protein forms heterodimers with normal NPM which, like normal NPM homodimers, is shuttled to the nucleus<sup>82</sup>. Unexpectedly, the broad application of monoclonal antibodies to ALK1 and ALK<sub>c</sub> revealed that about 10% of ALK-positive ALCLs showed an immunohistochemical reactivity confined to the cytoplasm. This was concomitant with the detection of a series of additional translocations (commonly called variant translocations), all involving the *ALK* gene, leading to the formation of a chimeric gene with partners other than *NPM*<sup>45</sup>. The derived hybrid proteins, all cause ALK over-expression and more often under oligomerization, but have no shuttling properties, and thus remain confined to the cytoplasm<sup>45</sup>. The most relevant of these variant translocations are the following:

t(1; 2) (q25; p23), producing the fusion gene and chimeric protein TMP3/ALK;  
 inv(2), producing the hybrid gene and chimeric protein ATIC/ALK;  
 t(2; 3) (p23; q21), producing the fusion gene and chimeric protein TGF/ALK;  
 t(2; 11; 2) (p23; p15; q31), producing the hybrid gene and chimeric protein CARS/ALK;  
 t(2; 17) (p23; q23), producing the fusion gene and chimeric protein CLTL/ALK;  
 t(2; 17) (p23; q25), producing the hybrid gene and chimeric protein ALO17/ALK;  
 t(2; 19) (p23; p13), producing the fusion gene and chimeric protein TPM4/ALK;  
 t(2; 22) (p23; q11.2), producing the formation of the hybrid gene and chimeric protein MYH9/ALK;  
 t(2; X) (p23; q11-12), producing the fusion gene and chimeric protein MSN/ALK.

Interestingly, t(2; 17) (p23; q23) is also observed in B-plasmablastic lymphoma as well as in IMT<sup>48</sup>, while t(1; 2) (q25; p23), t(2; 19) (p23; p13), and t(2; 11; 2) (p23; p15; q31) are detected more frequently in IMT than in ALCL<sup>83</sup>. With the exception of two studies, which could not be reproduced in other labs<sup>84,85</sup>, neither ALK protein detection (see above) nor t(2; 5) or variant translocations have been detected in HL<sup>6,25,80,86-89</sup>.

## CLINICAL BEHAVIOR

ALCL displays a rather different course depending on the expression of the ALK protein<sup>6,18,25,43,45,64,65</sup>. In particular, several studies have shown that about 90% of ALK<sup>+</sup> ALCLs achieve complete remission (CR) with anthracyclin-containing regimens. Follow-up studies revealed that most patients are actually cured. In contrast, no more than 35% of ALK<sup>-</sup> cases obtain stable CR by the same therapies<sup>6,25,45,64,65</sup>, suggesting that more aggressive strategies including autologous or allogeneic bone-marrow/stem cell transplantation should be adopted. This is not the only significant clinical difference between ALK-positive and negative ALCLs. In fact, the former most frequently occur among patients in the first or second decade of life, while the latter are usually recorded among people aged 50-70<sup>64</sup>. According to a recent report, leukemic spread seems to represent the only exception to the favorable prognosis of ALK<sup>+</sup> ALCL<sup>90</sup>. Based on these findings, ten Berge et al. have recently suggested that the distinction between ALK-negative ALCL and prognosis of peripheral T-cell lymphoma, unspecified (PTCL/U) is of limited clinical relevance, with only age and the International Prognostic Index (IPI) being prognostically significant for these tumors<sup>64</sup>. As to the latter parameter, one should remember that it also has a prognostic impact within the ALK-positive ALCL group. In fact, the 5 year-overall survival is 94% and 41% for the cases with low/low-intermediate and high/intermediate-high IPI, respectively<sup>45</sup>. On the occasion of the next revision of the REAL/WHO Classification, scheduled for mid 2006, this might lead to limitation of the term ALCL only to ALK-positive cases, which actually represent a group of homogeneous neoplasms in terms of clinical behaviors, phenotype, molecular characteristics, and pathogenesis.

## REFERENCES

- 1 Jaffe ES, Stein H, Vardiman JW: Tumours of hematopoietic and lymphoid tissues. Lyon, International Agency for Research on Cancer Press, pp 230-235, 2001.
- 2 Stein H, Mason DY, Gerdes J, O'Connor N, Wainscoat J, Pallesen G, Gatter K, Falini B, Delsol G, Lemke H, Schwarting R, Lennert K:

- The expression of the Hodgkin's disease associated antigen Ki-1 in reactive and neoplastic lymphoid tissue: evidence that Reed-Sternberg cells and histiocytic malignancies are derived from activated lymphoid cells. *Blood* 66: 848-858, 1985.
- 3 Harris NL, Jaffe ES, Stein H, Banks PM, Chan JK, Cleary ML, Delsol G, De Wolf-Peeters C, Falini B, Gatter KC. A revised European-American classification of lymphoid neoplasms: a proposal from the International Lymphoma Study Group. *Blood* 84: 1361-1392, 1994.
  - 4 Schwab U, Stein H, Gerdes J, Lemke H, Kirchner H, Schaadt M, Diehl V: Production of a monoclonal antibody specific for Hodgkin and Sternberg-Reed cells of Hodgkin's disease and a subset of normal lymphoid cells. *Nature* 299: 65-67, 1992.
  - 5 Chan JK, Ng CS, Hui PK, Leung TW, Lo ES, Lau WH, McGuire LJ: Anaplastic large cell Ki-1 lymphoma. Delineation of two morphological types. *Histopathology* 15: 11-34, 1989.
  - 6 Falini B, Bigerna B, Fizzotti M, Pulford K, Pileri SA, Delsol G, Carbone A, Paulli M, Magrini U, Menestrina F, Giardini R, Pilotti S, Mezzelani A, Ugolini B, Billi M, Pucciarini A, Pacini R, Pelicci PG, Flenghi L: ALK expression defines a distinct group of T/null lymphomas ("ALK lymphomas") with a wide morphological spectrum. *Am J Pathol* 153: 875-886, 1998.
  - 7 Haralambieva E, Pulford KAF, Lamant L, Pileri S, Roncador G, Gatter KC, Delsol G, Mason D Y: Anaplastic large-cell lymphomas of B-cell phenotype are anaplastic lymphoma kinase (ALK) negative and belong to the spectrum of diffuse large B-cell lymphomas. *Br J Haematol* 109: 584-591, 2000
  - 8 Kadin ME: Ki-1-positive anaplastic large-cell lymphoma: a clinicopathologic entity? *J Clin Oncol* 9: 533-536, 1991
  - 9 Kadin ME: Ki-1/CD30+ (anaplastic) large-cell lymphoma: maturation of a clinicopathologic entity with prospects of effective therapy. *J Clin Oncol* 12: 884-887, 1994
  - 10 Willemze R, Kerl H, Sterry W, Berti E, Cerroni L, Chimenti S, Diaz-Perez JL, Geerts ML, Goos M, Knobler R, Ralfkiaer E, Santucci M, Smith N, Wechsler J., van Vloten W A, Meijer CJLM: EORTC classification for primary cutaneous lymphomas: a proposal from the Cutaneous Lymphoma Study Group of the European Organization for Research and Treatment of Cancer. *Blood* 90: 354-371, 1997
  - 11 Kinney MC, Kadin ME: The pathologic and clinical spectrum of anaplastic large cell lymphoma and correlation with ALK gene dysregulation. *Am J Clin Pathol* 111: S56-67, 1999
  - 12 Pileri S, Falini B, Delsol G, Stein H, Baglioni P, Poggi S, Martelli MF, Rivano MT, Mason DY, Stansfeld AG: Lymphohistiocytic T-cell lymphoma (anaplastic large cell lymphoma CD30+/Ki-1+ with a high content of reactive histiocytes). *Histopathology* 16: 383-391, 1990
  - 13 Hodges KB, Collins RD, Greer JP, Kadin ME, Kinney MC: Transformation of the small cell variant Ki-1+ lymphoma to anaplastic large cell lymphoma: pathologic and clinical features. *Am J Surg Pathol* 23: 49-58, 1999
  - 14 Falini B, Liso A, Pasqualucci L, Flenghi L, Ascani S, Pileri S, Bucciarelli E: CD30+ anaplastic large-cell lymphoma, null type, with signet-ring appearance. *Histopathology* 30: 90-92, 1997
  - 15 Suzuki R, Seto M, Nakamura S, Nakagawa A, Hara K, Takeuchi K: Sarcomatoid variant of anaplastic large cell lymphoma with cytoplasmic ALK and alpha-smooth muscle actin expression: a mimic of inflammatory myofibroblastic tumor. *Am J Pathol* 159: 383-384, 2001
  - 16 Piccaluga PP, Ascani S, Fraternali OG, Piccioli M, Pileri JA, Falini B, Pileri S: Anaplastic lymphoma kinase expression as a marker of malignancy. Application to a case of anaplastic large cell lymphoma with huge granulomatous reaction. *Haematologica* 85: 978-981, 2000
  - 17 McCluggage WG, Walsh MY, Bharucha H: Anaplastic large cell malignant lymphoma with extensive eosinophilic or neutrophilic infiltration. *Histopathology* 32: 110-115, 1998
  - 18 Stein H, Foss HD, Durkop H, Marafioti T, Delsol G, Pulford K, Pileri S, Falini B: CD30(+) anaplastic large cell lymphoma: a review of its histopathologic, genetic, and clinical features. *Blood* 96: 3681-3695, 2000
  - 19 Pileri S, Bocchia M, Baroni CD, Martelli M, Falini B, Sabattini E, Gherlinzoni F, Amadori S, Poggi S, Mazza P, Burgio V, Zinzani PL, Melilli G, Benni M, Saragoni L, Martelli MF, Stein H, Mandelli F, Tura S: Anaplastic large cell lymphoma (CD30+/Ki-1+): results of a prospective clinico-pathological study of 69 cases. *Br J Haematol* 86: 513-523, 1994
  - 20 Pileri S: Controversies on Hodgkin's disease and anaplastic large cell lymphoma. Hematopathology Study Group of the Societa Italiana di Anatomia Patologica. *Haematologica* 79: 299-310, 1994
  - 21 Stein H: Ki-1-anaplastic large cell lymphoma:



- is it a discrete entity? *Leuk Lymphoma* 10 Suppl: 81-84, 1993
- 22 Pileri SA, Piccaluga A, Poggi S, Sabbatini E, Piccaluga PP, De Vivo A, Falini B, Stein H: Anaplastic large cell lymphoma: update of findings. *Leuk Lymphoma* 18: 17-25, 1995
  - 23 Pileri SA, Milani M, Ascani S, Fraternali-Orcioni G, Piccioli M, Poggi S, Sabbatini E, Falini B: Anaplastic large cell lymphoma: a concept reviewed. *Adv Clin Path* 2: 285-296, 1998
  - 24 Chittal SM, Delsol G: The interface of Hodgkin's disease and anaplastic large cell lymphoma. *Cancer Surv* 30: 87-105, 1997
  - 25 Falini B: Anaplastic large cell lymphoma: pathological, molecular and clinical features. *Br J Haematol* 114: 741-760, 2001
  - 26 Froese P, Lemke H, Gerdes J, Havsteen B, Schwarting R, Hansen H, Stein H: Biochemical characterization and biosynthesis of the Ki-1 antigen in Hodgkin-derived and virus-transformed human B and T lymphoid cell lines. *J Immunol* 139: 2081-2087, 1987
  - 27 Durkop H, Latza U, Hummel M, Eitelbach F, Seed B, Stein H: Molecular cloning and expression of a new member of the nerve growth factor receptor family that is characteristic for Hodgkin's disease. *Cell* 68: 421-427, 1992
  - 28 Smith CA, Gruss HJ, Davis T, Anderson D, Farrah T, Baker E, Sutherland GR, Brannan CI, Copeland NG, Jenkins NA, Grabstein KH, Gliniak B, McAlister IB, Fanslow W, Alderson M, Falk B, Gimpel S, Gillis S, Din WS, Goodwin RG, Armitage RJ: CD30 antigen, a marker for Hodgkin's lymphoma, is a receptor whose ligand defines an emerging family of cytokines with homology to TNF. *Cell* 73: 1349-1360, 1993
  - 29 Horie R, Watanabe T, Morishita Y, Ito K, Ishida T, Kanegae Y, Saito I, Higashihara M, Mori S, Kadin ME, Watanabe T: Ligand-independent signaling by overexpressed CD30 drives NF-kappaB activation in Hodgkin-Reed-Sternberg cells. *Oncogene* 21: 2493-2503, 2002
  - 30 Nadali G, Vinante F, Stein H, Todeschini G, Tecchio C, Morosato L, Chilosi M, Menestrina F, Kinney MC, Greer JP: Serum levels of the soluble form of CD30 molecule as a tumor marker in CD30+ anaplastic large-cell lymphoma. *J Clin Oncol* 13: 1355-1360, 1995
  - 31 Schwarting R, Gerdes J, Durkop H, Falini B, Pileri S, Stein H: BER-H2: a new anti-Ki-1 (CD30) monoclonal antibody directed at a formol-resistant epitope. *Blood* 74: 1678-1689, 1989
  - 32 Pallesen G, Hamilton-Dutoit SJ: Ki-1 (CD30) antigen is regularly expressed by tumor cells of embryonal carcinoma. *Am J Pathol* 133: 446-450, 1988
  - 33 Falini B, Pileri S, Pizzolo G, Durkop H, Flenghi L, Stirpe F, Martelli MF, Stein H: CD30 (Ki-1) molecule: a new cytokine receptor of the tumor necrosis factor receptor superfamily as a tool for diagnosis and immunotherapy. *Blood* 85: 1-14, 1995
  - 34 Delsol G, Al Saati T, Gatter KC, Gerdes J, Schwarting R, Caveriviere P, Rigal-Huguet F, Robert A, Stein H, Mason DY: Coexpression of epithelial membrane antigen (EMA), Ki-1, and interleukin-2 receptor by anaplastic large cell lymphomas. Diagnostic value in so-called malignant histiocytosis. *Am J Pathol* 130: 59-70, 1988
  - 35 Saito TYT: CD3 workshop panel report. In Kishimoto T KH, von dem Borne AEGK et al. (eds): *Leukocyte typing VI: white cell differentiation antigens*. New York, 1998, pp 46-48
  - 36 Foss HD, Anagnostopoulos I, Araujo I, Assaf C, Demel G, Kummer JA, Hummel M, Stein H: Anaplastic large-cell lymphomas of T-cell and null-cell phenotype express cytotoxic molecules. *Blood* 88: 4005-4011, 1996
  - 37 Felgar RE, Salhany KE, Macon WR, Pietra GG, Kinney MC: The expression of TIA-1+ cytolytic-type granules and other cytolytic lymphocyte-associated markers in CD30+ anaplastic large cell lymphomas (ALCL): correlation with morphology, immunophenotype, ultrastructure, and clinical features. *Hum Pathol* 30: 228-236, 1999
  - 38 Falini B, Pileri S, Stein H, Dieneman D, Dallenbach F, Delsol G, Minelli O, Poggi S, Martelli MF, Pallesen G, Palestro G: Variable expression of leucocyte-common (CD45) antigen in CD30 (Ki1)-positive anaplastic large-cell lymphoma: implications for the differential diagnosis between lymphoid and nonlymphoid malignancies. *Hum Pathol* 21: 624-629, 1990
  - 39 Rosso R, Paulli M, Magrini U, Kindl S, Boveri E, Volpato G, Poggi S, Baglioni P, Pileri S: Anaplastic large cell lymphoma, CD30/Ki-1 positive, expressing the CD15/Leu-M1 antigen. Immunohistochemical and morphological relationships to Hodgkin's disease. *Virchows Arch A Pathol Anat Histopathol* 416: 229-235, 1990
  - 40 Browne P, Petrosyan K, Hernandez A, Chan JA: The B-cell transcription factors BSAP, Oct-2, and BOB. 1 and the pan-B-cell markers CD20, CD22, and CD79a are useful in the differential diagnosis of classic Hodgkin lymphoma. *Am J Clin Pathol* 120: 767-777, 2003
  - 41 Pittaluga S, Wiodarska I, Pulford K, Campo E,

- Morris SW, Van den Berghe H, Wolf-Peters C: The monoclonal antibody ALK1 identifies a distinct morphological subtype of anaplastic large cell lymphoma associated with 2p23/ALK rearrangements. *Am J Pathol* 151: 343-351, 1997
- 42 Shiota M, Fujimoto J, Takenaga M, Satoh H, Ichinohasama R, Abe M, Nakano M, Yamamoto T, Mori S: Diagnosis of t(2; 5) (p23; q35)-associated Ki-1 lymphoma with immunohistochemistry. *Blood* 84: 3648-3652, 1994
- 43 Benharroch D, Meguerian-Bedoyan Z, Lamant L, Amin C, Brugières L, Terrier-Lacombe MJ, Haralambieva E, Pulford K, Pileri S, Morris SW, Mason DY, Delsol G: ALK-positive lymphoma: a single disease with a broad spectrum of morphology. *Blood* 91: 2076-2084, 1998
- 44 Nakamura S, Shiota M, Nakagawa A, Yatabe Y, Kojima M, Motoori T, Suzuki R, Kagami Y, Ogura M, Morishima Y, Mizoguchi Y, Okamoto M, Seto M, Koshikawa T, Mori S, Suchi T: Anaplastic large cell lymphoma: a distinct molecular pathologic entity: a reappraisal with special reference to p80(NPM/ALK) expression. *Am J Surg Pathol* 21: 1420-1432, 1997
- 45 Falini B, Pulford K, Pucciarini A, Carbone A, Wolf-Peters C, Cordell J, Fizzotti M, Santucci A, Pelicci PG, Pileri S, Campo E, Ott G, Delsol G, Mason DY: Lymphomas expressing ALK fusion protein(s) other than NPM-ALK. *Blood* 94: 3509-3515, 1999
- 46 Pulford K, Morris SW, Mason DY: Anaplastic lymphoma kinase proteins and malignancy. *Curr Opin Hematol* 8: 231-236, 2001
- 47 Cook JR, Dehner LP, Collins MH, Ma Z, Morris SW, Coffin CM, Hill DA: Anaplastic lymphoma kinase (ALK) expression in the inflammatory myofibroblastic tumor: a comparative immunohistochemical study. *Am J Surg Pathol* 25: 1364-1371, 2001
- 48 Chikatsu N, Kojima H, Suzukawa K, Shinagawa A, Nagasawa T, Ozawa H, Yamashita Y, Mori N: ALK+, CD30-, CD20- large B-cell lymphoma containing anaplastic lymphoma kinase (ALK) fused to clathrin heavy chain gene (CLTC). *Mod Pathol* 16: 828-832, 2003
- 49 Gascoyne RD, Lamant L, Martin-Subero JI, Lestou VS, Harris NL, Müller-Hermelink HK, Seymour JF, Campbell LJ, Horsman DE, Auvigne I, Espinos E, Siebert R, Delsol G: ALK-positive diffuse large B-cell lymphoma is associated with Clathrin-ALK rearrangements: report of 6 cases. *Blood* 102: 2568-2573, 2003
- 50 Adam P, Katzenberger T, Seeberger H, Gattenlohner S, Wolf J, Steinlein C, Schmid M, Müller-Hermelink HK, Ott G: A case of a diffuse large B-cell lymphoma of plasmablastic type associated with the t(2; 5) (p23; q35) chromosome translocation. *Am J Surg Pathol* 27: 1473-1476, 2003
- 51 Debelenko LV, Arthur DC, Pack SD, Helman LJ, Schrupp DS, Tsokos M: Identification of CARS-ALK fusion in primary and metastatic lesions of an inflammatory myofibroblastic tumor. *Lab Invest* 83: 1255-1265, 2003
- 52 Pulford K, Falini B, Banham AH, Codrington D, Robertson H, Hatton C, Mason DY: Immune response to the ALK oncogenic tyrosine kinase in patients with anaplastic large-cell lymphoma. *Blood* 96: 1605-1607, 2000
- 53 Passoni L, Gambacorti-Passerini C: ALK a novel lymphoma-associated tumor antigen for vaccination strategies. *Leuk Lymphoma* 44: 1675-1681, 2003
- 54 Borisch B, Yerly S, Cerato C, Schwaller J, Wacker P, Ozsahin AH, Brousse N, Hoessli DC: ALK-positive anaplastic large-cell lymphoma: strong T and B anti-tumor responses may cause hypocellular aspects of lymph nodes mimicking inflammatory lesions. *Eur J Haematol* 71: 243-249, 2003
- 55 Chiarle R, Gong JZ, Guasparri I, Pesci A, Cai J, Liu J, Simmons WJ, Dhall G, Howes J, Piva R, Inghirami G: NPM-ALK transgenic mice spontaneously develop T-cell lymphomas and plasma cell tumors. *Blood* 101: 1919-1927, 2003
- 56 Coluccia AML, Perego S, Cleris L, Gunby RH, Passoni L, Marchesi E, Formelli F, Gambacorti-Passerini C: Bcl-XL down-regulation suppresses the tumorigenic potential of NPM/ALK in vitro and in vivo. *Blood* 103: 2787-2794, 2004
- 57 Amin HM, Medeiros LJ, Ma Y, Feretzaki M, Das P, Leventaki V, Rassidakis GZ, O'Connor SL, McDonnell TJ, Lai R: Inhibition of JAK3 induces apoptosis and decreases anaplastic lymphoma kinase activity in anaplastic large cell lymphoma. *Oncogene* 22: 5399-5407, 2003
- 58 Drakos E, Rassidakis GZ, Lai R, Herling M, O'Connor SL, Schmitt-Graeff A, McDonnell TJ, Medeiros LJ: Caspase-3 activation in systemic anaplastic large-cell lymphoma. *Mod Pathol* 17: 109-116, 2004
- 59 Nishikori M, Maesako Y, Ueda C, Kurata M, Uchiyama T, Ohno H: High-level expression of BCL3 differentiates t(2; 5) (p23; q35)-positive anaplastic large cell lymphoma from Hodgkin disease. *Blood* 101: 2789-2796, 2003
- 60 Rassidakis GZ, Oyarzo MP, Medeiros LJ: BCL3 overexpression in anaplastic lymphoma kinase-positive anaplastic large cell lymphoma. *Blood* 102: 1146-1147, 2003
- 61 Emmerich F, Theurich S, Hummel M, Haeffker

- A, Vry MS, Döhner K, Bommert K, Stein H, Dörken B: Inactivating I kappa B epsilon mutations in Hodgkin/Reed-Sternberg cells. *J Pathol* 201: 413-420, 2003
- 62 Gu TL, Tothova Z, Scheijen B, Griffin JD, Gilliland DG, Sternberg DW: NPM-ALK fusion kinase of anaplastic large-cell lymphoma regulates survival and proliferative signaling through modulation of FOXO3a. *Blood* 103: 4622-4629, 2004
- 63 Cussac D, Greenland C, Roche S, Bai RY, Duyster J, Morris SW, Delsol G, Allouche M, Payrastre B: Nucleophosmin-anaplastic lymphoma kinase of anaplastic large-cell lymphoma recruits, activates, and uses pp60c-src to mediate its mitogenicity. *Blood* 103: 1464-1471, 2004
- 64 ten Berge RL, de Bruin PC, Oudejans JJ, Ossenkoppele GJ, van der Valk P, Meijer CJ: ALK-negative anaplastic large-cell lymphoma demonstrates similar poor prognosis to peripheral T-cell lymphoma, unspecified. *Histopathology* 43: 462-469, 2003
- 65 ten Berge RL, Oudejans JJ, Ossenkoppele GJ, Meijer CJ: ALK-negative systemic anaplastic large cell lymphoma: differential diagnostic and prognostic aspects-a review. *J Pathol* 200: 4-15, 2003
- 66 Marafioti T, Jabri L, Pulford K, Brousset P, Mason DY, Delsol G: Leucocyte-specific protein (LSP1) in malignant lymphoma and Hodgkin's disease. *Br J Haematol* 120: 671-678, 2003
- 67 Rassidakis GZ, Lai R, Herling M, Cromwell C, Schmitt-Graeff A, Medeiros LJ: Retinoblastoma protein is frequently absent or phosphorylated in anaplastic large-cell lymphoma. *Am J Pathol* 164: 2259-2267, 2004
- 68 Rassidakis GS, Goy A, Medeiros LJ, Jiang Y, Thomaidis A, Remache Y, Cabanillas F, Sarris AH, Gilles F: Prognostic significance of MUC-1 expression in systemic anaplastic large cell lymphoma. *Clin Cancer Res* 9: 2213-2220, 2003
- 69 Schlette EJ, Medeiros LJ, Goy A, Lai R, Rassidakis GZ: Survivin expression predicts poorer prognosis in anaplastic large-cell lymphoma. *J Clin Oncol* 22: 1682-1688, 2004
- 70 Lai R, Rassidakis GZ, Medeiros LJ, Ramdas L, Goy AH, Cutler C, Fujio Y, Kunisada K, Amin HM, Gilles F: Signal transducer and activator of transcription-3 activation contributes to high tissue inhibitor of metalloproteinase-1 expression in anaplastic lymphoma kinase-positive anaplastic large cell lymphoma. *Am J Pathol* 164: 2251-2258, 2004
- 71 Herling M, Rassidakis GZ, Jones D, Schmitt-Graeff A, Sarris AH, Medeiros LJ: Absence of Epstein-Barr virus in anaplastic large cell lymphoma: a study of 64 cases classified according to World Health Organization criteria. *Hum Pathol* 35: 455-459, 2004
- 72 Coyne JD, Banerjee SS, Bromley M, Mills S, Diss TC, Harris M: Post-transplant T-cell lymphoproliferative disorder/T-cell lymphoma: a report of three cases of T-anaplastic large-cell lymphoma with cutaneous presentation and a review of the literature. *Histopathology* 44: 387-393, 2004
- 73 Vannier JP, Bastard C, Rossi A, Hemet J, Thomine E, Tron P: Chromosomal t(2; 5) and hematological malignancies. *Pediatr Hematol Oncol* 4: 177-178, 1987
- 74 Morgan R, Hecht BK, Sandberg AA, Hecht F, Smith SD: Chromosome 5q35 breakpoint in malignant histiocytosis. *N Engl J Med* 314: 1322, 1986
- 75 Rimokh R, Magaud JP, Berger F, Samarut J, Coiffier B, Germain D, Mason DY: A translocation involving a specific breakpoint (q35) on chromosome 5 is characteristic of anaplastic large cell lymphoma ('Ki-1 lymphoma'). *Br J Haematol* 71: 31-36, 1989
- 76 Le Beau MM, Bitter MA, Larson RA, Doane LA, Ellis ED, Franklin WA, Rubin CM, Kadin ME, Vardiman JW: The t(2; 5) (p23; q35): a recurring chromosomal abnormality in Ki-1-positive anaplastic large cell lymphoma. *Leukemia* 3: 866-870, 1989
- 77 Bullrich F, Morris SW, Hummel M, Pileri S, Stein H, Croce CM: Nucleophosmin (NPM) gene rearrangements in Ki-1-positive lymphomas. *Cancer Res* 54: 2873-2877, 1994
- 78 Ladanyi M: The NPM/ALK gene fusion in the pathogenesis of anaplastic large cell lymphoma. *Cancer Surv* 30: 59-75, 1997
- 79 Borer RA, Lehner CF, Eppenberger HM, Nigg EA: Major nucleolar proteins shuttle between nucleus and cytoplasm. *Cell* 56: 379-390, 1989
- 80 Pulford K, Lamant L, Morris SW, Butler LH, Wood KM, Stroud D, Delsol G, Mason DY: Detection of anaplastic lymphoma kinase (ALK) and nucleolar protein nucleophosmin (NPM)-ALK proteins in normal and neoplastic cells with the monoclonal antibody ALK1. *Blood* 89: 1394-1404, 1997
- 81 Lamant L, Meggetto F, al Saati T, Brugieres L, de Paillerets BB, Dastugue N, Bernheim A, Rubie H, Terrier-Lacombe MJ, Robert A, Rigal F, Schlaifer D, Shiuta M, Mori S, Delsol G: High incidence of the t(2; 5) (p23; q35) translocation in anaplastic large cell lymphoma and its lack of detection in Hodgkin's disease. Comparison of



- cytogenetic analysis, reverse transcriptase-polymerase chain reaction, and P-80 immunostaining. *Blood* 87 : 284-291, 1996
- 82 Cordell JL, Pulford KAF, Bigerna B, Roncador G, Banham A, Colombo E, Pelicci PG, Mason DY, Falini B : Detection of normal and chimeric nucleophosmin in human cells. *Blood* 93 : 632-642, 1999
- 83 Cools J, Wlodarska I, Somers R, Mentens N, Pedetour F, Maes B, Wolf-Peeters C, Pauwels P, Hagemeijer A, Marynen P : Identification of novel fusion partners of ALK, the anaplastic lymphoma kinase, in anaplastic large-cell lymphoma and inflammatory myofibroblastic tumor. *Genes Chromosomes Cancer* 34 : 354-362, 2002
- 84 Trumper L, Daus H, Merz H, von Bonin F, Loftin U, Cochlovius C, Moller P, Feller AC, Pfreundschuh M : NPM/ALK fusion mRNA expression in Hodgkin and Reed-Sternberg cells is rare but does occur : results from single-cell cDNA analysis. *Ann Oncol* 8 Suppl 2 : 83-87, 1997
- 85 Orscheschek K, Merz H, Hell J, Binder T, Bartels H, Feller AC : Large-cell anaplastic lymphoma-specific translocation (t[2 ; 5] [p23 ; q35]) in Hodgkin's disease : indication of a common pathogenesis? *Lancet* 345 : 87-90, 1995
- 86 Weiss LM, Lopategui JR, Sun LH, Kamel OW, Koo CH, Glackin C : Absence of the t(2 ; 5) in Hodgkin's disease. *Blood* 85 : 2845-2847, 1995
- 87 Elmberger PG, Lozano MD, Weisenburger DD, Sanger W, Chan WC : Transcripts of the npm-alk fusion gene in anaplastic large cell lymphoma, Hodgkin's disease, and reactive lymphoid lesions. *Blood* 86 : 3517-3521, 1995
- 88 Herbst H, Anagnostopoulos J, Heinze B, Durkop H, Hummel M, Stein H : ALK gene products in anaplastic large cell lymphomas and Hodgkin's disease. *Blood* 86 : 1694-1700, 1995
- 89 Camilleri-Broët S, Audouin J, Ferme C, Briere J, Pulford K, Gaulard P, Divine M, Macintyre E, Delsol G, Berger F : ALK is not expressed in Hodgkin disease. *Blood* 97 : 1901-1902, 2001
- 90 Onciu M, Behm FG, Raimondi SC, Moore S, Harwood EL, Pui CH, Sandlund JT : ALK-positive anaplastic large cell lymphoma with leukemic peripheral blood involvement is a clinicopathologic entity with an unfavorable prognosis. Report of three cases and review of the literature. *Am J Clin Pathol* 120 : 617-625, 2003