

Original Article

# “Follicular Variant” of Hyaline-vascular Type of Castleman’s Disease : Histopathological and Immunohistochemical Study of 11 Cases

Masaru Kojima,<sup>1)</sup> Kazuhiko Shimizu,<sup>2)</sup> Hayato Ikota,<sup>3)</sup> Yoshihiro Ohno,<sup>4)</sup> Tadashi Motoori,<sup>5)</sup>  
Hideaki Itoh,<sup>6)</sup> Nobuhide Masawa,<sup>7)</sup> and Shigeo Nakamura<sup>8)</sup>

Occasionally, the hyaline-vascular type of Castleman’s disease (HVCD) contains numerous lymphoid follicles which usually occupy more than 50% of the lesion. Such lesions are called the follicular variant (FV) of HVCD. To clarify the histological and immunohistochemical findings of lymphoid follicles in the FV of HVCD, we examined 11 such cases. Histologically, five types of lymphoid follicles were delineated. Lymphoid follicles ; (i) with normal germinal centers (GCs) ; (ii) showing follicular lysis ; (iii) with progressive transformation of GC (PTGC) ; (iv) where the large nodule of mantle zone lymphocytes contained multiple small atrophic GCs (multiple GC pattern) ; and (v) where the large, often irregularly shaped nodules of mantle cells radically penetrated small vessels with inconspicuous GCs. These nodules somewhat resembled primary lymphoid follicles (primary follicular pattern). The majority of lymphoid follicles in all 11 cases were of the primary follicular pattern and/or multiple GC pattern. However, three lesions also contained normal germinal GC, while two contained normal GC, follicular lysis and PTGC and one other contained normal GC and PTGC. Moreover, in 3 cases of primary follicular pattern, the majority of the lymphoid follicles were surrounded by a pale cuff of mantle cells. Because of the presence of numerous lymphoid follicles, the FV of HVCD should be sometimes differentiated from Hodgkin lymphoma and low-grade B-cell lymphomas showing follicular growth pattern. Recognition of the histological and immunohistochemical findings of the FV of HVCD is needed to avoid overdiagnosis. [*J Clin Exp Hematopathol* 48(2) : 39-45, 2008]

**Keywords:** Castleman’s disease, hyaline-vascular type, follicular variant, histopathology, immunohistochemistry

## INTRODUCTION

In 1956, Castleman *et al.* described an entity involving localized mediastinal lymph node hyperplasia that resembled thymoma.<sup>1</sup> Since the original description, Castleman’s disease (CD) has been extended to include two entities, the classical hyaline vascular (HV) type and also a rare plasma cell variant.<sup>1-3</sup> Histologically, HV type CD is characterized by abnormal lymphoid follicles and interfollicular vascularity.<sup>1-4</sup> Lymphoid follicles of HV type are usually small- to medium-sized, and contain small blood vessels that often radically penetrate the small atrophic GCs.<sup>1-4</sup> The proportion of the two components -abnormal lymphoid follicles and increased interfollicular vascularity- may vary from cases containing numerous lymphoid follicles to cases with a predominantly vascular component and fibrosis.<sup>2-5</sup> Occasionally, the hyaline-vascular type of Castleman’s disease (HVCD) contains numerous lymphoid follicles.<sup>5</sup> Such lesions are called the follicular variant (FV) of HVCD (usually lymphoid follicles comprised more than 50% of the lesion).<sup>5</sup> Because of the presence of numerous lymphoid

---

Received : July 12, 2007

Revised : September 11, 2007

Accepted : September 20, 2007

<sup>1)</sup>Department of Pathology and Clinical Laboratories, Gunma Cancer Center Hospital, Ohta, Japan.

<sup>2)</sup>Department of Pathology and Clinical Laboratories, Ashikaga Red Cross Hospital, Ashikaga, Japan.

<sup>3)</sup>Department of Pathology and Clinical Laboratories, Fukaya Red Cross Hospital, Fukaya, Japan.

<sup>4)</sup>Department of Pathology, Tone Central Hospital, Numata, Japan.

<sup>5)</sup>Department of Pathology, Kitasato University, Kitasato Institute Medical Center Hospital, Kitamoto, Japan.

<sup>6)</sup>Department of Pathology and Clinical Laboratories, Maebashi Red Cross Hospital, Maebashi, Japan.

<sup>7)</sup>Department of Pathology, Dokkyo Medical University School of Medicine, Mibu, Japan.

<sup>8)</sup>Department of Pathology and Clinical Laboratories, Nagoya University School of Medicine, Nagoya, Japan.

Address correspondence and reprint request to Masaru Kojima, M.D., Department of Pathology and Clinical Laboratories, Gunma Cancer Center Hospital, 617-1, Takabayashinishi-cho Ohta, 373-8550, Japan.

E-mail : mkojima@gunma-cc.jp

follicles, the FV of HVCD should be differentiated from malignant lymphomas showing follicular growth pattern.<sup>6</sup> To clarify the histological and immunohistochemical findings of FV of HVCD, we examined 11 such cases, and discuss the differential diagnostic problems.

## MATERIALS AND METHODS

Eleven cases were collected from a series by one of the authors (M.K.) treated between 1992 and 2006. Three cases (Nos. 2, 3 and 7) were reported previously.<sup>7,8</sup>

The tissue specimens were fixed in formalin, routinely processed and embedded in paraffin wax. For light microscopic examination, sections were stained with hematoxylin-eosin and Giemsa.

Immunohistochemistry was performed on paraffin sections using a Ventana automated stainer according to the manufacturer's directions. The panel of antibodies against human immunoglobulin  $\kappa$  and  $\lambda$  light chains (Novocastra, New Castle, UK), IgD (Novocastra), IgM (Dako A/S, Glostrup, Denmark), PS-1 (CD3; MBL, Nagoya, Japan), 4C7 (CD5; Novocastara), 56C6 (CD10; Novocastra), L26 (Dako), 1B12 (CD23; Novocastra), DFT-1 (CD43; Novocastra), NK-1 (CD57; Zymed, South San Francisco, USA), PGM-1 (CD68; Dako), SP-4 (Cyclin D1; Nichirei Co., Tokyo, Japan), 124 (bcl-2; Dako), anti-follicular dendritic cell (FDC) antibody (CNA.42; Dako), 137B1 [anti-human herpes virus type 8 (HHV8); Novocastra] and E29 (EMA; Dako). Sections with known reactivity to the antibodies assayed served as positive controls and the section treated with normal rabbit- and mouse-serum served as negative controls.

In 3 cases, paraffin wax-embedded tissues from biopsied

specimens were prepared for polymerase chain reaction (PCR), and the rearranged heavy-chain genes were amplified using the semi-nested PCR method described by Wan *et al.*<sup>9</sup>

## RESULTS

The main clinicopathologic findings are shown in the Table 1.

### Clinical findings

The subjects consisted of six males and five females, ranging from 26 to 57 years with a mean age of 47 and a median age of 44 years. Tumor sizes ranged from 2.0 cm to 6 cm in maximal diameter (mean = 4.0 cm, median = 4.2 cm). In 8 patients (Nos. 2-4, and 6-10), the tumor was localized in the lymph nodes (intra-abdominal = 4, neck = 2, axilla = 1, inguinal = 1) and in the remaining 3 cases (Nos. 1, 5, and 11), the tumor originated in the soft tissue (neck = 2, intra-abdominal = 1). One patient (No. 5) was diagnosed with gastric cancer. Follow-up information was available between 3 and 120 mon (mean, 39 mon; median, 48 mon) in 9 cases (Nos. 2-7, and 9-11). At the last follow up, all 9 cases were alive without disease.

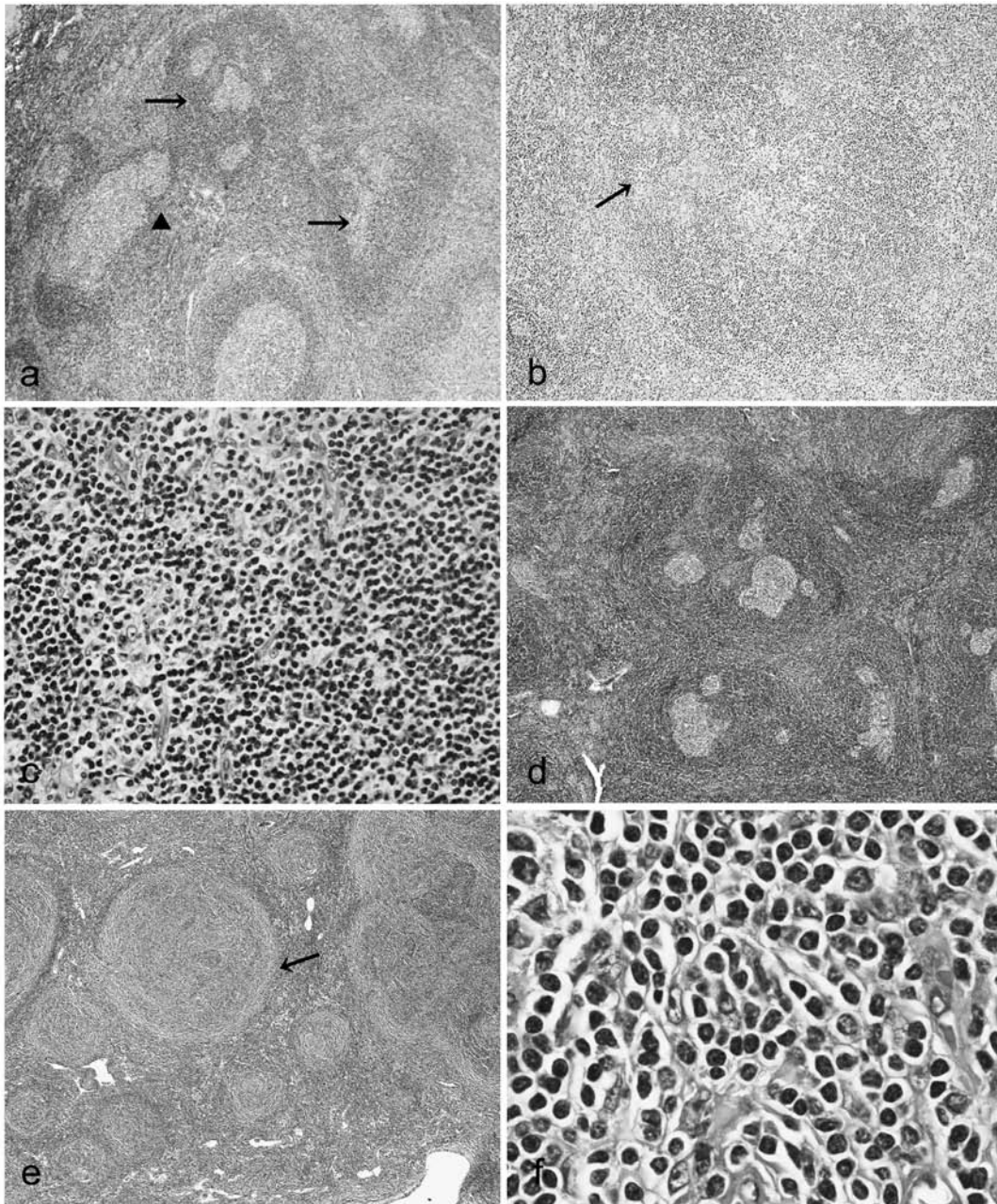
### Pathological findings

Under low magnification, the lymph nodes in all 11 cases was found to contain numerous lymphoid follicles (Fig. 1a). Five types of lymphoid follicles were identified. (i) The lymphoid follicles with normal hyperplastic GCs. (ii) Lymphoid follicles showing follicular lysis (Fig. 1a). (iii) Progressive transformation of GC (PTGC).<sup>8,10,11</sup> The PTGC appeared as a

**Table 1.** Clinicopathological findings of 11 cases

Case No.	Age/ Gender	Site of tumor	Size (cm)	outcome	NGC	FL	PTGC	MPGC	PF	PCM	PDC	FT
1	26/F	Neck	3	Lost	+	-	-	+	+	-	-	+
2	28/F	Intra-abdominal	4.2	65 mon AW	-	-	-	+	+	+	+	-
3	31/F	Inguinal	3.5	44 mon AW	+	+	+	+	+	-	-	+
4	32/M	Intra-abdominal	5	14 mon AW	+	-	+	+	-	-	+	+
5	42/M	Intra-abdominal	3	120 mon AW	-	-	-	+	+	+	-	-
6	44/F	Intra-abdominal	4.2	3 mon AW	+	-	-	+	+	-	-	+
7	49/M	Neck	2	12 mon AW	+	+	+	+	-	-	+	-
8	52/F	Neck	2	Lost	-	-	-	+	+	-	+	-
9	52/M	Intra-abdominal	6	65 mon AW	+	-	-	+	+	+	+	-
10	52/M	Axilla	6	48 mon AW	-	-	-	+	+	-	+	+
11	57/M	Neck	5	60 mon AW	-	-	-	+	+	-	+	+

NGC, normal germinal center; FL, follicular lysis; PTGC, progressive transformation of germinal center; MPGC, multiple germinal center pattern; PF, primary follicular pattern; PCM, pale cuff of mantle cells; PDC, plasmacytoid dendritic cells; FT, fibrous tissue; AW, alive well



**Fig. 1.** Histopathological findings. **(1a)** Low power field of the affected lymph node. A lymphoid follicle showing follicular lysis (*arrow head*) and two large PTGCs (*arrows*). Hematoxylin-eosin (HE), x10 (Case 3). **(1b)** Medium power field of the affected lymph node. Note a PTGC containing small hyalinized vessels (*arrow*) was present. HE, x25 (Case 3). **(1c)** High power field of PTGC. A relatively large number of residual centrocytes, centroblasts and immunoblasts were present, in addition to small mantle zone lymphocytes. HE, x100 (Case 3). **(1d)** Low power field of the affected lymph node. The large nodules of mantle cells contained multiple small atrophic GCs with increased vascularity. HE, x10 (Case 9). **(1e)** Low power field of the affected lymph node. Note the large nodules of mantle cells with inconspicuous germinal centers. Frequently, these nodules were radically penetrated by small vessels. The majority of lymphoid follicles were surrounded by a pale cuff of the lymphoid cells (*arrow*). HE, x10 (Case 2). **(1f)** Higher magnification shows that the pale cuffs were composed of small- to medium-sized lymphocytes with round or slightly indented nuclei and a broad rim of pale cytoplasm. HE, x250 (Case 2).

round or oval structure, two to three times the diameter of other reactive follicles (Fig. 1a). Occasionally, some of the PTGC contained small hyalinized vessels (Fig. 1b). PTGC were composed predominantly of small lymphocytes with variable numbers of centrocytes, centroblasts and immunoblasts (Fig. 1c).<sup>8,10,11</sup> (iv) Large nodules of mantle cells contained multiple small atrophic GC with increased vascularity (multiple GC pattern) (Fig. 1d).<sup>3,4</sup> (v) Large, often irregularly shaped nodules of mantle cells with inconspicuous GCs. Frequently, these nodules were radically penetrated by small vessels and somewhat resembled primary follicles (primary follicular pattern) (Fig. 1e).<sup>3,4</sup> In 3 cases (Nos. 2, 5, and 9), the majority of lymphoid follicles were surrounded by a pale cuff of the lymphoid cells (Fig. 1e). Higher magnification revealed that the pale cuffs were composed of small- to medium-sized lymphocytes with round or slightly indented nuclei and a broad rim of pale cytoplasm (Fig. 1f).

The majority of the lymphoid follicles in all 11 cases showed a primary follicular pattern and/or multiple GC pattern. However, three lesions (Nos. 1, 6, and 9) also contained normal GCs, two (Nos. 3 and 7) contained normal GC, follicular lysis and PTGCs, and one (No. 4) contained normal GC and PTGC.

There were no typical popcorn cells or Reed-Sternberg cells in the large nodule of mantle cells showing PTGC, multiple GC pattern and primary follicular pattern. The interfollicular area was composed of small, round lymphocytes mixed with a few immunoblasts and isolated histiocytes. However, none of the 11 cases contained epithelioid cell granulomas. In 6 cases (Nos. 2, 4, and 7-11) plasmacytoid dendritic cells were observed.<sup>12</sup> Small vessels were prominent in all 11 subjects and perivascular fibrous masses were observed in 6 cases (Nos. 1, 3, 4, 6, 11, and 12).

#### ***Immunohistochemical and genotypic findings***

The results of immunohistochemical study of these patients were similar to those described in previous reports.<sup>7,8,10-16</sup>

Briefly, mantle cells in onion skin pattern, multiple GC pattern and PTGC were CD20<sup>+</sup>, sIgM<sup>+</sup>, sIgD<sup>+</sup>, CD5<sup>-</sup>, CD10<sup>-</sup>, CD23<sup>-</sup>, CD43<sup>-</sup>, bcl-2<sup>+</sup>, bcl-6<sup>-</sup> and cyclin D1<sup>-</sup>.<sup>7,8,13</sup> The pale cuff of lymphoid cells in 3 cases of primary follicular pattern showed identical immunophenotypic findings as seen in mantle cells.<sup>7</sup>

Staining with monoclonal antibodies 1B12 (CD23) and CNA.42 highlighted the meshwork of FDC. The FDC networks of the primary follicular pattern and multiple GC pattern showed a tight/concentric pattern (Fig. 2a) or expanded/disrupted pattern (Fig. 2b) as previously described by Nguyen *et al.*<sup>16</sup> The FDC meshwork was completely disrupted into clusters in PTGC (Fig. 2c), as occurs in lymphoid follicles undergoing follicular lysis.<sup>10</sup>

Numerous CD57<sup>+</sup> T-cells were observed in normal GC, GC showing follicular lysis and PTGC (Fig. 2d).<sup>8,10,13,17</sup> However, CD57<sup>+</sup> T-cells in GC detected in multiple GC pattern were decreased in number (Fig. 2e). There were only a few CD57<sup>+</sup> T-cells in the GC in the primary follicular pattern (Fig. 2f).<sup>8,14,15</sup> Scattered CD57<sup>+</sup> T-cells were detected in the expanded mantle zone of the multiple GC pattern (Fig. 2e), primary follicular pattern (Fig. 2f) and PTGC.

Scattered B-immunoblasts in the PTGC and interfollicular area were CD30<sup>+</sup>, but CD15<sup>-</sup> and EMA<sup>-</sup>. PTGC containing small hyalinized vessels also showed identical immunohistological findings to PTGC without small vessels. There were no HHV-8<sup>+</sup> cells in any of the 9 cases (Nos. 1-4, 6, and 8-11) examined. Genotypic studies with immunoglobulin heavy chain probes demonstrated only germ line bands in 3 cases (Nos. 1, 2, and 6) examined.

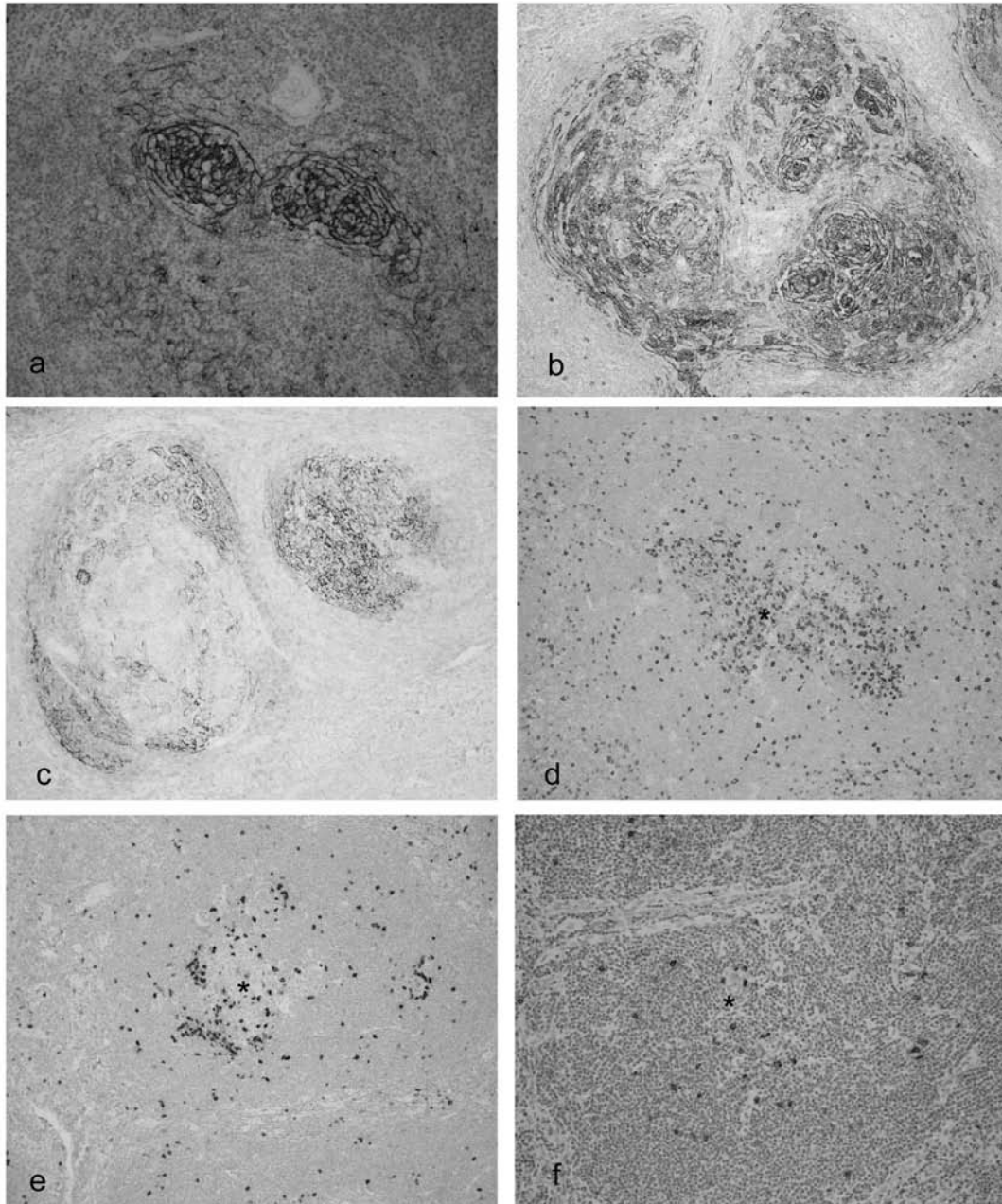
## **DISCUSSION**

Keller *et al.* and Frizzera stated that, "primary follicular pattern" and "multiple GC pattern" are characteristic follicular patterns of HVCD as well as small HV follicles.<sup>3,4</sup> However, it appears that only a portion of HVCD contained numerous "primary follicular pattern" and "multiple GC pattern".<sup>3</sup> All of our 11 cases of FV, contained numerous "primary follicular patterns" and "multiple GC patterns". Because of the presence of large nodules of mantle cells, the present 11 cases should be differentiated from various malignant lymphoma showing follicular growth pattern.<sup>6</sup>

Among these, as previously emphasized, mantle cell lymphoma is the most important diagnostic problem.<sup>5,18,19</sup> Mantle cell lymphomas usually show a mantle zone growth pattern with a remnant of small atrophic GCs and nodular growth pattern without GCs.<sup>18,20,21</sup> The former pattern should be differentiated from the "multiple GC pattern" and the latter should be differentiated from the "primary follicular pattern". However, mantle cells of the present 11 cases were CD5<sup>-</sup>, CD43<sup>-</sup> and cyclin D1<sup>-</sup>.<sup>18-21</sup>

Nodal marginal zone B-cell lymphoma (NMZBL) sometimes contains numerous regressive GCs, and should be differentiated from HVCD.<sup>22</sup> Moreover, the pale cuff of the lymphocytes in 3 cases showing the primary follicular pattern resembled the marginal zone distribution pattern of NMZBLs. The tumor cells of NMZBL are small- to medium-sized lymphocytes showing a moderate amount of clear cytoplasm, indented or round nuclei, and absent or small nucleoli (centrocyte-like cells).<sup>6,21</sup> The lymphocytes of the pale cuff in these 3 cases of primary follicular pattern showed cytological findings similar to those of centrocyte-like cells. However, immunohistochemical study demonstrated that proliferating cells were sIgD<sup>+</sup>, sIgM<sup>+</sup> and CD5<sup>-</sup>, CD43<sup>-</sup> suggesting a non-neoplastic mantle cell nature.<sup>18,19,21</sup>

Follicular lymphoma rarely shows lymphoid follicles



**Fig. 2.** Immunohistochemical findings. **(2a)** CNA.42 immunostain demonstrated tight/concentric pattern of follicular dendritic cell (FDC) network in multiple germinal center (GC) pattern. The follicle contained more than one FDC network. x50 (Case 11). **(2b)** CNA.42 immunostain demonstrated an expanded/disrupted pattern of FDC network in the primary follicular pattern. The follicle contained more than one FDC network. x25 (Case 9). **(2c)** CNA.42 immunostain demonstrated completely disrupted FDC network into clusters in progressive transformation of GC (PTGC). x25 (Case 7). **(2d)** Numerous CD57<sup>+</sup> T-cells were observed in the GC (*asterisk*) of the PTGC. x25 (Case 7). **(2e)** CD57<sup>+</sup> T-cells were decreased in number in GCs (*asterisk*) of the multiple GC pattern. Scattered CD57<sup>+</sup> T-cells were detected in the expanded mantle zone. x25 (Case 9). **(2f)** Only a few CD57<sup>+</sup> T-cells in the GC (*asterisk*) in the primary follicular pattern. Scattered CD57<sup>+</sup> T-cells were detected in the expanded mantle zone. x25

mimicking FV of HVCD.<sup>23,24</sup> However, the “primary follicular pattern” should be differentiated from follicular lymphoma of the small cleaved cell type (grade 1).<sup>21,24</sup> The tumor cells of follicular lymphomas are CD10<sup>+</sup>, sIgM<sup>+</sup>, and sIgD<sup>-</sup>, whereas the mantle cells in the “primary follicular pattern” were CD10<sup>-</sup>, sIgM<sup>+</sup>, and sIgD<sup>+</sup>.<sup>6</sup> The number of CD57<sup>+</sup> T-cells is equivalent to the number in reactive follicles.<sup>6,17</sup> However, there were only a few CD57<sup>+</sup> T-cells in the nodules of the “primary follicular pattern”. Moreover, there is usually a preserved FDC network in the area showing a follicular growth pattern in follicular lymphoma.<sup>21,25</sup> However, the present study demonstrated abnormal FDC pattern of the characteristic findings of HVCD.<sup>16</sup>

The histological features of nodular lymphocytes prevalent in Hodgkin lymphoma exhibits nodules of small lymphocytes, predominantly mantle cells as well as the “primary follicular pattern”.<sup>6,10</sup> However, there were no popcorn cells in the expanded mantle zone in the “primary follicular pattern”.

Follicular Hodgkin lymphoma is characterized by small eccentrically placed atrophic GCs and an expanded GC.<sup>6,26,27</sup> The nodules of “multiple GC pattern” somewhat resembled follicular Hodgkin lymphoma. However, there were no CD15<sup>+</sup> and/or CD30<sup>+</sup> typical Reed-Sternberg cells in the nodules showing a “multiple GC pattern”.

The etiology of HVCD remains unknown. Some investigators considered HVCD to be a hamartomatous lesion.<sup>1,3,16</sup> However, the present study demonstrated histological variations of lymphoid follicles in the FV of HVCD : i.e. (i) normal GC, (ii) GC showing follicular lysis, (iii) PTGC, (iv) “multiple GC pattern”, and (v) “primary follicular pattern”. The presence of five types of lymphoid follicles in two of our 11 lesions of FV of HVCD appears to represent a sequential spectrum of morphologic evolution in lymphoid hyperplasia in response to antigenic stimuli of unknown origin as Flendrig previously suggested.<sup>2</sup> Moreover, the presence of PTGC containing small vessels suggested that part of the HVCD appears to be the ultimate fate of PTGC.

Finally, as suggested by Hunt *et al.*,<sup>28</sup> reactive lymph node lesions may rarely show mantle cell hyperplasia with clear cytoplasm. In our study, an association of mantle cell hyperplasia with clear cytoplasm and LV of HVCD has a relatively high incidence (27%). However, this series was too small to definitively clarify this issue.

## REFERENCES

- 1 Castleman B, Iverson L, Menendez VP : Localized mediastinal lymphnode hyperplasia resembling lymphoma. *Cancer* 9 : 822-830, 1956
- 2 Flendrig JA : Benign giant lymphoma : clinicopathologic correlation study. In Clark RL, Gumley RW (eds) : *The Year Book of Cancer*. Year Book Medical Publishers, Chicago, 1970, pp. 296-299
- 3 Keller AR, Hochholzer L, Castleman B : Hyaline-vascular and plasma-cell types of giant lymph node hyperplasia of the mediastinum and other locations. *Cancer* 29 : 670-683, 1972
- 4 Frizzera G : Castleman's disease and related disorders. *Semin Diagn Pathol* 5 : 346-364, 1988
- 5 Danon AD, Krishnan J, Frizzera G : Morpho-immunophenotypic diversity of Castleman's disease, hyaline-vascular type : with emphasis on a stroma-rich variant and a new pathogenic hypothesis. *Virchows Arch [A Pathol Anat Histopathol]* 423 : 369-382, 1993
- 6 Isaacson PG : Malignant lymphoma with follicular growth pattern. *Histopathology* 28 : 487-495, 1996
- 7 Kojima M, Nakamura S, Iijima M, Murayama K, Sakata N, Masawa N : Lymphoid variant of hyaline vascular Castleman's disease containing numerous mantle zone lymphocytes with clear cytoplasm. *Case report. APMIS* 113 : 75-80, 2005
- 8 Kojima M, Nakamura S, Miyawaki S, Ohno Y, Sakata N, Masawa N : Progressive transformation of germinal center presenting with histological features of hyaline-vascular type of Castleman's disease. *APMIS* 113 : 288-295, 2005
- 9 Wan JH, Trainor KJ, Brisco MJ, Morley AA : Monoclonality in B-cell lymphoma detected in paraffin wax embedded sections using the polymerase chain reaction. *J Clin Pathol* 43 : 888-890, 1990
- 10 Nguyen PL, Ferry JA, Harris NL : Progressive transformation of germinal centers and nodular lymphocyte predominance Hodgkin's disease. A comparative immunohistochemical study. *Am J Surg Pathol* 23 : 27-33, 1999
- 11 Chang CC, Osiupov V, Wheaton S, Tripp S, Perkins SL : Follicular hyperplasia, follicular lysis, and progressive transformation of germinal centers. A sequential spectrum of morphologic evolution in lymphoid hyperplasia. *Am J Clin Pathol* 120 : 322-326, 2003
- 12 Harris NL, Bhan AK : “Plasmacytoid T cells” in Castleman's disease. Immunohistologic phenotype. *Am J Surg Pathol* 11 : 109-113, 1987
- 13 van den Oord JJ, De Wolf-Peeters C, Desmet VJ : Immunohistochemical analysis of progressively transformed follicular centers. *Am J Clin Pathol* 83 : 560-564, 1983
- 14 van den Oord JJ, De Wolf-Peeters C, Tricot G, Desmet VJ : Distribution of lymphocyte subsets in a case of angiofollicular lymph node hyperplasia. *Am J Clin Pathol* 82 : 491-495, 1984
- 15 Martin JM, Bell B, Ruether BA : Giant lymph node hyperplasia (Castleman's disease) of hyaline vascular type. Clinical heterogeneity with immunohistologic uniformity. *Am J Clin Pathol* 84 : 439-446, 1985
- 16 Nguyen DT, Diamond LW, Hansmann ML, Alavaikko MJ, Schroder H, Fellbaum C, Fischer R : Castleman's disease, Differences in follicular dendritic network in the hyaline vascular and plasma cell variants. *Histopathology* 24 : 437-443, 1994
- 17 Mori S, Mohri N, Morita H, Yamaguchi K, Shimamine T : The distribution of cells expressing a natural killer cell marker (HNK-1) in normal human lymphoid organs and malignant lymphomas.

- Virchows Arch [B Cell Pathol Incl Mol Pathol] 43 : 253-263, 1983
- 18 Weisenburger DD, Duggan MJ, Perry DA, Sanger WG, Armitage JO ; Non-Hodgkin's lymphomas of mantle zone origin. *Pathol Annu* 26 (Pt I) : 139-158, 1991
  - 19 Banks PM : Microscopic mimicry of lymphomas : diagnostic pitfalls. *Mod Pathol* 12 : 116-124, 1999
  - 20 Yatabe Y, Suzuki R, Matsuno Y, Tobinai K, Ichinohazama R, Tamaru J, Mizoguchi Y, Hashimoto Y, Yamaguchi M, Kojima M, Uike N, Okamoto M, Isoda K, Ichimura K, Morishima Y, Seto M, Suchi T, Nakamura S : Morphological spectrum of cyclin D1-positive mantle cell lymphoma : study of 168 cases. *Pathol Int* 51 : 747-761, 2001
  - 21 Feller AC, Diebold J : *Histopathology of nodal and extranodal non-Hodgkin's lymphomas*. Berlin, Springer, 2004
  - 22 Kojima M, Nakamura S, Motoori T, Shimano S, Murayama K, Tamaki Y, Shimizu K, Oyama T, Sugihara S, Sakata N, Masawa N : Primary marginal zone B-cell lymphoma of the lymph node resembling plasmacytoma arising from a plasma cell variant of Castleman's disease. A clinicopathological and immunohistochemical study of seven patients. *APMIS* 110 : 875-880, 2002
  - 23 Warnke RF, Weiss LM, Chan JKC, Clearre ML, Dorfman RF : Tumor of the lymph nodes and spleen (Atlas of tumor pathology, 3rd series, fascicle 14). Armed Forces Institute of Pathology, Bethesda MD, 1995
  - 24 Nozawa Y, Hirao M, Kamimura K, Hara Y, Abe M : Unusual case of follicular lymphoma with hyaline vascular follicles. *Pathol Int* 52 : 794-795, 2002
  - 25 Scoazec JY, Berger F, Magaud JP, Brochier J, Coiffier B, Bryon PA : The dendritic reticulum cell pattern in B cell lymphomas of the small cleaved, mixed, and large cell types : an immunohistochemical study of 48 cases. *Hum Pathol* 20 : 124-131, 1989
  - 26 Ashton-Key M, Thorpe PA, Allen JP, Isaacson PG : Follicular Hodgkin's disease. *Am J Surg Pathol* 19 : 1294-1299, 1995
  - 27 Kansal R, Singleton TP, Ross CW, Finn WG, Padmore RF, Schnitzer B : Follicular Hodgkin lymphoma : A histopathologic study. *Am J Clin Pathol* 117 : 29-35, 2002
  - 28 Hunt JP, Chan JA, Samoszuk M, Brynes RK, Hernandez AM, Bass R, Weisenburger DD, Müller-Hermelink K, Nathwani BN : Hyperplasia of mantle/marginal zone B cells with clear cytoplasm in peripheral lymph nodes. A clinicopathologic study of 35 cases. *Am J Clin Pathol* 116 : 550-559, 2001