

Case Study

t(11;18)(q21;q21)-positive Advanced-stage MALT Lymphoma Associated with Monoclonal Gammopathy : Resistance to Rituximab or Rituximab-containing Chemotherapy

Hitoshi Ohno¹⁾ and Kotaro Isoda²⁾

Here we describe two cases of mucosa-associated lymphoid tissue (MALT) lymphoma with monoclonal immunoglobulins (Igs). The first case was a 77-year-old man with primary lymphoma of the lung. Immunoelectrophoresis detected IgM- κ in serum and κ light chain excretion into urine. Three months after treatment with single-agent rituximab, a large amount of pleural fluid was found to have accumulated. The fluid contained CD5⁻, CD10⁻, CD19⁺, CD38⁺ and CD138^{+/+} lymphoma cells with lymphoplasmacytoid appearance. Although a small fraction of the cells were CD20⁺, the majority of the lymphoma cells were negative and expressed surface-membrane IgM- κ at low levels. The cells possessed a karyotype of 46, XY, t(11;18)(q21;q21). The second case was a 55-year-old man who underwent total gastrectomy due to gastric perforation. Surgical specimens demonstrated the histopathological features of MALT lymphoma associated with plasma cell differentiation. The lymphoma cells had a 46, XY, t(11;18)(q21;q21) karyotype. Monoclonal Igs detected were serum IgA (M)- κ and urinary κ light chain. The patient was subsequently treated with six cycles of R-CVP (rituximab, cyclophosphamide, vincristine and prednisolone); however, serum monoclonal Ig levels were not affected. The lymphoma cells in both cases may have contained two populations, a rituximab-sensitive CD20⁺ population and a rituximab-resistant population that had differentiated into the Ig-secreting plasma cell stage. [*J Clin Exp Hematopathol* 48(2) : 47-54, 2008]

Keywords: MALT lymphoma, monoclonal gammopathy, rituximab, t(11;18)(q21;q21), CD20

INTRODUCTION

Monoclonal immunoglobulin (Ig) in the serum and/or urine can be detected in a variety of mature B-cell-type lymphoproliferative disorders, including extranodal marginal zone B-cell lymphoma of mucosa-associated lymphoid tissue (MALT lymphoma).¹ MALT lymphoma tissues contain not only "centrocyte-like" cells but also plasmacytoid cells with varying degrees of maturation,² which may explain the high incidence of monoclonal gammopathy in this particular subtype of low grade B-cell tumors.^{3,4} On the other hand, several

cases have been reported to exhibit features overlapping with primary macroglobulinemia,⁵⁻¹⁰ supporting further that neoplastic cells in MALT lymphomas have the potential to differentiate into Ig-secreting plasma cells.

Rituximab, a human-mouse chimeric monoclonal antibody against CD20 antigen, has been used in patients with B-cell tumors in a number of clinical settings.¹¹ Although controlled trials to define the optimal therapy for MALT lymphoma have not been published, rituximab alone has some activity against both untreated and relapsed MALT lymphoma, irrespective of the stage or primary site.¹²⁻¹⁴ In this report, we describe two cases of advanced-stage MALT lymphoma associated with monoclonal gammopathy. While the disease appeared initially to respond to single-agent rituximab or rituximab-containing chemotherapy, the levels of monoclonal Ig in the serum were not significantly altered by treatment. This case report also suggests a potential mechanism for the resistance of MALT lymphoma to rituximab.

Received : June 25, 2007

Revised : November 9, 2007

Accepted : January 19, 2008

¹⁾Department of Hematology, Takeda General Hospital, Kyoto, Japan

²⁾Kyoto Byori, Kyoto, Japan

Address correspondence and reprint request to Hitoshi Ohno, M.D., Ph.D., Department of Hematology, Takeda General Hospital, 28-1 Ishida, Mori-minami-cho, Fushimi-ku, Kyoto 601-1495, Japan

E-mail : hitoshi-ono@fm2.seikyoku.ne.jp

CASE REPORT

Case 1

The patient was a 77-year-old man who presented to our hospital with shortness of breath. Chest radiography and computed tomography (CT) revealed irregular opacities, consisting of confluent tumor masses and interstitial infiltrates occupying the middle fields of both lungs. Combined positron-emission tomography (PET) and CT demonstrated intense accumulation of fluorodeoxyglucose (FDG) within these complicated lung lesions (Fig. 1a). No extra-thoracic lesions were detected.

Three years prior to presentation, the patient had undergone bronchoscopic examination for the lung lesions at another hospital. Histological specimens prepared from the bronchoalveolar lavage fluid detected the accumulation of small lymphoma cells that stained with an anti-CD20 monoclonal antibody. The patient was diagnosed with a low-grade lymphoma of "bronchus-associated lymphoid tissue"; at that time, however, he declined treatment for the disease.

Blood cell counts and routine blood chemistry were normal, with the exception of an M-spike on protein electrophoresis. Serum contained 95 mg/dL IgA, 433 mg/dL IgG, and 2,022 mg/dL IgM. Immunoelectrophoresis confirmed that the monoclonal Ig in the serum was labeled with IgM and κ -chain anti-sera; κ light chain was detected in urine. Immunophenotyping of the peripheral blood and bone marrow by flow cytometry revealed a monoclonal B-cell population expressing surface-membrane (Sm) IgM- κ . The serum level of soluble interleukin-2 receptor (sIL-2R) was 8,925 IU/mL.

After informing the patient of the potential treatment options for disseminated low-grade B-cell lymphoma, he gave consent to be treated with single-agent rituximab. In response to four weekly doses of 375 mg/m² rituximab, the lung lesions appeared to regress; his respiratory symptoms resolved (Fig. 2a). Three months after treatment, however, he developed dyspnea. A chest radiograph indicated marked progression of the right pleural effusion. Serum levels of sIL-2R and monoclonal Ig increased concurrently (Fig. 2a). The pleural fluid contained large numbers of lymphoma cells with a lymphoplasmacytoid appearance (Fig. 3a). Occasional large and/or bi-nucleated cells were present. Flow cytometry revealed a surface phenotype of CD5⁻, CD10⁻, CD19⁺, CD38⁺ and CD138^{+/+} (Fig. 3b). Although a small fraction of the cells were CD20⁺, the lymphoma cells were primarily CD20⁻, expressing low levels of SmIgM- κ (Fig. 3b). The G-banded karyotype of the pleural fluid cells was: 46, XY, t(11;18)(q21;q21) [12]/46, XY [8].

The fluid contained monoclonal Ig identical to that found in serum; the levels of Ig were 43 mg/dL IgA, 195 mg/dL IgG, and 1,500 mg/dL IgM. The concentration of lactate

dehydrogenase was 2,870 IU/L. After removal of the pleural effusion, the patient's respiratory symptoms improved. The patient declined further treatment for lymphoma, but has been followed up regularly as an outpatient.

Case 2

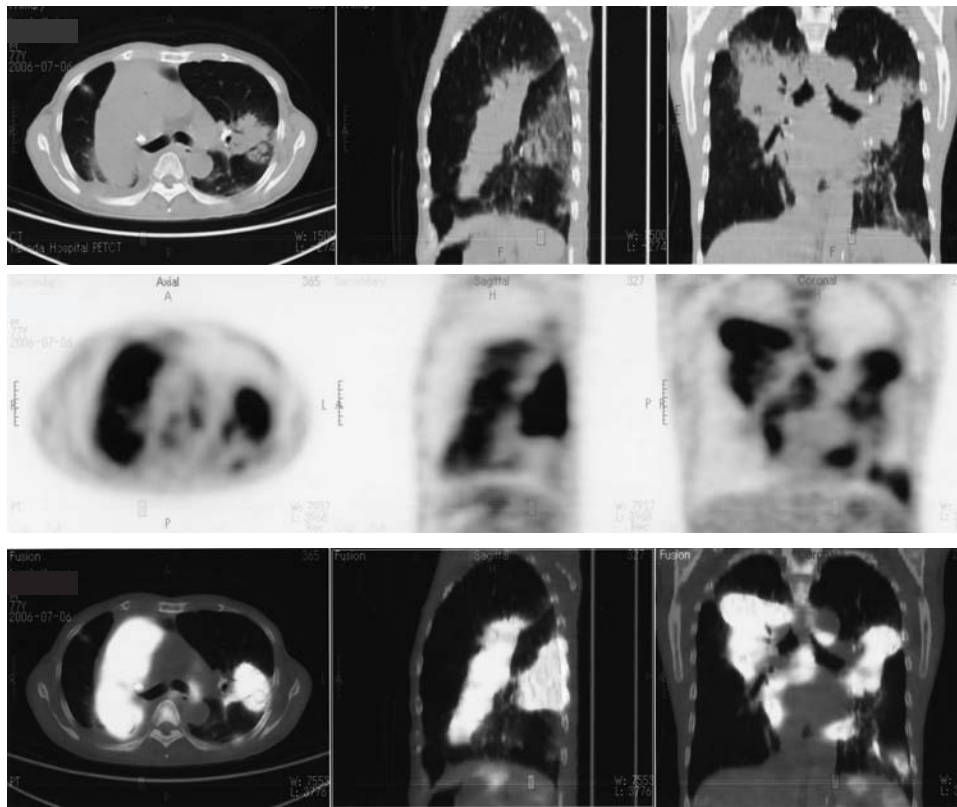
A 55-year-old man was admitted to our hospital with perforation of the gastrointestinal tract. Five years prior to admission, the patient had presented to another hospital with anorexia and weight loss; endoscopic examination had revealed gastric MALT lymphoma. His symptoms improved in response to antibiotic therapy for eradication of *Helicobacter pylori* (*H. pylori*). The patient had remained well until the day before admission, when he developed sudden-onset, severe, diffuse abdominal pain.

A CT scanning of the abdomen taken at admission revealed free air anterior to the left lobe of the liver, thickening of the gastric wall, and para-aortic lymphadenopathy. Immediate laparotomy was performed, revealing a perforation at the anterior wall of the mid-body of the stomach; this lesion was closed with a piece of greater omentum. Endoscopic examination after surgery demonstrated erosions of the mucosa from the fundus to the pre-pylorus and a cobble-stone appearance of the mid-body. Biopsies revealed a non-diagnostic lymphocytic infiltrate. Bacterial cultures for *H. pylori* were negative. A PET scan indicated increased FDG uptake in the gastric wall and lymph nodes of the mediastinum and the lung hilum (Fig. 1b).

The patient subsequently underwent subtotal gastrectomy due to concerns that future cytotoxic therapy would lead to gastric perforation and/or bleeding. Microscopic examination of the excised stomach revealed transmural infiltrates of small lymphoid cells, extending from the mucosa (Fig. 4a) to the serosa (Fig. 4b). Cells within the subepithelial areas, which exhibited a plasmacytoid appearance, had invaded the gastric glands, generating lymphoepithelial lesions (Fig. 4c and 4d). Regional lymph nodes displayed a nodular architecture with expansion of the marginal zone, containing small cells and scattered large cells (Fig. 4e and 4f) expressing CD20 and Bcl-2 (Fig. 4g and 4h). Outside of these nodules, we observed cytological heterogeneity; immunoblast-like cells and plasma cells aggregated within the sinusoids (Fig. 4i).

We prepared a single cell suspension from a lymph node and subjected these cells to flow cytometry. Lymphoma cells expressed CD19, CD20, and either SmIgM or SmIgA in association with κ light chain, but lacked CD5 and CD10 expression. No plasma cell fraction was detected in this study. Thirteen of 14 metaphases had a karyotype of 46, XY, t(11;18)(q21;q21); fluorescence *in situ* hybridization (FISH) of interphase cells confirmed an alteration in the *MALT1* gene. Both bone marrow and peripheral blood included a monoclonal B-cell population of the CD19⁺, CD20⁺, and SmIg κ

1a



1b

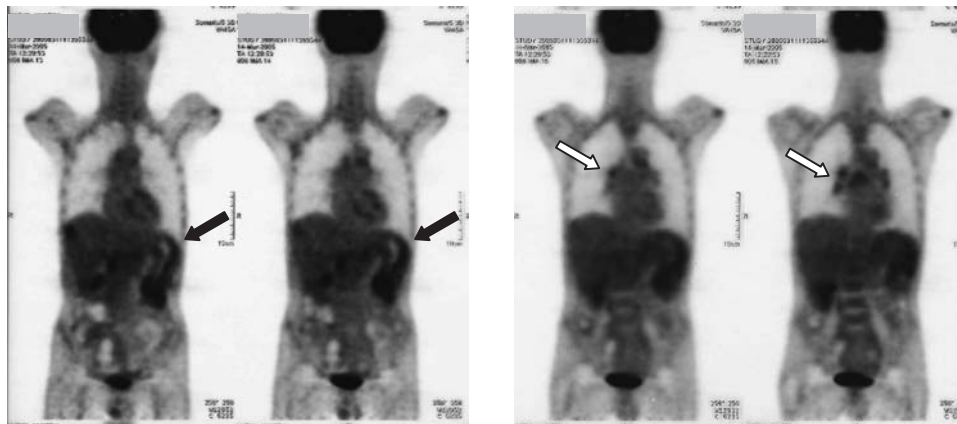
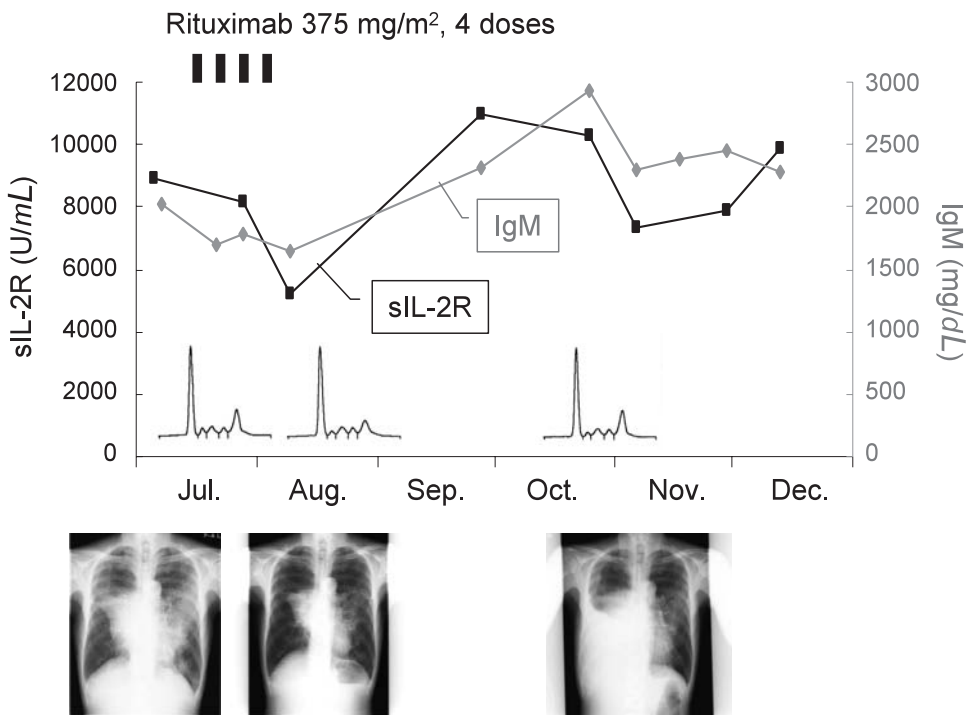


Fig. 1. Positron emission tomography (PET). (**1a**) Case 1. Computed tomography (CT) images (*top*), PET images (*middle*), and fused PET and CT images (*bottom*) are shown. (**1b**) Case 2. The closed and open arrows indicate the accumulation of fluorodeoxyglucose within the gastric wall and mediastinal/hilar lymph nodes, respectively.

immunophenotype, as demonstrated by flow cytometry. Bone marrow smears revealed an increase in the lymphocyte-plasma cell series, which comprised 13.0% of nucleated marrow cells.

Serum protein electrophoresis revealed an M-spike in the γ -globulin region; immunoelectrophoresis detected an M-bow of IgA- κ , which also labeled with an IgM antiserum less intensely than IgA. We also identified the urinary excretion

2a



2b

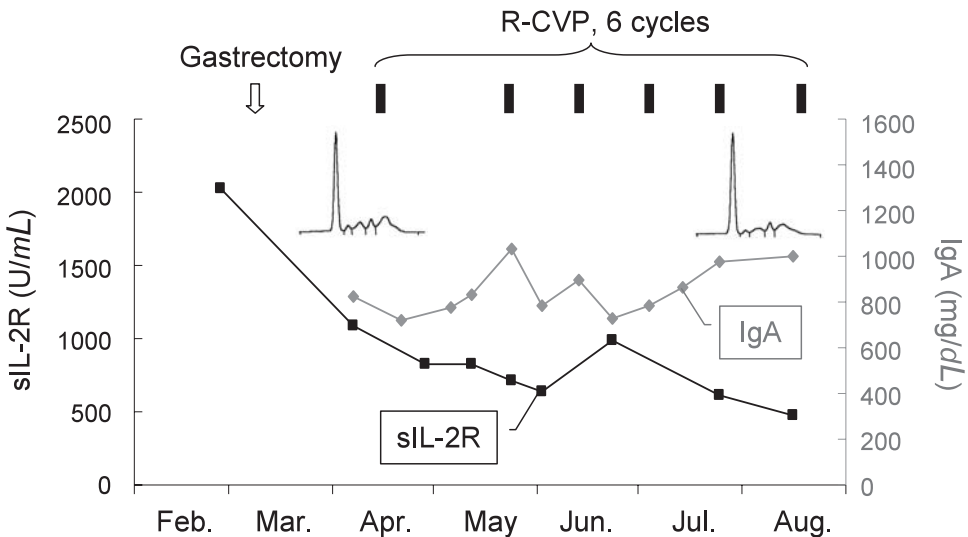
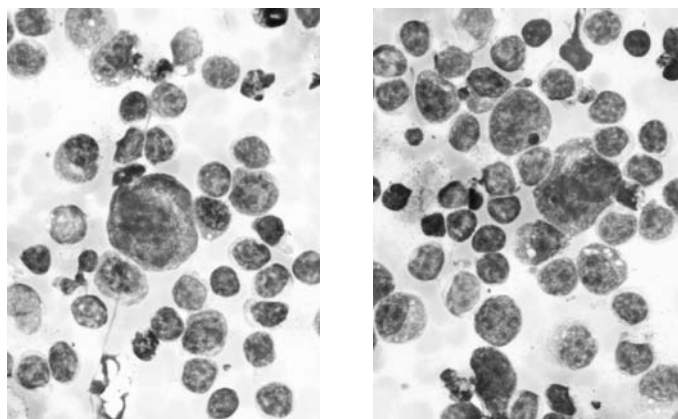


Fig. 2. Treatment courses of cases 1 (2a) and 2 (2b). The soluble interleukin-2 receptor (sIL-2R; normal range, 135 to 438 U/mL), serum IgM (normal range, 32 to 220 mg/dL), and serum IgA (normal range, 110 to 410 mg/dL) levels are shown. The serum electrophoresis patterns for each case are shown in the 2a and 2b insets. Chest radiographs for case 1 are shown at the bottom of 2a. R-CVP: rituximab, cyclophosphamide, vincristine and prednisolone.

3a



3b

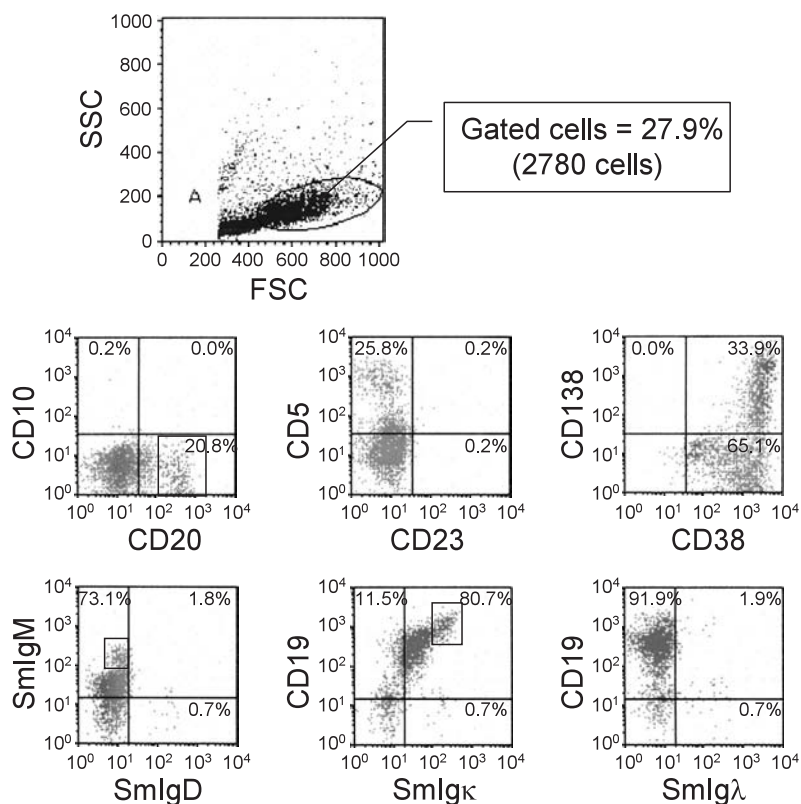


Fig. 3. Characterization of lymphoma cells present in the pleural fluid of case 1. (3a) A few large (*left*) and/or bi-nucleated (*right*) cells were identified. Giemsa staining, x1,000. (3b) Flow cytometric analysis. Forward scatter (FSC) and side scatter (SSC) characteristics of pleural fluid cells are shown at the *top*. Gated cells were subjected to two-color flow cytometry using indicated combinations of antibodies. The boxed CD20⁺ cells expressed surface-membrane (Sm) IgM-κ at higher levels than the excluded cells. The population of low FSC value cells was composed of reactive T-cells.

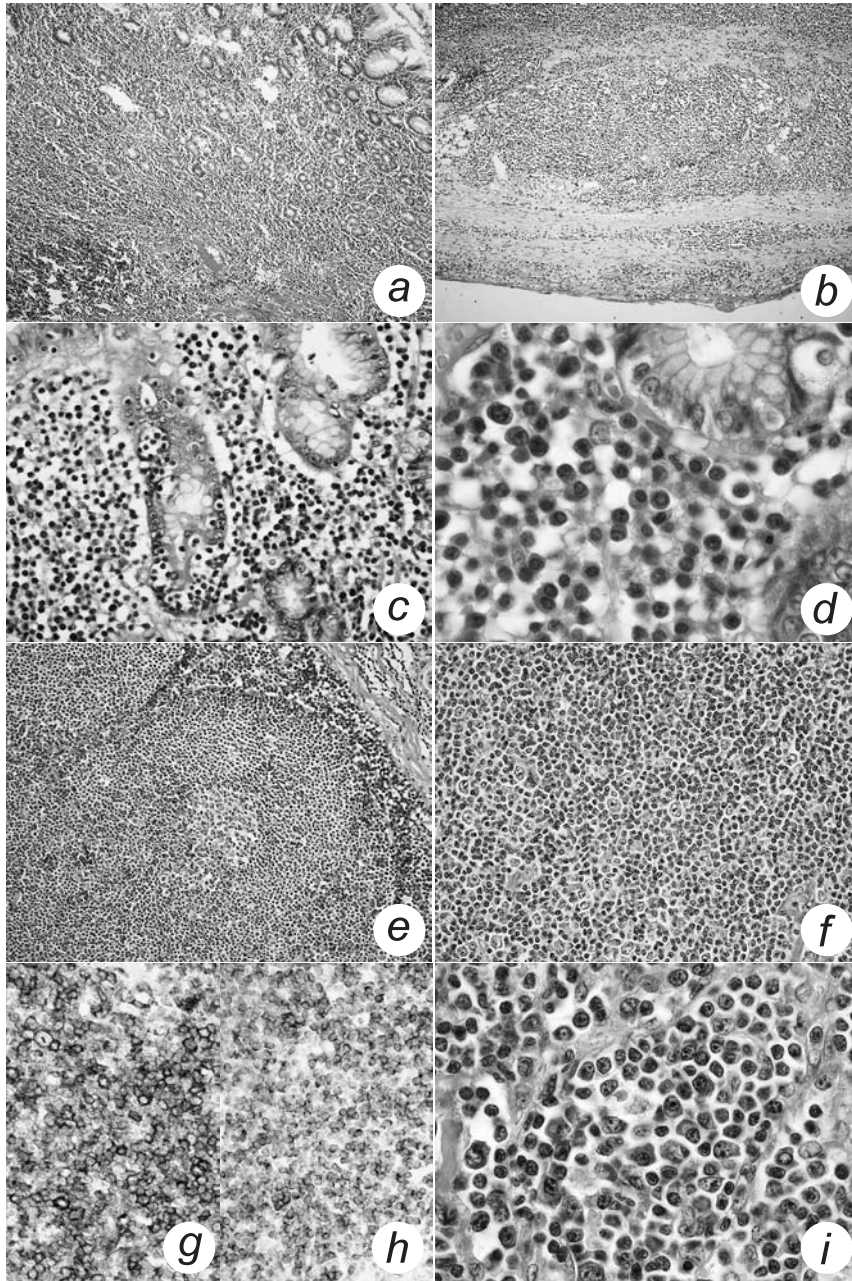


Fig. 4. Histopathology of excised stomach (*4a* through *4d*) and a gastric lymph node (*4e* through *4i*). Staining and magnification with an objective lens : *4a*, HE, x20 ; *4b*, HE, x10 ; *4c*, HE, x40 ; *4d*, HE, x100 ; *4e*, HE, x20 ; *4f*, HE, x40 ; *4g*, anti-CD20 immunostaining, x40 ; *4h*, anti-Bcl-2 immunostaining, x40 ; and *4i*, HE, x100.

of κ light chain. Serum contained 824 mg/dL IgA, 1,209 mg/dL IgG, and 119 mg/dL IgM. The levels of sIL-2R before and after surgery were 2,026 and 1,082 U/mL, respectively.

We made a diagnosis of disseminated gastric MALT lymphoma. The patient was treated with R-CVP (rituximab 375 mg/m² on day 1, cyclophosphamide 750 mg/m² on day 3,

vincristine 1.4 mg/m² on day 3, and prednisolone 100 mg on days 3 through 7) combination therapy every three weeks (Fig. 2b). During the treatment course, the para-aortic lymph nodes and spleen decreased in size, and sIL-2R levels normalized. The M-spike detected by protein electrophoresis and the serum IgA levels, however, were not significantly af-

ected. After six cycles of R-CVP, flow cytometry detected the persistence of monoclonal B-cells in the peripheral blood. The patient refused further treatment and was lost to follow-up.

DISCUSSION

The two cases presented here shared not only the presence of monoclonal Igs and the t(11;18)(q21;q21) but also a long-term asymptomatic period and disseminated disease at presentation. Although the primary sites in each case were different, this clinical presentation may represent a stage in the progression of MALT lymphoma.

Two retrospective studies have examined monoclonal gammopathy in MALT lymphoma.^{3,4} These studies reported similar incidences of monoclonal gammopathy determined by immunoelectrophoresis and/or immunofixation, 36%⁴ and 27%.³ These studies, however, did not agree regarding if there was a correlation between this condition and clinical parameters. One study did not find any correlation between monoclonal gammopathy and clinical stage, *H. pylori* infection, or presence of the t(11;18)(q21;q21), although monoclonal Ig levels decreased significantly in patients responding to chemotherapy or radiation.⁴ In the second study, all patients with extranodal marginal zone lymphomas and concurrent monoclonal gammopathies had stage IV disease; there was a strong correlation between bone marrow involvement and the presence of monoclonal Ig.³ The two cases detailed in this study clearly support the latter report indicating that monoclonal gammopathy correlates with disseminated disease.

It is apparent that the monoclonal Igs seen in these cases were produced by the lymphoma cells, as the heavy chain subclass and the light chain type matched those expressed on the lymphoma cell surface. Thus, the levels of monoclonal Igs were likely proportional to tumor bulk. Although the disease initially appeared to respond to single agent (case 1) or rituximab-containing chemotherapy (case 2), the levels of monoclonal Ig in the serum did not respond appropriately, indicating the persistence of non-responding cells. As evidenced by immunophenotyping of the pleural fluid cells in case 1 and the plasma cell differentiation observed in surgical specimens of case 2, the lymphoma cells in both cases were presumably composed of two populations, a rituximab-sensitive CD20⁺ population and a rituximab-resistant population that had differentiated into the plasma cell stage and lost CD20 expression; the latter population, which was likely responsible for monoclonal Ig production, likely became predominant after treatment with rituximab. Although a large series would be required to determine the prognostic significance of monoclonal Igs in MALT lymphoma, this report suggests that monoclonal gammopathy may indicate a resistance to rituximab therapy.

REFERENCES

- 1 Economopoulos T, Papageorgiou S, Pappa V, Papageorgiou E, Valsami S, Kalantzis D, Xiros N, Dervenoulas J, Raptis S: Monoclonal gammopathies in B-cell non-Hodgkin's lymphomas. *Leuk Res* 27 : 505-508, 2003
- 2 Isaacson PG, Muller-Hermelink HK, Piris MA, Berger F, Nathwani B, Swerdlow S, Harris NL: Extranodal marginal zone B-cell lymphoma of mucosa-associated lymphoid tissue (MALT lymphoma), in Jaffe ES, Harris NL, Stein H, Vardiman JW (eds): World Health Organization Classification of Tumours. Pathology and Genetics of Tumours of Haematopoietic and Lymphoid Tissues. Lyon, IARC Press, 2001, pp.157-160
- 3 Asatiani E, Cohen P, Ozdemirli M, Kessler CM, Mavromatis B, Cheson BD: Monoclonal gammopathy in extranodal marginal zone lymphoma (ENMZL) correlates with advanced disease and bone marrow involvement. *Am J Hematol* 77 : 144-146, 2004
- 4 Wohrer S, Streubel B, Bartsch R, Chott A, Raderer M: Monoclonal immunoglobulin production is a frequent event in patients with mucosa-associated lymphoid tissue lymphoma. *Clin Cancer Res* 10 : 7179-7181, 2004
- 5 Valdez R, Finn WG, Ross CW, Singleton TP, Tworek JA, Schnitzer B: Waldenström macroglobulinemia caused by extranodal marginal zone B-cell lymphoma: a report of six cases. *Am J Clin Pathol* 116 : 683-690, 2001
- 6 Berger F, Traverse-Glehen A, Felman P, Callet-Bauchu E, Baseggio L, Gazzo S, Thieblemont C, Ffrench M, Magaud JP, Salles G, Coiffier B: Clinicopathologic features of Waldenström's macroglobulinemia and marginal zone lymphoma: are they distinct or the same entity? *Clin Lymphoma* 5 : 220-224, 2005
- 7 Hirase N, Yufu Y, Abe Y, Muta K, Shiokawa S, Nawata H, Nishimura J: Primary macroglobulinemia with t(11;18)(q21;q21). *Cancer Genet Cytogenet* 117 : 113-117, 2000
- 8 Iwase S, Takahara S, Sekikawa T, Ito K, Nakada S, Yamazaki Y, Yamada J, Kobayashi M, Yamada H: [Disseminated MALT lymphoma associated with macroglobulinemia]. *Rinsho Ketsueki* 41 : 1183-1188, 2000
- 9 Kunisaki Y, Muta T, Yamano Y, Kobayashi Y: Detection of two cell populations corresponding to distinct maturation stages in API-2/MLT-positive mucosa-associated lymphoid tissue lymphoma cells proliferating in pleural effusion. *Int J Hematol* 78 : 357-361, 2003
- 10 Mehta KU, Ghorab Z, DeVoto E: Waldenström macroglobulinemia caused by extranodal marginal zone B-cell lymphoma. *Am J Clin Pathol* 117 : 495-496, 2002
- 11 Coiffier B: Rituximab therapy in malignant lymphoma. *Oncogene* 26 : 3603-3613, 2007
- 12 Raderer M, Jager G, Brugger S, Puspok A, Fiebigger W, Drach J, Wotherspoon A, Chott A: Rituximab for treatment of advanced extranodal marginal zone B cell lymphoma of the mucosa-associated lymphoid tissue lymphoma. *Oncology* 65 : 306-310, 2003
- 13 Martinelli G, Laszlo D, Ferreri AJ, Pruneri G, Ponzoni M,

Ohno H & Isoda K

Conconi A, Crosta C, Pedrinis E, Bertoni F, Calabrese L, Zucca E : Clinical activity of rituximab in gastric marginal zone non-Hodgkin's lymphoma resistant to or not eligible for anti-*Helicobacter pylori* therapy. J Clin Oncol 23 : 1979-1983, 2005
14 Conconi A, Martinelli G, Thieblemont C, Ferreri AJ, Devizzi L,

Peccatori F, Ponzoni M, Pedrinis E, Dell'Oro S, Pruneri G, Filipazzi V, Dietrich PY, Gianni AM, Coiffier B, Cavalli F, Zucca E : Clinical activity of rituximab in extranodal marginal zone B-cell lymphoma of MALT type. Blood 102 : 2741-2745, 2003