

Case Study

# EBV<sup>+</sup> B-cell Lymphoproliferative Disorder Associated with Subsequent Development of Burkitt Lymphoma in a Patient with Idiopathic CD4<sup>+</sup> T-lymphocytopenia

Masaru Kojima,<sup>1)</sup> Shinji Sakurai,<sup>2)</sup> Yukio Morita,<sup>3)</sup> Naoya Nakamura,<sup>4)</sup> Shiro Sugihara,<sup>5)</sup>  
and Shun-ichi Shimano<sup>6)</sup>

We report here a case of idiopathic CD4<sup>+</sup> T-lymphocytopenia (ICL) associated with Epstein-Barr virus (EBV)<sup>+</sup> lymphoproliferative disorder (LPD) terminating in Burkitt lymphoma (BL). A 33-year-old Japanese male was admitted to the hospital showing severe CD4<sup>+</sup> lymphocytopenia and neutropenia that was diagnosed as ICL in 1993. Twenty months after the onset of disease, right cervical lymphadenopathy was detected. Biopsy of the specimen showed reactive lymph node hyperplasia and interfollicular B-cell hyperplasia. Ninety-one months later, polypoid tumors were resected from the bilateral nasal cavities and were diagnosed as BL. Immunohistological studies suggested the reactive nature of the initial lymph node biopsy specimen. Polymerase chain reaction (PCR) analyses of immunoglobulin heavy-chain gene (*IgH*) demonstrated a polyclonal pattern in the initial lymph node lesion. However, the subsequent BL demonstrated a clonal band in the PCR assay for the *IgH* gene. As demonstrated in human immunodeficiency virus (HIV)-patients, clonal expansion of EBV infected B-cells in the initial lymph node lesion may progress to BL in this patient. The present case did not associate with severe opportunistic infections during the course of disease. EBV<sup>+</sup> BL may be the first manifestation of severe immunodeficiency of the ICL in this patient. [*J Clin Exp Hematopathol* 48(2) : 55-59, 2008]

**Keywords:** CD4<sup>+</sup> T-lymphocytopenia, Epstein-Barr virus, lymphoproliferative disorder, polymerase chain reaction

## INTRODUCTION

The Centers for Disease Control has applied the term idiopathic CD4<sup>+</sup> lymphocytopenia (ICL) to describe rare patients in whom no detectable cause of low CD4<sup>+</sup> T-cell counts can be found.<sup>1-4</sup> The criteria for diagnosing ICL requires < 300 × 10<sup>9</sup>/L CD4<sup>+</sup> T-cells or a CD4<sup>+</sup> T-cell count < 20% of total T-lymphocytes on two occasions, no evidence of human

immunodeficiency virus (HIV) or -2, (HTLV)-1 or 2 infection, and no other cause of immunosuppression.<sup>1-4</sup>

ICL appears to be a rare disorder. Patients with ICL may be asymptomatic, have a mildly idiopathic opportunistic infection such as herpes or candidiasis, or present with severe opportunistic infections such as cryptococcal meningitis, pneumocystis pneumonia, or tuberculosis. Many of these clinical findings are similar to the clinical presentation of HIV infections, but there is a difference. In HIV-infections, the risk of non-Hodgkin lymphoma is between 60 and 100 times the expected rate.<sup>5,6</sup> Moreover, the majority of these cases demonstrated Epstein-Barr virus (EBV)<sup>+</sup> B-cell lymphomas.<sup>5,6</sup> However, in the English literature, non-Hodgkin lymphomas have rarely been reported in ICL.<sup>7-12</sup> We present here a case of EBV<sup>+</sup> lymphoproliferative disorder (LPD) associated with subsequent development of Burkitt lymphoma (BL) in a patient with ICL.

## CASE REPORT

The clinical findings of this case have previously been presented in detail.<sup>13</sup>

A 33-year-old Japanese male was admitted to our hospital

Received : October 2, 2007

Revised : February 15, 2008

Accepted : June 19, 2008

<sup>1)</sup>Department of Pathology and Clinical Laboratories, Gunma Cancer Center Hospital, Ohta, Japan

<sup>2)</sup>Department of Tumor Pathology, Graduate School of Medicine, Gunma University Maebashi, Japan

<sup>3)</sup>Gunma Prefectural Institute of Public Health and Environmental Science, Maebashi, Japan

<sup>4)</sup>Department of Pathology, Tokai University School of Medicine, Isehara, Japan

<sup>5)</sup>Department of Pathology, Gunma Health Foundation, Maebashi, Japan

<sup>6)</sup>Department of Internal Medicine, Keiicho Hospital, Midori, Japan

Address correspondence and reprint request to Masaru Kojima, M.D., Department of Pathology and Clinical Laboratories, Gunma Cancer Center Hospital, 617-1, Takabayashinishi-cho Ohta, 373-8550, Japan

E-mail : mkojima@gunma-cc.jp

because severe neutropenia in July 1985. At that time, abnormal laboratory findings were a white blood cell count of  $2.2 \times 10^9/L$  (neutrophils =  $0.055 \times 10^9/L$ ,  $CD4^+$  T-lymphocytes =  $0.128 \times 10^9/L$ , and CD4/CD8 ratio = 0.1). Serum immunoglobulin levels were in the normal range. During the course of disease, repeated examinations of  $CD4^+$  T-lymphocyte counts demonstrated a count below  $0.3 \times 10^9/L$  between 1985 and 1993 on five of nine examinations performed. Serological tests for HIV-1/2 and HTLV-1/2 were negative, and there were no risk factors for HIV infection. The etiology of neutropenia was unknown, and the neutropenia was sustained during the course of disease. The present case did not associate with severe opportunistic infection during the course of disease. In March 1991, he demonstrated EBV infection. At that time, abnormal serologic tests for EBV showed serological findings, suggesting reactivation of EBV (a viral capsid antigen IgG titer of 1 : 2,560 and an early antigen titer of 1 : 80).<sup>14</sup> However, there was no atypical lymphocytosis of peripheral blood. In May 1991, right-sided cervical lymphadenopathy was found. A lymph node biopsy was performed, and was diagnosed as reactive change. Thereafter, lymphadenopathy spontaneously regressed. In February 1994, polypoid tumors were resected from bilateral nasal cavities and diagnosed as BL. He was treated with a modified COPBLAM III (cyclophosphamide, oncovin, prednisone, bleomycin, adriamycin, and matulane), but died in July 1994. An autopsy demonstrated tumor cell infiltration in multiple organs.

## MATERIALS AND METHODS

Tissue specimens from lymph node biopsy and nasal tumors were fixed in formalin, routinely processed and embedded in paraffin. For light microscopic examination, the sections were stained with hematoxylin-eosin (HE).

Immunohistochemical studies were performed using the Ventana automated (BenchMark<sup>TM</sup>) stainer according to the manufacturer's instructions. A panel of antibodies included human immunoglobulin light chains ( $\kappa$  and  $\lambda$ ) (Novocastra, Newcastle Upon Tyne, UK), PS-1 (CD3; Immunotech, Marseille, France), 4C7 (CD5; Novocastra), 56C6 (CD10; Novocastra), L26 (CD20; Dako A/S, Glostrup, Denmark), 124 (bcl-2; Dako), Ki-67 (MIB-1; Dako), CS.1-4 (latent membrane protein-1 [LMP-1]; Novocastra), and PE2 (EBV-encoded nuclear antigen-2 [EBNA2]; Novocastra). Sections with known reactivity for the antibodies assayed served as positive controls and the sections treated with normal rabbit and mouse-serum served as negative controls.

*In situ* hybridization (ISH) with EBV-encoded small RNA (EBER) oligonucleotides was performed to test for the presence of EBV small RNA in the formalin-fixed paraffin-embedded sections using a Ventana automated (BenchMark<sup>TM</sup>) stainer.

Paraffin-embedded tissues from the biopsy specimen were prepared for polymerase chain reaction (PCR), and rearranged immunoglobulin heavy-chain (*IgH*) genes were amplified using the seminested PCR method as described by Wan *et al.*<sup>15</sup>

Formalin-fixed, paraffin-embedded tissue was selected based on its pathology as determined by HE stain. To generate templates for PCR, we purified the DNA obtained from tissue using a commercial kit (DEXPAT, Takara, Tokyo, Japan). To identify EBV, we performed a comparative sequence analysis of the EBV genome.<sup>16</sup> For genomic amplification, we used a set of previously reported primers: BAM-HIW forward primer (5'-CCC AAC ACT CCA CCA CAC C-3') and the reverse primer (5'-TCT TAG GAG CTG TCC GAG GG-3') (theoretical amplicon of 76 nt).<sup>16</sup> The PCR reaction mixture contained 2  $\mu$ L of template DNA, 1  $\mu$ L of the BAM-HIW forward primer and reverse primers (20 pmol each), 12.5  $\mu$ L of PCR Master Mix (Promega, Madison, WI), and 8.5  $\mu$ L of distilled water free from DNase and RNase (total volume, 25  $\mu$ L). The PCR protocol included incubation for 3 min at 95°C, followed by 35 cycles at 95°C for 30 sec, at 60°C for 30 sec, at 72°C for 45 sec, and an additional 5 min for elongation at 72°C after the last cycle. The sizes of the amplified DNA fragments were confirmed by electrophoresis on a 3.0% agarose gel. After purification of the DNA fragments with a QIAquick PCR purification kit (Qiagen GmbH, Hilden, Germany), the 76-bp nucleotide sequence, which included the target gene, was determined using an automated DNA sequencer (ABI 310 DNA sequencer, Applied Biosystems, Foster City, CA) and a Dye Terminator Cycle Sequencing Ready Reaction Kit (Applied Biosystems). Nucleotide sequences (37-bp) of the amplicon (76-bp) were analyzed genetically using the BLAST program (<http://www.ddbj.nig.ac.jp/search/blast-e.html>) provided by the DNA Data Bank of Japan (DDBJ) home page.

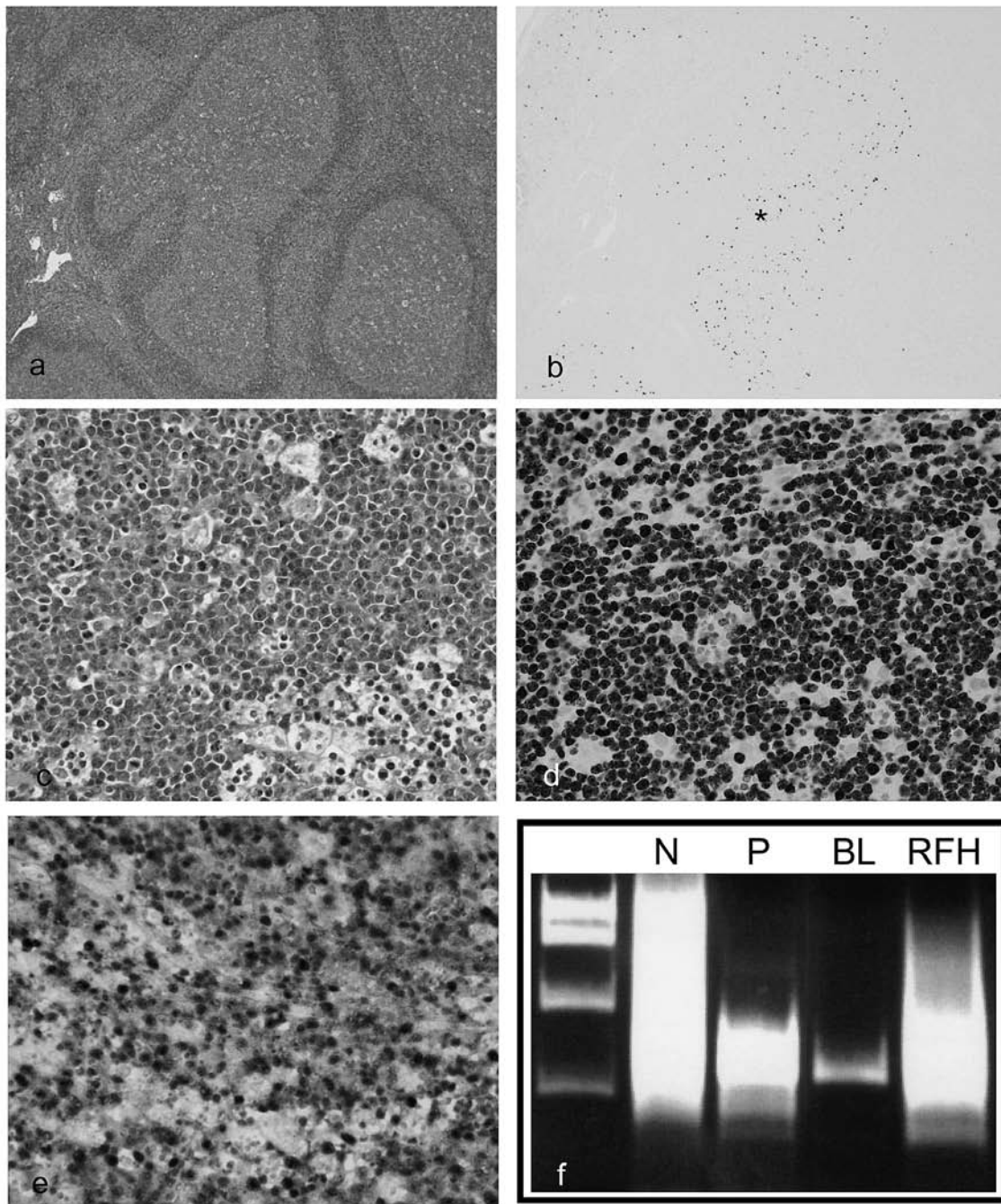
## RESULTS

### *Pathological, immunohistochemical and ISH findings*

#### *Lymph node biopsy specimen*

On low power field, the lesion was characterized by numerous enlarged, bizarre-shaped coalescing lymphoid follicles with distortion rather than effacement of the lymph node architecture (Fig. 1a). The paracortical area and lymphoid sinus were compressed by enlarged follicles. However, tingible-body macrophages were numerous and polarization was seen in the lymphoid follicles. Various numbers of germinal centers had undergone follicular lysis. Monocytoid B-lymphocyte foci were observed located next to blood vessels and sinuses.

Immunohistochemical study demonstrated that lymphoid follicles and monocytoid B-lymphocyte were positive for CD20. Staining with CD20, CD3, and CD5 showed a mixed



**Fig. 1.** (*1a*) Low power field of the initial lymph node biopsy specimen. The lesion was characterized by numerous enlarged, atypically-shaped coalescing lymphoid follicles with distortion rather than effacement of the lymph node architecture. HE, x10. (*1b*) Approximately 100 EBER-positive cells had small- to- large nuclei and were located both in the interfollicular area and in the lymphoid follicles. EBER, x10. (*1c*) High-power field of the nasal tumor. Medium-sized cells showed a monotonous proliferation accompanied by a starry-sky appearance. The tumor cells had round nuclei with multiple basophilic small nucleoli and intensely basophilic cytoplasm. HE, x100. (*1d*) Immunohistochemistry. Nearly 100% of the tumor cells were Ki-67<sup>+</sup>. x100. (*1e*) ISH. Note the numerous EBER<sup>+</sup> cells. x100. (*1f*) PCR analysis for clonal immunoglobulin heavy chain rearrangement. The lanes contain molecular-weight markers, negative control (*N*), polyclonal control (*P*), Burkitt lymphoma (*BL*), and initial lymph node biopsy (*RFH*).



nature of the small- and medium-sized lymphocytes, and immunoblasts in the interfollicular area. B-cells in the germinal centers and a nest of MBLs were both bcl-2 negative, while bcl-2 positivity was expressed in mantle zone B-cells.<sup>17</sup> CD10<sup>+</sup> large lymphoid cells were confined strictly to the germinal centers. Immunohistochemical studies of light chain determinants for germinal center and MBLs demonstrated a polyclonal pattern.<sup>17</sup> There were no LMP-1<sup>+</sup>, EBNA-2<sup>+</sup> cells in the lesion.

Approximately 100 EBER-positive cells had small to large nuclei and were located both in the interfollicular area and in the lymphoid follicles (Fig. 1b).

#### *Nasal tumor*

Histologically, the medium-sized cells from the nasal tumor showed monotonous proliferation accompanied by numerous mitoses and apoptotic bodies (starry-sky appearance) (Fig. 1c). The tumor cells had round nuclei with multiple basophilic small sized nucleoli and deeply basophilic cytoplasm.

Immunohistochemical studies demonstrated that tumor cells were CD3<sup>-</sup>, CD5<sup>-</sup>, CD10<sup>+</sup>, CD20<sup>+</sup>, bcl-2<sup>-</sup>, and cytoplasmic immunoglobulin<sup>-</sup>. Nearly 100% of the tumor cells were Ki-67<sup>+</sup> (Fig. 1d). The results of LMP-1 and EBNA-2 expression were not evaluated.

ISH study demonstrated that numerous EBER<sup>+</sup> tumor cells (Fig. 1e). Histological, immunohistochemical and EBV findings of the nasal tumor were compatible with BL.<sup>18</sup> The rearrangement of *c-myc* oncogene and study of the chromosomal abnormalities were not examined.

#### ***Molecular genetic studies for the IgH gene***

PCR analyses for *IgH* gene demonstrated polyclonal pattern in the initial lymph node lesion. However, the subsequent BL demonstrated clonal band in the PCR assay for the *IgH* gene (Fig. 1f).

#### ***Molecular genetic studies for EBV***

The 76-bp of amplicon was detected by PCR from the initial lymph node lesion and the subsequent BL, and the gene sequences of both samples were identified as EBV. In addition, partial sequence of gene from both samples was completely matched the EBV genome, strain B95-8 (GenBank accession no. V01555).

## **DISCUSSION**

LPDs, congenital or acquired, that mimic and/or lead to lymphoma can occur in patients with immunodeficiencies including AIDS.<sup>5,6</sup> Notably, EBV is often associated with each type of immunodeficiency-associated LPD.<sup>5,6</sup> However,

only a few cases of non-Hodgkin lymphoma occurring in ICL patients in the English literature.<sup>7-12</sup> Moreover, to our knowledge, only two cases of EBV<sup>+</sup> NHL occurring in an ICL patient have been reported including the present case.<sup>12</sup> During the course of disease, the present case under discussion fulfilled the diagnostic criteria for ICL including ; (i) < 300 × 10<sup>9</sup>/L CD4<sup>+</sup> T-cells on five occasion ; (ii) no evidence of HIV-1 or -2, HTLV-1 or -2 infection, and (iii) no other cause of CD4<sup>+</sup> T-cell cytopenia.<sup>1-4</sup>

HIV-infected patients are also at increased risk for developing reactive lymphadenopathy designated as persistent generalized lymphadenopathy (PGL).<sup>5</sup> In the early phase of PGL, histology of the enlarged lymph node consists of a benign but florid follicular and interfollicular B-cell hyperplasia.<sup>5</sup> Interestingly, using ISH and PCR, Shibata *et al.* demonstrated that HIV infected patients containing EBV genomes in the early phase of PGL were associated with subsequent development of EBV<sup>+</sup> B-cell lymphoma including BL.<sup>19</sup> The initial lymph node biopsy specimen from this case showed florid follicular and interfollicular B-cell hyperplasia. ISH studies demonstrated approximately 100 EBER<sup>+</sup> lymphocytes in both the interfollicular area and lymphoid follicles. Immunohistological studies suggested the reactive nature of the initial lymph node biopsy specimen. PCR analyses for *IgH* genes demonstrated a polyclonal pattern in the initial lymph node lesion. However, the subsequent BL demonstrated clonal band in the PCR assay for the *IgH* gene. PCR analyses for EBV-genomes demonstrated the same single clonal infection of EBV in the initial lymph node lesion and the second nasal tumor. As Shibata *et al.* demonstrated in an HIV-patient, clonal expansion of EBV infected B-cells in the initial lymph node lesion in this patient may progress to BL in this patient.<sup>19</sup> However, PCR analysis for clonal EBV infection was not performed in this case.

A number of observations suggest that clinical distinctions exist among AIDS-related B-cell lymphomas according to their histopathological findings. AIDS-related BL may develop in the presence of relatively sustained peripheral blood CD4<sup>+</sup> T-cell levels and may be the first manifestation of AIDS in a significant fraction of cases.<sup>20-22</sup> On the other hand, AIDS-related diffuse large B-cell lymphoma tends to develop in the presence of low CD4 counts and is frequently a late manifestation of AIDS. The present case did not associate with severe opportunistic infection during the course of disease. EBV<sup>+</sup>BL may be the first manifestation of severe immunodeficiency of the ICL in this patient. However, at the onset of BL, peripheral blood CD4<sup>+</sup> T-cell count was not examined. Moreover, EBV<sup>+</sup> AIDS-related BL fail to express EBV transforming antigen EBNA-2 and LMP-1.<sup>21,22</sup> The tumor cells of the present case also EBNA-2<sup>-</sup> and LMP-1<sup>-</sup>.

The present case indicates that EBV<sup>+</sup> B-cell lymphomas occur in patients with ICL as well as in AIDS patients.

## REFERENCES

- 1 Smith DK, Neal JJ, Holmberg SD : Unexplained opportunistic infections and CD4<sup>+</sup> T-lymphocytopenia without HIV infection. An investigation of cases in the United States. The Centers for Disease Control Idiopathic CD4<sup>+</sup> T-lymphocytopenia Task Force. *N Eng J Med* 328 : 373-379, 1993
- 2 Ho DD, Cao Y, Zhu T, Farthing C, Wang N, Gu G, Schooley RT, Daar ES : Idiopathic CD4<sup>+</sup> T-lymphocytopenia - immunodeficiency without evidence of HIV infection. *N Eng J Med* 328 : 380-385, 1993
- 3 Spira TJ, Jones BM, Nicholson JK, Lal RB, Rowe T, Mawle AC, Lauter CB, Shulman JA, Monson RA : Idiopathic CD4<sup>+</sup> T-lymphocytopenia - an analysis of five patients with unexplained opportunistic infections. *N Eng J Med* 328 : 386-392, 1993
- 4 Duncan RA, von Reyn CF, Alliegro GM, Toossi Z, Sugar AM, Levitz SM : Idiopathic CD4<sup>+</sup> T-lymphocytopenia - four patients with opportunistic infections and no evidence of HIV infection. *N Eng J Med* 328 : 393-398, 1993
- 5 Knowles DM, Chadburn A : Lymphadenopathy and the lymphoid neoplasms associated with the acquired immune deficiency syndrome. Knowles DM (ed). *Neoplastic Hematopathology*, 2nd ed. Lippincott Williams & Wilkins, Baltimore. pp.987-1089, 2000
- 6 Feller AC, Diebold JJ : *Histopathology of Nodal and Extranodal Non-Hodgkin's Lymphomas*, Springer, Berlin, pp.379-395, 2004
- 7 Quiles I, Anaut P, Cibrián F, Gainzarán J, Vega L, Andía A : Idiopathic CD4<sup>+</sup> T-lymphocytopenia with opportunistic infection and non-Hodgkin's lymphoma. *J Intern Med* 238 : 183-184, 1995
- 8 Paolini R, D'Andrea E, Poletti A, Del Mistro A, Zerbinati P, Girolami A : B non-Hodgkin's lymphoma in a haemophilia patient with idiopathic CD4<sup>+</sup> T-lymphocytopenia. *Leuk Lymphoma* 21 : 177-180, 1996
- 9 Hanamura I, Wakita A, Harada S, Tsuboi K, Komatsu H, Banno S, Iwaki O, Takeuchi G, Nitta M, Ueda R : Idiopathic CD4<sup>+</sup> T-lymphocytopenia in a non-Hodgkin's lymphoma patient. *Intern Med* 36 : 643-646, 1997
- 10 Campbell JK, Prince HM, Juneja SK, Seymour JF, Slavin M : Diffuse large cell lymphoma t(8;22)(q24;q11) in a patient with idiopathic CD4<sup>+</sup> T-lymphocytopenia. *Leuk Lymphoma* 41 : 421-423, 2001
- 11 Busse PJ, Cunningham-Rundles C : Primary leptomeningeal lymphoma in a patient with concomitant CD4<sup>+</sup> lymphocytopenia. *Ann Allergy Asthma Immunol* 88 : 339-342, 2002
- 12 Kanno H, Sasaki M, Kumagai H, Endo M, Chida S, Sawai T : Epstein-Barr virus-positive malignant lymphoma of salivary gland developing in an infant with selective depletion of CD4-positive lymphocytes. *Leuk Lymphoma* 48 : 183-186, 2007
- 13 Shimano S-I, Murata N, Tsuchiya J : Idiopathic CD4<sup>+</sup> T-lymphocytopenia terminating in Burkitt's lymphoma. *Jpn J Clin Hematol* 38 ; 599-603, 1997 (*in Japanese*)
- 14 Henle W, Henle GE, Horwitz CA : Epstein-Barr virus specific diagnostic tests in infectious mononucleosis. *Hum Pathol* 5 : 551-565, 1974
- 15 Wan JH, Trainor KJ, Brisco MJ, Morley AA : Monoclonality in B cell lymphoma detected in paraffin wax embedded sections using the polymerase chain reaction. *J Clin Pathol* 43 ; 888-890, 1990
- 16 Perkins RS, Sahm K, Marando C, Dickson-Witmer D, Pahnke GR, Mitchell M, Petrelli NJ, Berkowitz IM, Soteropoulos P, Aris VM, Dunn SP, Krueger LJ : Analysis of Epstein-Barr virus reservoirs in paired blood and breast cancer primary biopsy specimens by real time PCR. *Breast Cancer Res* 8 : R70, 2006 (doi : 10.1186/bcr1627)
- 17 Dogan A, Bagdi E, Munson P, Isaacson PG : CD10 and BCL-6 expression in paraffin sections of normal lymphoid tissue and B-cell lymphomas. *Am J Surg Pathol* 24 : 846-852, 2000
- 18 Diebold J, Jaffe ES, Raphael M, Warnke RA : Burkitt lymphoma. In : Jaffe ES, Harris NL, Stein H, Vardiman JW (eds) : *Pathology and Genetics of Tumours of Haematopoietic and Lymphoid Tissues*. IARC Press, Lyon, pp.181-184, 2001
- 19 Shibata D, Weiss LM, Nathwani BN, Brynes RK, Levine AM : Epstein-Barr virus in benign lymph node biopsies from individuals infected with the human immunodeficiency virus is associated with concurrent or subsequent development of non-Hodgkin's lymphoma. *Blood* 77 : 1527-1533, 1991
- 20 Roithmann S, Tourani JM, Andrieu JM : AIDS-associated non-Hodgkin lymphoma. *Lancet* 338 : 884-885, 1991
- 21 Carbone A, Tirelli U, Gloghini A, Volpe R, Boiocchi M : Human immunodeficiency virus-associated systemic lymphomas may be subdivided into two main groups according to Epstein-Barr viral latent gene expression. *J Clin Oncol* 11 : 1674-1681, 1993
- 22 Gaidano G, Carbone A, Dalla-Favera R : Pathogenesis of AIDS-related lymphomas : molecular and histogenetic heterogeneity. *Am J Pathol* 152 : 623-630, 1998