

Short Communication

IgG Type Multiple Myeloma and Concurrent IgA Type Monoclonal Gammopathy of Undetermined Significance Complicated by Necrotizing Skin Ulcers due to Type I Cryoglobulinemia

Soranobu Ninomiya, Kenji Fukuno, Nobuhiro Kanemura, Naoe Goto, Senji Kasahara,
Toshiki Yamada, Hisashi Tsurumi, and Hisataka Moriwaki

A 61-year-old male who worked as a frozen chicken processor was referred to us with necrotizing skin ulcers on his hands and feet. Serum IgG and IgA levels were 4,355 mg/dl and 605 mg/dl, respectively. Serum immunoelectrophoresis demonstrated M-bands for anti-IgG λ and anti-IgA κ . Bone marrow aspirate revealed approximately 31% atypical plasma cells. Cryoglobulin was identified in his serum. Cryoglobulin immunoelectrophoresis revealed monoclonal IgG λ paraproteins. The diagnosis was IgG λ type multiple myeloma and concurrent IgA κ type monoclonal gammopathy of undetermined significance with type I cryoglobulinemia. A skin biopsy taken from an involved site showed amorphous eosinophilic material occluding small vessel lumens. There was a good response after one cycle of chemotherapy consisting of vincristine, adriamycin and dexamethasone (VAD). There was a concurrent decrease in serum cryoglobulin levels; this was associated with re-epithelialization of skin ulcers. Two years later, multiple myeloma progressed during a maintenance therapy of melphalan and prednisolone. Treatment with bortezomib following VAD resulted in a transient response. Serum IgG levels increased to 7,200 mg/dl, in contrast to a decrease in IgA levels to 7 mg/dl. The increase corresponded with the reappearance of skin ulcers. Shortly thereafter, the patient died of multiple myeloma. [*J Clin Exp Hematopathol* 50(1) : 71-74, 2010]

Keywords: cryoglobulin, skin ulcer, myeloma, biclonal gammopathy

INTRODUCTION

Cryoglobulins are proteins that precipitate at reduced temperatures and redissolve when the temperature is raised. Cutaneous manifestations, including ulceration and necrosis in 5-25% of patients, are the major clinical presentations of cryoglobulinemia.^{1,2} Cryoglobulinemia may be a primary disorder or associated with an underlying hematological, autoimmune or chronic infectious disease. In 6 to 10% of patients, cryoglobulinemia is associated with multiple myeloma.^{1,3} Multiple myeloma, characterized by a neoplastic expansion of plasma cells, is typically a monoclonal gammopathy but biclonal gammopathy is seen in 2% of patients.⁴ The clinical

features of biclonal gammopathy are similar to those of monoclonal gammopathy. There have been few reports of biclonal gammopathy with cryoglobulinemia.⁵ Here, we report a case of IgG λ type multiple myeloma and concurrent IgA κ type monoclonal gammopathy of undetermined significance (MGUS) complicated by necrotizing skin ulcers due to type I cryoglobulinemia.

CASE REPORT

A 61-year-old male who worked as a frozen chicken processor was referred to us in December 2005 with necrotizing skin ulcers on his hands and feet (Fig. 1A, 1B). Laboratory findings were as follows: leukocyte count, $7.0 \times 10^9/L$; hemoglobin, 9.9 g/dL; platelet count, $264 \times 10^9/L$; total protein, 10.0 g/dL; albumin, 3.0 g/dL; creatinine, 0.7 mg/dL; calcium, 8.6 mg/dL; C-reactive protein, 5.5 mg/dL; IgG, 4,355 mg/dL; IgA, 605 mg/dL; IgM, 39 mg/dL; β_2 -microglobulin, 4.0 mg/dL; fibrin/fibrinogen degradation products, 28.8 $\mu g/mL$; D-dimer, 14.7 $\mu g/mL$. Serum protein electrophoresis on cellulose acetate membranes showed an M-

Received : November 6, 2008

Revised : March 29, 2009

Accepted : April 27, 2009

First Department of Internal Medicine, Gifu University Graduate School of Medicine, Gifu, Japan

Address correspondence and reprint requests to Hisashi Tsurumi, M.D., First Department of Internal Medicine, Gifu University Graduate School of Medicine, 1-1 Yanagido, Gifu 501-1194, Japan, E-mail : htsuru@gifu-u.ac.jp

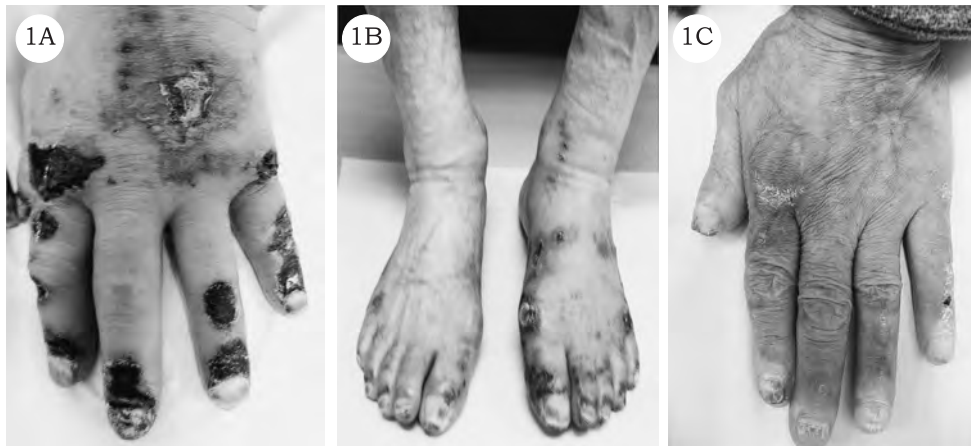

Fig. 1. Skin findings before and after chemotherapy. (*1A, 1B*) The hands and feet were swollen. On the dorsum, ulceration with black crusting and a reddish hue of the surrounding skin was observed. (*1C*) Skin ulcers were re-epithelialized after one cycle of vincristine, adriamycin and dexamethasone.

band in the γ region. Serum immunoelectrophoresis demonstrated M-bows for anti-IgG, anti-IgA, anti- λ and anti- κ , indicating IgG λ and IgA κ paraproteins (Fig. 2A). Urine immunoelectrophoresis was negative for Bence Jones protein. Bone marrow aspirate revealed approximately 31% atypical plasma cells. Flow cytometric analysis of bone marrow mononuclear cells in CD38-strong positive fractions showed 1.5% cytoplasmic $\kappa^+\lambda^+$, 42.9% $\kappa^+\lambda^+$ and 5.5% $\kappa^+\lambda^-$ cells. Cryoglobulin was identified in his serum with the cryocrit at 20%. Characteristically, precipitation of the cryoglobulin began at about 18°C and dissolved at temperatures over 30°C. Cryoglobulin immunoelectrophoresis revealed monoclonal IgG λ paraproteins (Fig. 2B). Computed tomography scan showed a compression fracture of the lumbar vertebra. Bone scintigram revealed an abnormal uptake in multiple bones. A skin biopsy taken from an involved site showed an inflammatory infiltrate and amorphous eosinophilic material occluding small vessel lumens (Fig. 3). The diagnosis was IgG λ type multiple myeloma (Durie-Salmon, stage II; International Staging System, stage II) and concurrent IgA κ type MGUS with type I cryoglobulinemia. The patient received chemotherapy consisting of vincristine, adriamycin and dexamethasone (VAD), and local and systemic administration of prostaglandin preparations. There was a good response after one cycle of VAD, with a decrease in serum IgG and IgA levels to 1,320 mg/dL and 355 mg/dL, respectively. There was a concurrent decrease in serum cryoglobulin levels, which was associated with re-epithelialization of skin ulcers (Fig. 1C). Two years later, multiple myeloma progressed during a maintenance therapy of melphalan and prednisolone. Serum cryoglobulin was positive. Treatment with bortezomib following VAD resulted in a transient response. Serum IgG levels

increased to 7,200 mg/dL in contrast to a decrease in IgA levels to 7 mg/dL in December 2008. At that point, skin ulcers reappeared. Shortly thereafter, the patient died of multiple myeloma.

DISCUSSION

Compared with type II and III cryoglobulinemia, ulceration and hyaline thrombosis associated with a high circulating cryoglobulin level (cryocrit > 20%) were more common in type I cryoglobulinemia.² Berliner *et al.* speculated that occlusion of small cutaneous blood vessels by cryoglobulin aggregates may play a role in the development of skin ulceration.⁶ In our patient, the cryocrit was 20% and small vessel occlusion was seen. This suggested that cryoglobulin aggregates may have contributed to the development of necrotizing skin ulcers. Temperature, pH, protein concentration and ionic strength affect the cold insolubility of cryoglobulins.^{7,8} As such, cold exposure related to the patient's occupation may have promoted cryoglobulin aggregates. Reappearance of skin ulcers at the time of an increase in serum IgG levels indicates a possible connection with cryoglobulin concentration.

Apart from IgM paraproteins, IgA proteins may also cause hyperviscosity syndrome. A possible explanation for this is the tendency of IgA paraproteins to form polymers. However, the effect of IgA paraproteins on cryoprecipitation is not certain. The presence of IgA paraproteins might not affect cryoglobulin aggregates since normal pooled human γ G-globulin and non-cryoprecipitating γ M-globulin from a patient with Waldenström's macroglobulinemia caused a decrease in cryoprecipitability.⁸ Because serum IgA levels were

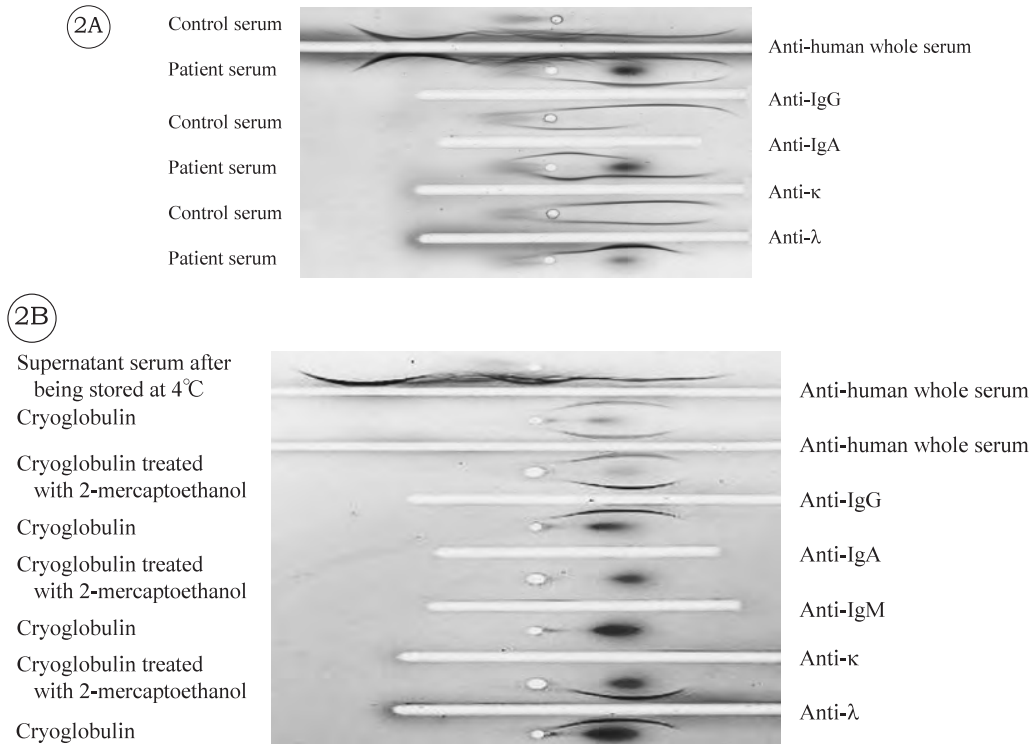


Fig. 2. Immunoelectrophoresis of serum and cryoglobulin solution. (2A) Serum immunoelectrophoresis showing M-bows detected by anti-IgG, anti-IgA, anti-κ and anti-λ antibodies, respectively. (2B) Immunoelectrophoresis of cryoglobulin showing M-bows detected by anti-IgG and anti-λ antibodies, respectively.

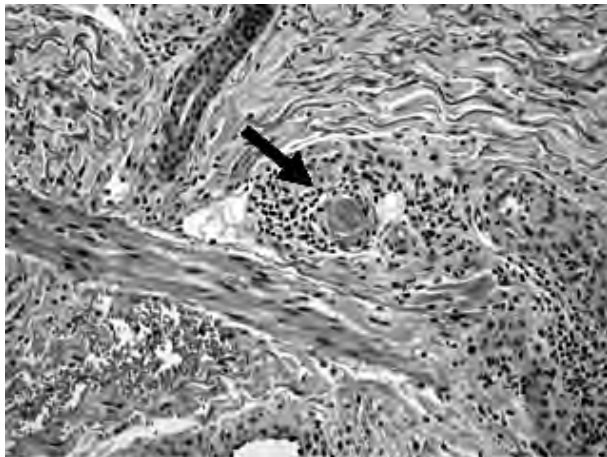


Fig. 3. Histopathology of the skin biopsy showed small vessel lumens occluded by an amorphous eosinophilic material (arrow). H&E stain, original magnification, ×200.

very low when skin ulcers reappeared, IgG cryoglobulin aggregates probably had nothing to do with IgA paraproteins. Further cases are necessary to clarify whether there is any influence of biclonal gammopathy on the cutaneous manifestations in cryoglobulinemia.

REFERENCES

- 1 Brouet JC, Clauvel JP, Danon F, Klein M, Seligmann M : Biologic and clinical significance of cryoglobulins. A report of 86 cases. *Am J Med* 57 : 775-788, 1974
- 2 Cohen SJ, Pittelkow MR, Su WP : Cutaneous manifestations of cryoglobulinemia : clinical and histopathologic study of seventy-two patients. *J Am Acad Dermatol* 25 : 21-27, 1991
- 3 Gorevic PD, Kassab HJ, Levo Y, Kohn R, Meltzer M, *et al.* : Mixed cryoglobulinemia : clinical aspects and long-term follow-up of 40 patients. *Am J Med* 69 : 287-308, 1980
- 4 Kyle RA, Gertz MA, Witzig TE, Lust JA, Lacy MQ, *et al.* : Review of 1027 patients with newly diagnosed multiple myeloma. *Mayo Clin Proc* 78 : 21-33, 2003
- 5 Kyle RA, Robinson RA, Katzmann JA : The clinical aspects of biclonal gammopathies. Review of 57 cases. *Am J Med* 71 : 999-1008, 1981

Ninomiya S, et. al.

- 6 Berliner S, Weinberger A, Ben-Bassat M, Idesess C, Hazaz B, *et al.* : Small skin blood vessel occlusions by cryoglobulin aggregates in ulcerative lesions in IgM-IgG cryoglobulinemia. *J Cutan Pathol* 9 : 96-103, 1982
- 7 Grey HM, Kohler PF : Cryoimmunoglobulins. *Semin Hematol* 10 : 87-112, 1973
- 8 Andersen BR, Tesar JT, Schmid FR, Haisty WK, Hartz WH Jr : Biological and physical properties of a human γ M-cryoglobulin and its monomer subunit. *Clin Exp Immunol* 9 : 795-807, 1971