

Case Study

CD56⁺ Angioimmunoblastic T-Cell Lymphoma With Evans Syndrome : A Case Report and Review of the Literature

Yasunobu Sekiguchi,¹⁾ Asami Shimada,^{1,3)} Hidenori Imai,¹⁾ Mutsumi Wakabayashi,¹⁾
Keiji Sugimoto,¹⁾ Noriko Nakamura,²⁾ Tomonori Sawada,²⁾ Norio Komatsu³⁾
and Masaaki Noguchi¹⁾

A 67-year-old man was diagnosed with CD56⁺ angioimmunoblastic T cell lymphoma (AITL), which was associated with autoimmune thrombocytopenic purpura (ATP) and autoimmune hemolytic anemia (AIHA) (Evans syndrome). The ATP was refractory to *Helicobacter pylori* eradication therapy and steroid. Complete remission (CR) of both AITL and AIHA was achieved with THP-COP chemotherapy (pirarubicin, cyclophosphamide, vincristine, and prednisolone), but ATP was not improved promptly. AITL associated with ATP has been reported in only 14 cases. The present case was not related to the serum interleukin-6 levels, suggesting the possibility of an association with other factors. This case is the first report of Evans syndrome associated with AITL. The AITL relapsed 2 months after CR. The AITL tumor were CD56-positive at initial diagnosis and CD56-negative at relapse, and showed complex additional chromosomal abnormalities, and the morphological characteristics of blast cells. CD56⁺ AITL are rare, although CD56 expression has not been investigated in many cases; our observations suggest that CD56 expression and its significance in AITL should be investigated in the future. There has been only one other case of CD56⁺ AITL, the patient died 4 months after the diagnosis. Our patient reported showed early relapse, central nervous system infiltration and was refractory to treatment, suggesting that CD56 positivity may be a poor prognostic marker in patients with AITL. [*J Clin Exp Hematop* 53(1): 37-47, 2013]

Keywords: angioimmunoblastic T-cell lymphoma, CD56, autoimmune thrombocytopenia, autoimmune hemolytic anemia, Evan's syndrome

INTRODUCTION

CD56 is known to be a marker of poor prognosis in patients with acute myeloblastic leukemia and anaplastic large cell lymphoma.^{1,2} However, CD56 expression has scarcely been measured in patients with angioimmunoblastic T-cell lymphoma (AITL), and its significance remains to be investigated.

Here, we report the case of a CD56⁺ AITL at the time of initial diagnosis encountered by us. CD56⁺ AITL is very rare, and only one other case has been reported so far in the literature;³ observations suggest that CD56 positivity of the tumor cells may be associated with a poor prognosis in AITL

patients.

In addition, AITL associated with autoimmune thrombocytopenia (ATP) is also rare, and only 14 cases, including our present case, have been reported so far.⁴⁻¹³ Furthermore, only in the present patient was the ATP a component of Evans syndrome. It has been speculated that tumor cells produce interleukin (IL)-6, which acts on the B cells, leading to hyper- γ -globulinemia, production of autoantibodies and development of ATP.¹³ In the present case, however, the platelet count did not increase even at the time of complete remission of the AITL, despite the serum IL-6 level being within the normal range. Other unusual characteristics of our patient were that at the time of the relapse of the AITL, the tumor cells became negative for CD56, and showed complex additional chromosomal abnormalities and the morphological characteristics of blast cells. The serum IL-6 level continued to remain within normal range, but the platelet count increased. Involvement of a cytokine(s) other than IL-6 was, therefore, speculated.

Received : November 28, 2012

Revised : January 10, 2013

Accepted : January 16, 2013

Divisions of ¹⁾Hematology and ²⁾Clinical Laboratory, Juntendo University Urayasu Hospital, Chiba, Japan

³⁾Division of Hematology, Juntendo University Juntendo Hospital, Tokyo, Japan

Corresponding author : Dr. Yasunobu Sekiguchi, Division of Hematology, Juntendo University Urayasu Hospital, 2-1-1 Tomioka, Urayasu-shi, Chiba 279-0021 Japan

E-mail : yasu_sek@juntendo-urayasu.jp

CASE REPORT

A 67-year-old man presented with multiple superficial lymphadenopathy, anorexia, weight loss and lower abdominal pain. His previous medical history included hypertension diagnosed at the age 62 years, and right pontine infarction and hyperlipidemia, both diagnosed when he was 65 years old. There was nothing noteworthy in his family history. As for the history of present illness, he was detected to have multiple superficial lymphadenopathy on both sides in the neck, clavicular fossae, axillae, inguinal and other regions, which had gradually enlarged since July 2010. Anorexia and weight loss developed in August 2010 and lower abdominal pain in September 2010, and the patient was referred to our hospital. In October 2010, a right axillary lymph node biopsy suggested the diagnosis of malignant lymphoma, and the patient was admitted to the Division of Hematology.

On admission, the patient was 169 cm tall, weighed 63 kg, had a body temperature of 36.0°C, blood pressure of 148/80

mmHg, regular pulse of 96/min, clear consciousness, no palpable liver or spleen, and no abnormal neurological findings. A few superficial lymph nodes measuring approximately 1-2 cm in diameter were palpable in the submandibular region and the neck on both sides, and a few measuring approximately 3-4 cm in diameter were palpable in the axillary and inguinal regions on both sides.

The laboratory findings at admission are shown in Table 1. The platelet count was as low as $1.0 \times 10^4/\mu\text{L}$; a bone marrow examination revealed a somewhat decreased nucleated cell count, a megakaryocyte count of $30/\mu\text{L}$, and no obvious atypical cells. There were no chromosomal abnormalities. Serum tests for antiplatelet and antinuclear antibodies were negative. The serum platelet-associated immunoglobulin G (PAIgG) level was markedly elevated ($1,600 \text{ ng}/10^7 \text{ cells}$), on the basis of which the diagnosis of ATP was made. In addition, the direct Coombs test was positive, associated with a marked decrease of the serum haptoglobin levels and autoimmune hemolytic anemia

Table 1. Laboratory findings at initial admission

Complete blood count		Coagulation	
White blood cell	3,800/ μL ↓	Prothrombin time	93%
Band	6.0%	APTT	33.0 sec
Segmented	73.0% ↑	Fibrinogen	270 mg/dL
Lymphocyte	10.0% ↓	FDP	6.0 $\mu\text{g}/\text{mL}$ ↑
Monocyte	10.0% ↑	Immunoelectrophoresis	
Eosinophil	1.0%	Anti-human whole serum	No M-protein
Red blood cell	$428 \times 10^4/\mu\text{L}$	Immuno-serological findings	
Hemoglobin	12.5 g/dL ↓	IgG	2,519 mg/dL ↑
Hematocrit	35.8% ↓	IgA	125 mg/dL
MCV	83.6% ↓	IgM	136 mg/dL
MCH	29.1% ↓	Antinuclear antibodies	< ×40
Platelet	$1.0 \times 10^4/\mu\text{L}$ ↓	Platelet-associated IgG	1,600 ng/ 10^7 cell ↑ (9.0-25.0)
Reticulocyte	1.7%	Antiplatelet antibodies	Negative
Urinalysis	No abnormalities	Anti- <i>Helicobacter pylori</i> IgG	11 U/mL ↑
Biochemistry		Serum IL-2R	5,780 U/mL ↑ (145-519)
Total protein	7.7 g/dL	Serum IL-6	3.3 pg/mL (≤ 4.0)
Albumin	3.2 g/dL	Direct Coombs test	Positive ↑
AST	36 IU/L ↑	Indirect Coombs test	Negative
ALT	24 IU/L	Haptoglobin	$\leq 10 \text{ mg}/\text{dL}$ ↓ (25-176)
LDH	459 IU/L ↑	HTLV-1 antibodies	Negative
ALP	322 IU/L	HIV antibodies	Negative
γ -GTP	28 IU/L	Cold agglutinin	×32
Total bilirubin	0.9 mg/dL	Cryoglobulin	Negative
Direct bilirubin	0.4 mg/dL ↑	Chromosome G-banding in the lymph node	
BUN	8 mg/dL	At initial diagnosis	Poor growth
Creatinine	0.74 mg/dL	At relapse	
Uric acid	5.4 mg/dL	46, XY, add (10) (q22), add (19) (p13)	10 out of 20 cells
CRP	2.1 mg/dL ↑	48, XY, add (2) (q31), + del (5) (q?), + 19	8 out of 20 cells

Abnormal values are shown by arrows: ↑, higher than the normal range; ↓, lower than the normal range; the normal range is shown in parenthesis.

MCV, mean corpuscular volume; MCH, mean corpuscular hemoglobin; AST, aspartate aminotransferase; ALT, alanine aminotransferase; LDH, lactate dehydrogenase; ALP, alkaline phosphatase; γ -GTP, γ -guanosine triphosphate; BUN, blood urea nitrogen; CRP, C-reactive protein; APTT, activated partial thromboplastin; FDP, fibrin fibrinogen degradation; IL-2 R, interleukin-2 receptor; HTLV-1, human T-cell leukemia virus-1; HIV, human immunodeficiency virus

(AIHA); based on these findings, the diagnosis of Evans syndrome was made.

¹⁸F-fluorodeoxyglucose-positron emission tomography/computed tomography (FDG-PET-CT) showed abnormal FDG accumulation in the superficial and deep lymph nodes extending from the neck to the popliteal fossa, in the pharynx, and in the spleen, and also pericardial effusion, pleural effusion and ascites. The maximum standardized uptake value (SUVmax) was 9.0 in the right axillary lymph node, which was therefore selected as the site of biopsy (Fig. 1A).

Histopathological examination by light microscopy, under low magnification, of the biopsy specimen after H&E staining revealed loss of the lymph node architecture, a small number of obvious clear cells, and dendritic growth of blood vessels (Fig. 2A). Examination under higher magnification revealed proliferation mainly of small- to medium-sized, somewhat atypical cells, with a small number of large cells (Fig. 2B). Immunohistochemical staining showed that the tumor cells were positive for CD3 (Fig. 2C), weakly positive for CD4 (Fig. 2D), positive for CD5 (Fig. 2E), positive for CD8 at a low frequency (Fig. 2F), negative for CD10 (Fig. 2G), and large cells with CD20 expression are scattered (Fig. 2H).

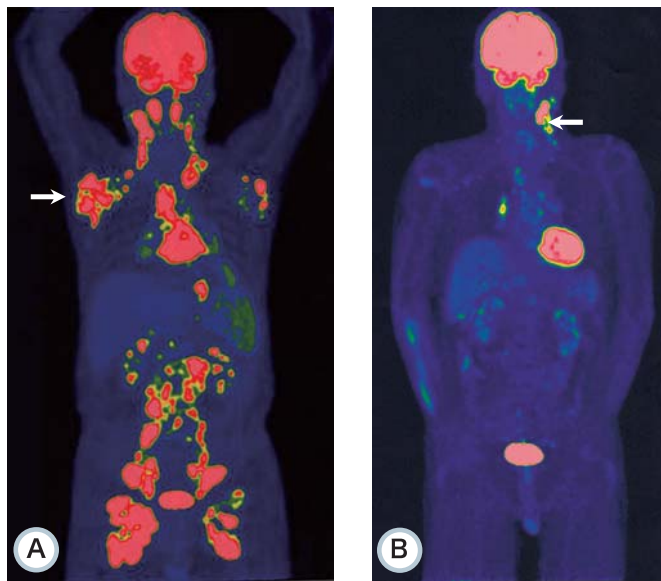


Fig. 1. Imaging findings. (**1A**) At the time of initial diagnosis, ¹⁸F-fluorodeoxyglucose-positron emission tomography/computed tomography (FDG-PET-CT) showed FDG accumulation in lymph nodes from the neck to the popliteal fossa, in the pharynx, and in the spleen. Evidence of pericardial effusion, pleural effusion and ascites was also observed. SUVmax in the right axillary lymph node was 9.0 (indicated by the *white arrow*), which was, therefore, selected as the site of biopsy. (**1B**) At the time of relapse, PET-CT showed FDG accumulation in the left nasopharynx, and in the left neck and mediastinal lymph nodes. SUVmax in the left neck lymph node was 12.3 (indicated by the *white arrow*); this node was therefore selected as the biopsy site.

CD21⁺ follicular dendritic cells proliferated in a reticular pattern (Fig. 2I). CD30 positivity was observed at a low frequency in the small to large cells (Fig. 2J) and Epstein-Barr virus-encoded RNA (EBER) positivity was noted mainly in the large cells (Fig. 2K). In particular, CD56⁺ cells were observed at a high frequency (Fig. 2L). Weak positivity for latent membrane protein-1 was noted, mainly in the large cells (Fig. 2M), and strong Ki-67 positivity was observed at a somewhat high frequency (30%) (Fig. 2N). Weak positivity for program death-1 and CXCL13 chemokine ligand 13 was noted (Fig. 2O & 2P). Based on the above, the patient was diagnosed as having CD56⁺ AITL.

Flow cytometry of the biopsy specimen from the right axillary lymph node confirmed CD56 positivity (Fig. 3A). In addition, it showed CD2 positivity, CD3 negativity, CD8 negativity, CD5 positivity, CD7 negativity, CD30 negativity and weak CD4 positivity. CD3 positivity on immunohistochemistry, suggested that the CD3 was present within the cytoplasm. CD5 positivity suggested T-cell lymphoma, rather than natural killer (NK) cell lymphoma.

Southern-blot analysis of the lymph node biopsy specimen revealed rearrangement of the T cell receptor gene, *TCR CC1* (Fig. 4B), but not of an immunoglobulin heavy chain joining region (*IgHJH*). G-banded chromosomes could not be identified in the lymph node due to poor growth. There was no infiltration of tumor cells in the bone marrow or central nervous system. Based on the FDG-PET-CT findings (Fig. 1A), the disease was diagnosed to be in clinical stage IVB. The patient fulfilled three of the criteria of the International Prognostic Index, i.e., extranodal lesions, old age and high serum lactate dehydrogenase value, and was classified as a high-intermediate risk patient.

In the clinical course after admission (Fig. 5A), *Helicobacter pylori* eradication therapy was given for ATP due to the positive urea breath test result, and at the same time, the patient was started on treatment with oral prednisolone at 1 mg/kg/day (60 mg/day). Thereafter, the prednisolone was gradually tapered in dose and eventually discontinued. The urea breath test became negative, indicating successful eradication of the *Helicobacter pylori* infection, however, the platelet count did not increase. One course of THP-COP therapy (pirarubicin, cyclophosphamide, vincristine, and prednisolone) was administered as treatment for the AITL in October 2010. The lymph nodes became markedly smaller in response, indicating that the therapy was effective, and the patient was discharged. However, the platelet count still did not increase.

In regard to the clinical course after discharge (Fig. 5A), the patient received 6 courses of THP-COP therapy until January 2011, and the therapy was completed. In March 2011, systemic CT and Ga scintigraphy confirmed complete remission. Serum soluble IL-2 receptor level decreased from 5,780 to 726 U/mL. The direct Coombs test became negative

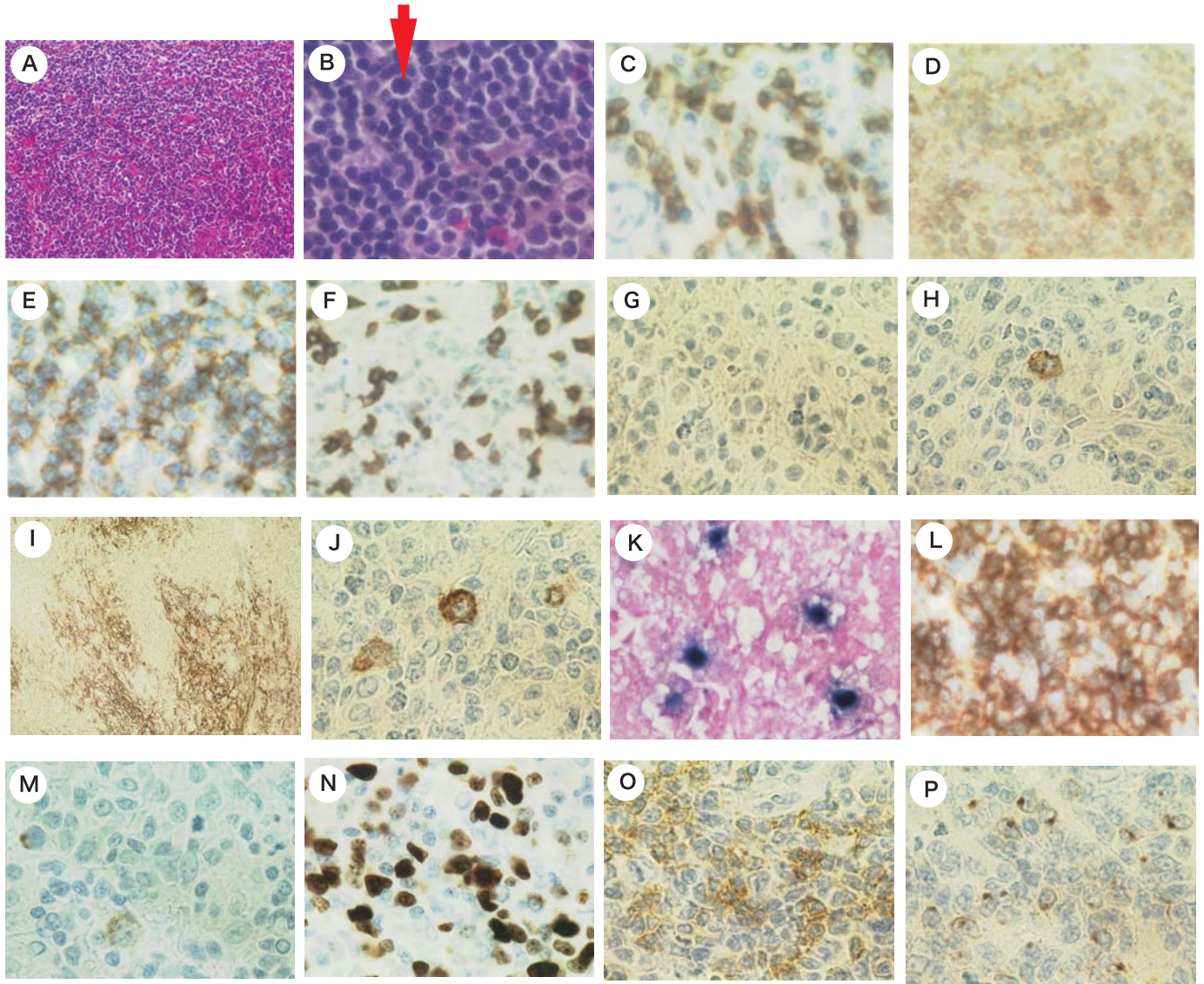


Fig. 2. Pathological findings of axillary lymph node at the time of the initial diagnosis. (2A) H&E staining of the right axillary lymph node ($\times 100$) showed no obvious clear cells, but showed dendritic growth of blood vessels. (2B) H&E staining ($\times 600$) showed proliferation, mainly of small- to medium-sized, somewhat atypical cells, with a small number of large cells (*arrow*). (2C) The tumor cells were CD3-positive. (2D) The tumor cells were weakly positive for CD4. (2E) The tumor cells were CD5-positive. (2F) The tumor cells were CD8-positive. (2G) The tumor cells were CD10-negative, but angioimmunoblastic T cell lymphoma could not be excluded. (2H) Small- to medium-sized, somewhat atypical cells were CD20-negative. Large cells with CD20 expression are scattered. (2I) CD21-positive follicular dendritic cell proliferating in a reticular pattern ($\times 40$). (2J) CD30 positivity in some small to large cells. (2K) Epstein-Barr virus-encoded RNA positivity in some large cells. (2L) The tumor cells were CD56-positive. (2M) Weak positivity for latent membrane protein-1 was found in some large cells. (2N) Positivity for Ki-67 was observed at a high frequency (30%) mainly in some tumor cells and in large cells. (2O) The tumor cells were weakly positive for program death-1. (2P) The tumor cells were weakly positive for CXC chemokine ligand 13.

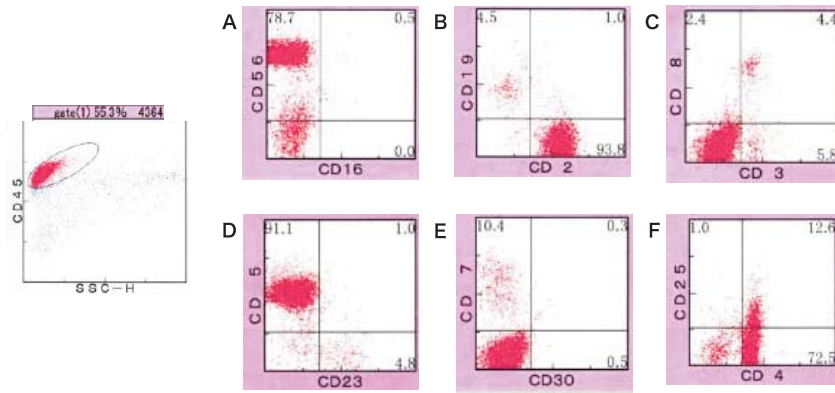


Fig. 3. Flow cytometry of the right axillary lymph node at the time of the initial diagnosis. (3A) CD56-positive, CD16-negative. (3B) CD2 positive, CD19 negative. (3C) CD3-negative, CD8-negative. (3D) CD5-positive, CD23-negative. (3E) CD7-negative, CD30-negative. (3F) CD4-positive, CD25-negative.

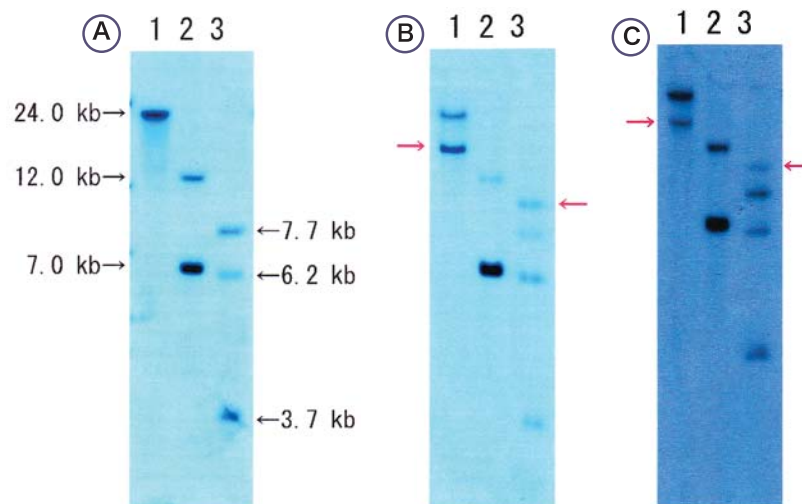


Fig. 4. Southern blot analysis of lymph node biopsy specimens (*T-cell receptor C β 1*). (4A) Healthy individual control. (4B) The right axillary lymph node at the time of the initial diagnosis. (4C) The left neck lymph node at the time of relapse. The restriction enzymes used were: lane 1, BamHI; lane 2, EcoRV; and lane 3, HindIII. Red arrows indicate gene rearrangement bands in the patient's specimen. It was considered that the patient might have a T-cell lymphoma, but not natural killer-cell lymphoma.

and the serum haptoglobin returned to normal range (78 mg/dL). The serum level of PAIgG also decreased from 1,600 to 21 ng/ 10^7 cells (within the normal range); however, the platelet count was 16,000/ μ L, remaining low. Bone marrow examination was performed in February and June 2011, and the nucleated cell and megakaryocyte counts were within the respective normal ranges, with no obvious atypical cells.

In May 2011, new lymphadenopathy developed in the left neck (Fig. 5B), and FDG-PET-CT was performed. FDG accumulation was observed in the nasopharynx, in the lymph nodes from the left side of the neck (SUVmax 12.3) to the mediastinum, as well as in the mesenteric and left external

iliac lymph nodes, indicating early relapse (Fig. 1B).

In June 2011, biopsy of the left neck lymph node was performed. The biopsy confirmed relapse of the AITL, however, immunostaining (Fig. 6G) and flow cytometry (Fig. 7A) of the lymph node revealed that the tumor cells had become negative for CD56. The tests for other markers than CD56 showed almost similar results as before (Fig. 7). The proportion of highly atypical, medium-sized cells with blast characteristics and clear nucleoli was higher (Fig. 6A). CD3 positivity (Fig. 6B), CD5 positivity (Fig. 6C), CD20 negativity (Fig. 6D) and a reduced rate of CD21 positivity (Fig. 6E), which indicate a reduction in follicular dendritic cell prolifer-

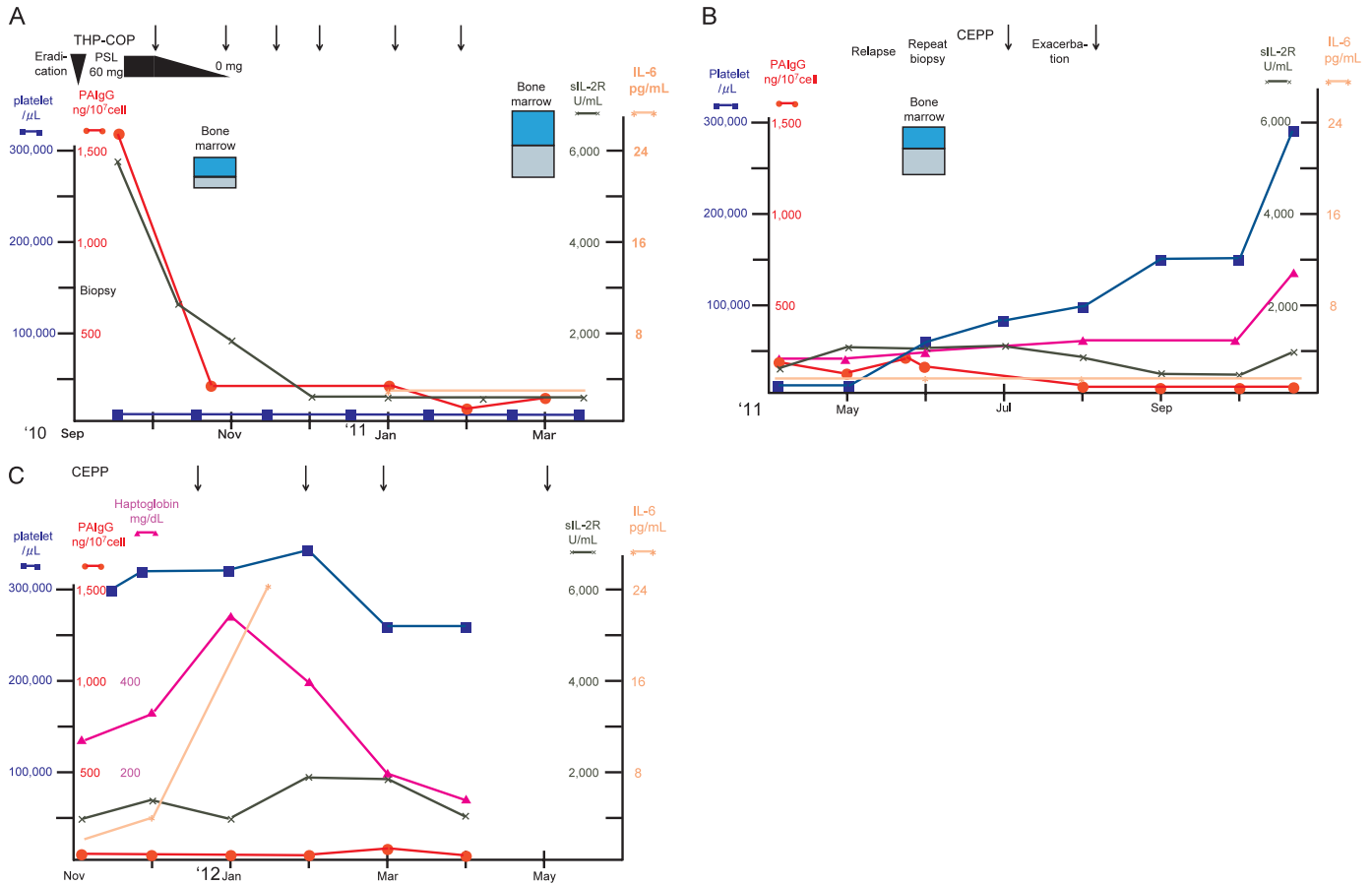


Fig. 5. Clinical course. (5A) Clinical course from the initial diagnosis to complete remission is shown. Complete remission of angioimmunoblastic T cell lymphoma (AITL) was achieved with THP-COP therapy (pirarubicin, cyclophosphamide, vincristine, and prednisolone). The serum platelet-associated immunoglobulin G (PAIgG) decreased from 1,600 to 21 ng/ 10^7 cells, but the platelet count remained at 12,000/ μ L, showing no increase. The positive direct Coombs test, indicative of autoimmune hemolytic anemia, became negative, and the serum haptoglobin also increased and improved from 10 or lower to 78 mg/dL. (5B) Clinical course after complete remission through relapse. At the time of relapse, the AITL cells were transformed and the platelet count increased from 17,000 to 67,000/ μ L. Subsequently, the platelet count increased further to 297,000/ μ L, unrelated to the disease state. The serum PAIgG decreased to 9 ng/ 10^7 cells and the serum haptoglobin increased to 275 mg/dL, unrelated to the state of AITL. (5C) Clinical course from exacerbation to the present time: The platelet count remained in the range of 219,000 to 394,000/ μ L, and the serum PAIgG remained in the range of 8 to 18 ng/ 10^7 cells, unrelated to the state of AITL. The serum interleukin-6 increased approximately 6 months after the relapse (after the increase in the platelet count).

ation, and a reduced rate of EBER positivity (Fig. 6F), which indicates a reduction in the number of Epstein-Barr virus-infected B-cells, suggested the proliferation of transformed AITL tumor cells. *TCR C β 1* rearrangement bands almost identical to those at the time of initial diagnosis were observed (Fig. 4B & 4C), suggesting the involvement of the same clone in the relapse. Rearrangement of *IgHJH* was absent. In respect of the G-banding patterns of chromosomes in the lymph node at the time of relapse, 46, XY, add(10)(q22), add(19)(p13) was found in 10 out of 20 cells and 48, XY, add(2)(q31), +del(5)(q?), +19 in 8 cells. At the time of the AITL relapse, the cells showed complex additional chromosomal abnormalities, became negative for CD56 (Fig. 6G & 7A), exhibited the morphological characteristics of blast

cells (Fig. 6A), and an increase of the Ki-67 positivity rate (60%) (Fig. 6H). FDG-PET-CT showed that the SUV max increased from 9.0 in the right axillary lymph node at the time of initial diagnosis to 12.3 in the left neck lymph node at the time of relapse (Fig. 1B). Based on the above findings, the patient was diagnosed as relapse of AITL with transformed tumor cells.

At the time of diagnosis of the relapse, the platelet count increased from 17,000 to 67,000/ μ L (Fig. 5B). Bone marrow examination was performed again, which revealed a decrease of the nucleated cell count to 66,000/ μ L, megakaryocyte count within the normal range (75/ μ L), and no atypical cells. In June 2011, the patient was readmitted to our division. The first course of CEPP therapy (cyclophosphamide, etoposide,

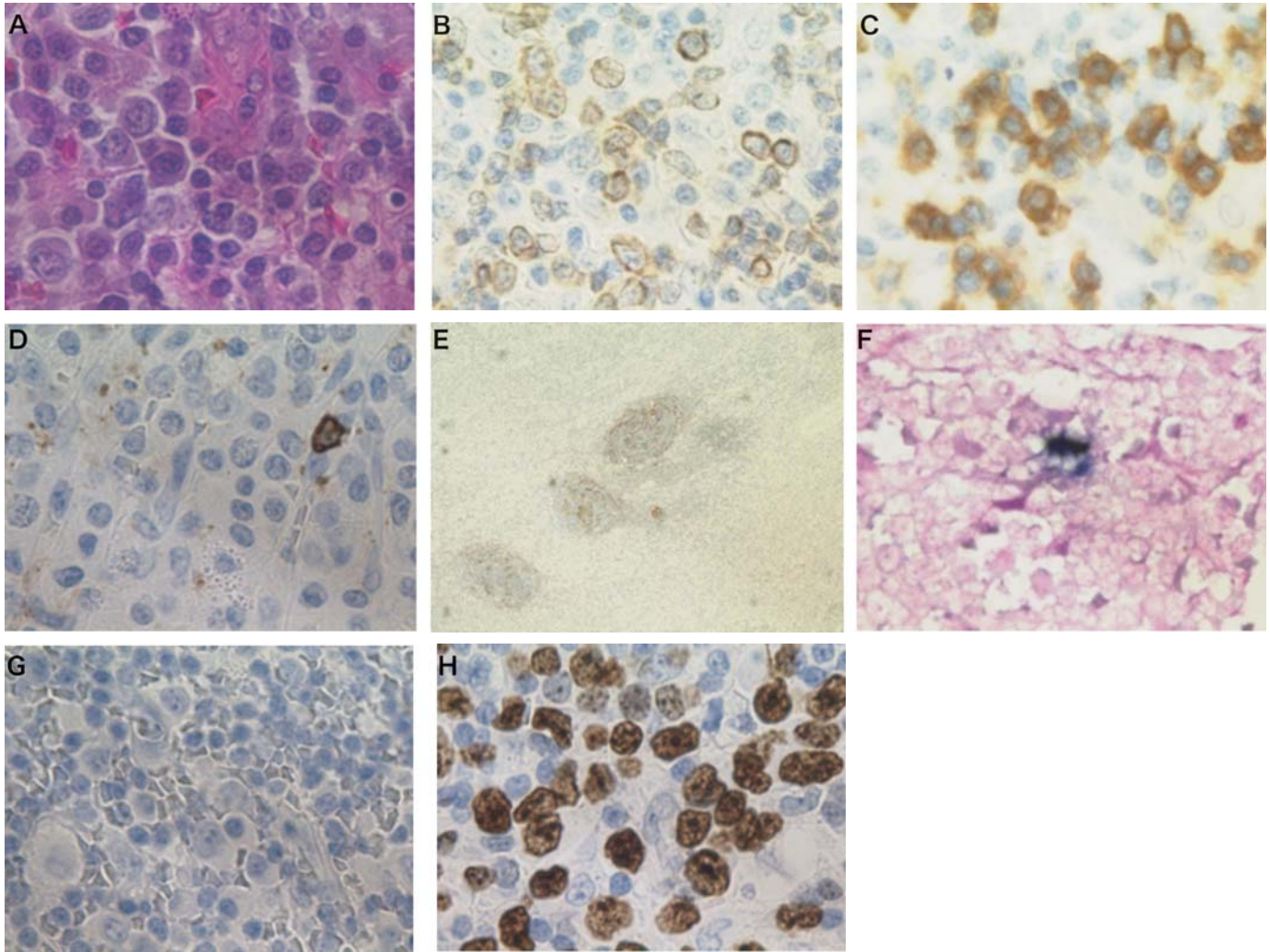


Fig. 6. Pathological findings of the left neck lymph node at the time of relapse. (6A) H&E staining ($\times 600$) showed that tumor cells had more characteristics of blast cells as compared with that at the time of initial diagnosis. (6B) Tumor cells were CD3-positive. (6C) The tumor cells were CD5-positive. (6D) The tumor cells were CD20-negative. (6E) CD21⁺ follicular dendritic cell proliferating in a reticular pattern ($\times 40$). (6F) Epstein-Barr virus-encoded RNA positivity in a small number of large cells. (6G) The tumor cells were CD56-negative. (6H) Ki-67 positivity was observed mainly in some tumor cells and in large cells, and the index was higher (60%) as compared with that at the time of the initial diagnosis.

procarbazine, and prednisone) was started in July, and the lymph nodes became markedly smaller, with almost complete remission achieved. The serum PAIgG decreased, and after a while, the platelet count increased further to 82,000/ μL . Therefore, the patient was discharged in July. The platelet count increased further to 297,000/ μL . In December 2011, the AITL was exacerbated and CEPP therapy was administered again (Fig. 5C). Approximately 6 months after the AITL relapse (after the platelet count increased), the serum IL-6 increased. However, in June 2012, infiltration of AITL tumor cells was observed in the central nervous system, and the patient became refractory to treatment.

DISCUSSION

CD56 positivity of the blood cells is often noted in hematopoietic diseases. However, to the best of our knowledge, CD56⁺ AITL is very rare and only one other case has been reported previously in the literature.³ Comparison between the previous and present case is shown in Table 2. In both cases, the AITL tumor cells were CD2-positive and CD3-negative and some large reactive B-cells were EBER-positive. However, the cells were CD4-negative and partially CD8-positive in the previous case, while they were CD4-positive and CD8-negative in the present case. Furthermore, since the cells were CD5-positive, NK cell lymphoma was

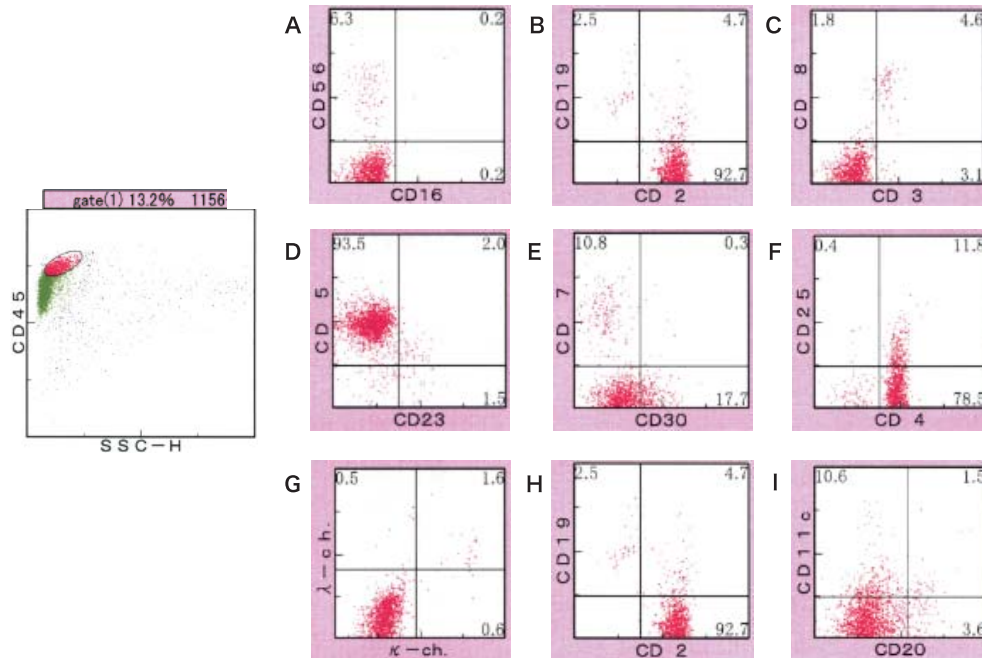


Fig. 7. Flow cytometry of the biopsy specimen from the left neck lymph node at the time of relapse. (7A) CD56-negative, CD16-negative. (7B) CD2-positive, CD19-negative. (7C) CD3-negative, CD8-negative. (7D) CD5-positive, CD23-negative. (7E) CD7-negative, CD30-negative. (7F) CD4-positive, CD25-negative. (7G) κ -negative, λ -negative. (7H) CD2-positive, CD19-negative. (7I) CD20-negative, CD11c-negative.

Table 2. Comparison between the previous case of CD56⁺ angioimmunoblastic T cell lymphoma and the present case

Case	Age/sex	Evans syndrome	CD2	CD3	cytoplasmic CD3	CD4	CD5	CD7	CD8	CD16	CD56	EBER	LMP-1	Reference
The previous case	83/M	-	+	-	NA	-	NA	NA	+/-	NA	+	+	NA	3
At initial diagnosis in this case	65/M	+	+	-	+	+	+	-	-	-	+	+	-	This case
At relapse in this case	66/M	+	+	-	+	+	+	-	-	-	-	+/-	-	This case

EBER, Epstein-Barr virus-encoded RNA ; LMP-1, latent membrane protein-1 ; M, man ; NA, not available

unlikely in the present case, whereas in the previous case, NK cell lymphoma could not be excluded as the tumor cell CD5 expression was not investigated, intracellular CD3 and Southern blot analysis were not performed, and the patient was Japanese. In the present case, but not in the previous case, CD56⁺ AITL was associated with Evans syndrome. The present patient became refractory to treatment approximately 4 months after completion of treatment, and the previous case died approximately 4 months after the diagnosis, suggesting that CD56 positivity of the tumor cells may be a marker of poor prognosis in AITL patients.

In general, CD56 expression is known to be a poor prognostic factor in cases of acute myeloid leukemia and anaplastic large cell lymphoma.^{1,2} However, CD56 has scarcely been examined in patients with AITL until date. We would like to perform CD56 immunostaining in previously reported AITL

cases to investigate the significance of tumor cell expression of CD56 in this disease. At the time of relapse in our present patient, the tumor cells showed some characteristics of blast cells and an elevated Ki-67 index (60%). Furthermore, the cells became negative for CD56 and complex additional chromosomal abnormalities appeared. The results of southern blot analysis for *TCR C β 1* suggested the involvement of the same clone as at the initial diagnosis, and the patient was diagnosed as having AITL relapse with transformed AITL cells.

The present patient had both AIHA and ATP and was diagnosed as having Evans syndrome. It has been reported that in cases of AITL, the Coombs test is positive in as high as 45.2% of the cases, but that actually AIHA is not commonly found.¹⁴ Furthermore, AITL associated with ATP is rare. A search of the literature to the best of our ability revealed

reports of only 14 cases in the literature, including the present case, of AITL associated with ATP (Table 3). All the 14 cases were reported from Japan, and therefore, we considered that this combination may be more common among Japanese. The characteristics of these patients are shown in Table 4.

The reported patients ranged in age from 56 to 88 years, with an average age of 69.2 years. Thus, AITL associated with ATP was found more often in the elderly. The presence of the two diseases concomitantly also tended to be more common in males, with a male : female ratio of 10 : 4. The platelet count was as low as 3,000 to 96,000/ μ L, with an average of 36,000/ μ L. The serum PAIgG level was as high as 128 to 33,000 ng/ 10^7 cells, with an average of 4,145.1 ng/ 10^7 cells. The IgG level was 2,519 to 7,808 mg/dL, with

an average of 4,051 mg/dL, indicative of hyper- γ -globulinemia. The direct Coombs test was positive in 10 out of the 14 cases, but none of the cases actually showed hemolytic anemia. Of the 11 cases, 5 were positive for antinuclear antibodies, although no other evidence of collagen disease was found. As for the outcomes, the AITL improved in all of the 14 cases, and of these, complete remission was achieved in 5 cases. The ATP improved in 13 cases, but persisted in 1 case (Case 12 in Table 3). Four of the 14 patients died, and of these, 2 died of AITL and 2 died of causes unrelated to AITL or ATP. The ATP improved with the improvement of AITL in 11 of the 14 reported cases with both AITL and ATP. In Case 9, the platelet count increased in response to splenic irradiation, and was, therefore, considered to have been

Table 3. Reports of patients with angioimmunoblastic T cell lymphoma (AITL) associated with autoimmune thrombocytopenic purpura (ATP)

Case	Age/sex	Platelet count ($\times 10^4/\mu$ L)	PAIgG (ng/ 10^7 cells)	Treatment	Effect (AITL)	Effect (ATP)	Outcome	Reference
1	66/M	1.6	1,600	Pylori eradication, PSL, chemotherapy	CR→Relapse	No improvement → Improvement at relapse	Survival	This case
2	59/M	1.1	NA	PSL 100 mg/day	Improvement	Improvement	Death from interstitial pneumonia and DIC	4
3	75/F	8.2	605	Chemotherapy	CR	Improvement	Still alive for 18 mon	5
4	71/M	3.3	841.9	Chemotherapy	PR	Improvement	NA	6
5	61/M	5	320	Chemotherapy	CR	Improvement	NA	6
6	73/F	9.6	451.7	Chemotherapy	PR	Improvement	NA	6
7	71/F	2.2	+	Steroid pulse, chemotherapy	Improvement	Improvement	Death from cerebral infarction 8 mon later	7
8	88/F	5	296.5	PSL, chemotherapy	Improvement → Exacerbation	Improvement → Exacerbation	Death from exacerbation of AITL 4 mon later	8
9	84/M	2.6	2,568.9	PSL, chemotherapy Splenic radiation	Improvement → Exacerbation	Improvement by radiation	Death from exacerbation of AITL 3 mon later	9
10	58/M	4.8	1,939.5	PSL, chemotherapy	CR	Improvement	Still alive for 20 mon	10
11	56/M	3.3	128	Chemotherapy	CR → Relapse → CR	Improvement → Exacerbation → Improvement	Still alive for 19 mon	11
12	73/M	2.5	6,880	Under chemotherapy	Improvement	No improvement	Still alive for 6 mon	12
13	68/M	0.3	33,000	Chemotherapy	Improvement	Improvement	Still alive for 3 yr	13
14	66/M	0.4	1,110	Chemotherapy	Improvement	Improvement	Still alive for 2 yr 7 mon	13

PAIgG, serum platelet-associated immunoglobulin G ; M, man ; F, female ; PSL, prednisolone ; CR, complete remission ; PR, partial remission ; DIC, disseminated intravascular coagulation ; NA, not available

Table 4. Characteristics of the reported cases of angioimmunoblastic T cell lymphoma (AITL) associated with autoimmune thrombocytopenic purpura (ATP)

Mean age (years)	69.2 (56-88) (n = 14)
Male/female	10 : 4 (n = 14)
Platelet count ($\times 10^4/\mu\text{L}$)	3.6 (0.3-9.6) (n = 14)
PAIgG (ng/ 10^7 cells)	4,145.1 (128-33,000) (n = 12)
Treatment	Eradication 1/Chemotherapy 13/Steroid 6/Splenic radiation 1
Therapeutic effect on AITL	CR 5/Improvement (including PR) 9 (n = 14)
Therapeutic effect on ATP	Improvement 13/No improvement 1 (n = 14)
Outcome	Survival 7/Death from AITL 2/Death from causes other than AITL 2 (n = 11)

PAIgG, serum platelet-associated immunoglobulin G ; CR, complete remission ; PR, partial remission

caused by hypersplenism. Case 12 was under chemotherapy and could not be assessed. In the present case, the ATP did not improve with chemotherapy at first, but improved at the time of the tumor relapse. This was the only case where the ATP improved at the time of relapse.

Various immunological abnormalities, including circulating immune complex positivity, Coombs positivity, production of autoantibodies such as antinuclear antibodies, hemolytic anemia, cold agglutinin positivity and polyclonal hyper- γ -globulinemia, have been reported in patients with AITL.¹⁵ It is speculated that the tumor cells produce IL-6, which acts on the B cells, resulting in hyper- γ -globulinemia and production of autoantibodies,^{8,9,13} and consequently, in the development of ATP. Production of cytokines, such as tumor necrosis factor- α/β , IL-1, IL-4, IL-6 and interferon- γ , has also been reported.^{16,17} However, the mechanisms of autoantibody production have not yet been elucidated in detail. The platelet count increased with the improvement of AITL in many previously reported cases (Table 3). It has been speculated that cytokines from the tumor cells can block autoantibody production. However, in the present case, the platelet count did not increase at the time of complete remission, even though the serum level IL-6 was within the normal range and the serum PAIgG level was reduced (Fig. 2A). Bone marrow examination showed normal counts of megakaryocytes, no suppression of platelet production, and no evidence of AITL infiltration. At the time of relapse, the serum PAIgG decreased to within normal range and the platelet count increased to 67,000/ μL (Fig. 2B), suggesting the possibility of transformation of AITL tumor cells, so that cytokines promoting PAIgG production other than IL-6 ceased to be produced after the relapse. Therefore, we consider it necessary in the future to measure various cytokines in cases of AITL. The present patient had no splenomegaly and was also unlikely to have had hypersplenism.

At the time of relapse, lymph node biopsy showed that the tumor cells showed blast-like morphology, CD56 negativity and complex additional chromosomal abnormalities, suggesting morphological transformation of the tumor cells. Therefore, it is possible that the stimulation of cytokines promoting PAIgG production from the tumor cells may have

been reduced, contributing to the increase in the platelet count. In the reports of cases of AITL associated with ATP (Table 3), CD56 expression in the tumor cells was not measured in any of the cases, except the present case. In the future, it is considered necessary to accumulate cases of AITL with ATP and to examine CD56 expression in the tumor cells and various cytokines and serum PAIgG levels over time, as well as to investigate the prognosis in relation to these parameters.

CONSENT

Written informed consent was obtained from the patient for publication of this case report and any accompanying images.

CONFLICT OF INTEREST

The authors declare that they have no conflict interest.

AUTHORS' CONTRIBUTIONS

YS, AS, HI, MW and KS treated the patient and collected data. NN and TS analyzed the data. YS made analysis and wrote the manuscript under the guidance of NK and MN. All authors read and approved the final manuscript.

REFERENCES

- 1 Baer MR, Stewart CC, Lawrence D, Arthur DC, Byrd JC, *et al.*: Expression of the neural cell adhesion molecule CD56 is associated with short remission duration and survival in acute myeloid leukemia with t(8;21)(q22;q22). *Blood* 90:1643-1648, 1997
- 2 Suzuki R, Kagami Y, Takeuchi K, Kami M, Okamoto M, *et al.*: Prognostic significance of CD56 expression for ALK-positive and ALK-negative anaplastic large-cell lymphoma of T/ null cell phenotype. *Blood* 96:2993-3000, 2000
- 3 Hosoki K, Okada S, Ichinohasama R, Yamaguchi M, Uchiyama B, *et al.*: Angioimmunoblastic T-cell lymphoma developed with lymphocytic pleural effusion. *Intern Med* 46:739-742, 2007
- 4 Okada T, Hato T, Kawamura S, Fujita S, Kobayashi Y, *et al.*:

- Immunoblastic lymphadenopathy (IBL)-like T cell lymphoma associated with hypoplastic anemia, thrombocytopenia and abnormality of coagulation. *Rinsho Ketsueki* 28:756-761, 1987 (*Abstract in English*)
- 5 Anzai T, Hirose W, Nakane H, Kawagoe M, Kawai T, *et al.*: Myelodysplastic syndrome associated with immunoblastic lymphadenopathy-like T-cell lymphoma: simultaneous clinical improvement with chemotherapy. *Jpn J Clin Oncol* 24:106-110, 1994
 - 6 Higuchi T, Mori H, Niikura H, Omine M: Hypocomplementemia and hematological abnormalities in immunoblastic lymphadenopathy and immunoblastic lymphadenopathy-like T cell lymphoma. *Acta Haematol* 96:68-72, 1996
 - 7 Shirakawa C, Enomoto H, Tanaka H, Yonekawa S, Irimajiri K, *et al.*: Immunoblastic lymphadenopathy-like T cell lymphoma associated with erythroid hypoplasia and thrombocytopenia. *Rinsho Ketsueki* 37:701-706, 1996 (*Abstract in English*)
 - 8 Takayanagi N, Sampi K: Immunoblastic lymphadenopathy-like T cell lymphoma with high levels of serum interleukin-6, cold agglutinin disease, and immune thrombocytopenia. *Rinsho Ketsueki* 39:1109-1114, 1998 (*Abstract in English*)
 - 9 Suehiro S, Shiratsuchi M, Suehiro Y, Oshima K, Shiokawa S, *et al.*: Angioimmunoblastic T cell lymphoma (AITL) with autoimmune thrombocytopenia. *Rinsho Ketsueki* 43:841-845, 2002 (*Abstract in English*)
 - 10 Muta T, Yamano Y: Angioimmunoblastic T-cell lymphoma associated with an antibody to human immunodeficiency virus protein. *Int J Hematol* 78:160-162, 2003
 - 11 Matsui K, Adachi M, Tominaga T, Shinohara K, Kamei T: Angioimmunoblastic T cell lymphoma associated with reversible myelofibrosis. *Intern Med* 47:1921-1924, 2008
 - 12 Kondo A, Hyodo H, Tanozaki S, Tamura H, Nakamura K, *et al.*: Angioimmunoblastic T cell lymphoma with severe hyper-IgE-globulinemia and immune thrombocytopenia. *J Jap Elderly Leukemia and Lymphoma Study Group* 17:13-16, 2008 (*in Japanese*)
 - 13 Oka K, Nagayama R, Yatabe Y, Iijima S, Mori N: Angioimmunoblastic T-cell lymphoma with autoimmune thrombocytopenia: a report of two cases. *Pathol Res Pract* 206:270-275, 2010
 - 14 Tobinai K, Minato K, Ohtsu T, Mukai K, Kagami Y, *et al.*: Clinicopathologic, immunophenotypic, and immunogenotypic analyses of immunoblastic lymphadenopathy-like T-cell lymphoma. *Blood* 72:1000-1006, 1988
 - 15 Dogan A, Gaulard P, Jaffe ES, Ralfkiaer E, Muller-Hermelin HK: Angioimmunoblastic T-cell lymphoma. In: Swerdlow SH, Campo E, Harris NL, Jaffe ES, Pileri SA, *et al.* (eds): *World Health Organization Classification of Tumours, WHO Classification of Tumours of Haematopoietic and Lymphoid Tissues*. 4th ed, Lyon, International Agency for Research on Cancer (IARC), pp. 309-311, 2008
 - 16 Ohnishi K, Ichikawa A, Kagami Y, Nagasaka T, Niwa T, *et al.*: Interleukin 4 and γ -interferon may play a role in the histopathogenesis of peripheral T-cell lymphoma. *Cancer Res* 50:8028-8033, 1990
 - 17 Ohnishi K, Kato H: IBL-like T cell lymphoma. The relationship between cytokine production and histopathogenesis. *Rinsho Ketsueki* 37:412-416, 1996 (*Abstract in English*)