

Case Study

A Case of IgG4-Related Dacryoadenitis that Regressed Without Systemic Steroid Administration

Koh-ichi Ohshima,¹⁾ Yasuharu Sato,²⁾ and Tadashi Yoshino²⁾

There are no reports on the effect of anti-allergic agents against IgG4-related disease. We herein report a case of IgG4-related dacryoadenitis that is believed to have regressed due to the administration of anti-allergic agents. A 57-year-old woman consulted us because of bilateral temporal upper eyelid swelling and induration. She had also been suffering from allergic rhinitis and allergic conjunctivitis for 20 years. We performed an incisional biopsy of the lesion. With respect to the pathology, extranodal marginal zone lymphoma of mucosa-associated lymphoid tissue type was strongly suspected. On obtaining consent from the patient, follow-up alone was to be continued without radiation therapy. In addition to the observation of lacrimal gland lesions, the administration of epinastine hydrochloride at a dosage of 20 mg/day and 0.01% betamethasone eye drops twice a day to both eyes was commenced in order to treat both allergic rhinitis and allergic conjunctivitis. The lacrimal gland lesion decreased in size over time, becoming predominantly normal 7 years after the commencement of agent administration. We therefore re-examined the blood and pathology specimens. As a result, the serum IgG4 level was found to have increased to 540 mg/dl, while IgG4/IgG was 36.2%. The pathological diagnosis was revised to IgG4-related dacryoadenitis. The hypotheses of spontaneous remission and/or the effect of epinastine hydrochloride administration can be proposed regarding the mechanism by which the lacrimal gland lesion decreased in size. [*J Clin Exp Hematop* 53(1): 53-56, 2013]

Keywords: epinastine, IgG4-related dacryoadenitis, IgG4-related disease, anti-allergic agent, treatment

INTRODUCTION

Systemic steroid administration is the treatment of choice against IgG4-related diseases. Rituximab may be used to treat IgG4-related diseases, but its effectiveness remains controversial.¹⁻³ However, there are no reports on the effect of anti-allergic agents. We herein report a case of IgG4-related dacryoadenitis that is believed to have regressed due to the administration of anti-allergic agents.

CASE REPORT

A 57-year-old woman consulted at our hospital because of a one-year history of bilateral temporal upper eyelid swelling and induration. She had also been suffering from allergic

rhinitis and allergic conjunctivitis for 20 years.

At the initial visit, her temporal upper eyelids were swollen and subcutaneous indurations were palpated on both sides (Fig. 1). The palpebral conjunctiva was mildly congested and the patient complained of itchiness in her eyes. Her visual acuity was good, at 1.0 (1.5) on the left and 0.8 (1.5) on the right. She had punctate keratitis on the lower part of the cornea of both eyes. Lacrimation was declining and it was 3 mm to the right and 5 mm to the left on Schirmer's test (the normal level is 15 mm or more). Neither the salivary glands

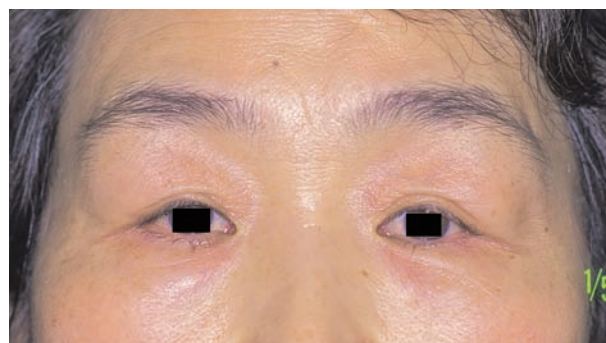


Fig. 1. Clinical photograph of the patient at the initial visit showing bilateral temporal upper eyelid swelling.

Received : December 2, 2012

Revised : December 25, 2012

Accepted : January 15, 2013

¹⁾Division of Ophthalmology, National Hospital Organization Okayama Medical Center, Okayama, Japan

²⁾Department of Pathology, Okayama University Graduate School of Medicine, Okayama, Japan

Corresponding author : Dr. Koh-ichi Ohshima, Division of Ophthalmology, National Hospital Organization Okayama Medical Center, 1711-1 Tamasu, Okayama 701-1154, Japan

E-mail : ohshima@okayama3.hosp.go.jp

nor the regional lymph nodes were swollen. No abnormalities were observed upon blood testing. However, immunoglobulin in the serum, including the serum IgG4 level and the serum IgG level, was not measured.

On orbital magnetic resonance imaging, an abnormal shadow was observed in the bilateral lacrimal gland. The mass showed a molding figure and low signal intensity in both T1-weighted image and T2-weighted image. Sinusitis in the ethmoidal sinus, sphenoidal sinus, and frontal sinus was also observed along with thickening of the nasal mucosa (Fig. 2a). No abnormality could be found on a systemic computed tomography scan other than in the bilateral lacrimal gland. On gallium scintigraphy, no abnormal accumulation was observed other than in the bilateral lacrimal gland.

From the clinical findings, we suspected a lymphoproliferative disorder and thus performed an incisional biopsy of the tumor in the lacrimal gland. First, the tumor on the left side was excised, followed by excision of the tumor on the right side one week later.

With respect to the pathology, extranodal marginal zone lymphoma of mucosa-associated lymphoid tissue type (MALT lymphoma) was strongly suspected. For the time being, follow-up alone was to be continued without radiation therapy, upon obtaining consent from the patient. In addition to the treatment for the lacrimal gland lesions, the administration of epinastine hydrochloride at a dosage of 20 mg/day and 0.01% betamethasone eye drops twice a day to both eyes was commenced in order to treat both allergic rhinitis and allergic conjunctivitis. These agents were continuously used for 10 years or longer. However, the clinical presentation was mild during June to August every year, so the agents were tempo-

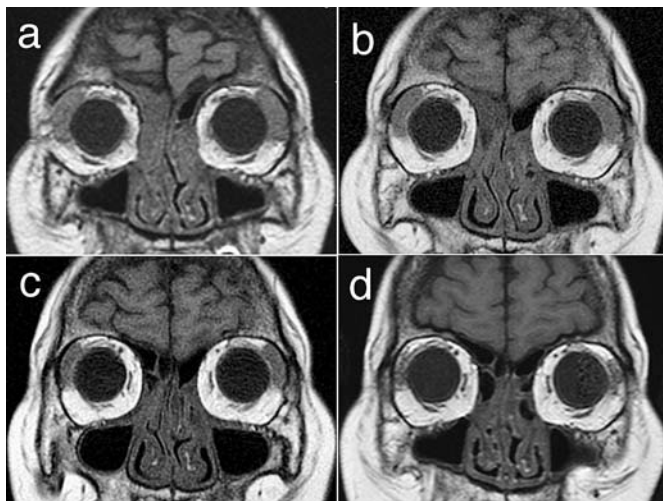


Fig. 2. The chronological change in magnetic resonance images. Magnetic resonance images of Figures 2a, 2b, 2c, & 2d were taken on 2002/01/23 (2a), 2002/09/17 (2b), 2003/10/21 (2c), and 2009/04/28 (2d), respectively. The lacrimal gland lesion decreased in size over time, becoming predominantly normal after 7 years.

rarily withdrawn during this period.

Magnetic resonance images were taken 4 times within the 7 years from the commencement of agent administration (Fig. 2a-2d). The lacrimal gland lesion decreased in size over time, becoming substantially normal at 7 years following the commencement of agent administration (Fig. 2d). The chronological change in magnetic resonance images is shown in Fig. 2.

The concept of IgG4-related diseases became widely known during the follow-up period. Around the 6th year after the initial consultation, we suspected that this case might involve an IgG4-related disease, so we re-examined the blood and pathology specimens. As a result, the serum IgG4 level was found to have increased to 540 mg/dL, while IgG4/IgG was 36.2% (Table 1). According to this result, we re-examined previously biopsied samples. Histologically, the lesions showed diffuse and dense lymphoplasmacytic infiltration with scattered eosinophils. There were interspersed reactive lymphoid follicles and mild fibrosis (Fig. 3a & 3b). The lymphoid cells were CD20⁺, CD3⁻, CD5⁻, CD10⁻, and cyclinD1⁻. The lymphoid follicles were CD10⁺ and Bcl-2⁻. Abundant mature plasma cells were IgG4⁺, and the IgG4⁺/IgG⁺ cell ratio was > 90% (Fig. 3c & 3d). These findings were consistent with IgG4-related disease.⁴

Table 1. Laboratory data

Parameters	Values	Normal range
Red blood cells (/ μ L)	3.94×10^6	$3.80 \sim 4.80 \times 10^6$
Hemoglobin (g/dL)	11.5	11.5~14.5
Hematocrit (%)	34.6	35.0~45.0
Platelets (/ μ L)	170×10^3	$150 \sim 350 \times 10^3$
MCV (fl)	87.8	83.0~100.0
MCH (pg)	29.2	28.0~34.0
White blood cells (/ μ L)	6.2×10^3	$3.5 \sim 8.5 \times 10^3$
Segmented neutrophils (%)	73.4	40.0~70
Eosinophils (%)	2.1	1.0~6.0
Basophils (%)	0.3	0.0~2.0
Monocytes (%)	6.6	2.0~9.0
Lymphocytes (%)	17.6	20.0~50.0
Total protein (g/dL)	7.3	6.5~8.0
Albumin (g/dL)	4.3	4.0~5.0
A/G (%)	1.4	1.3~2.0
Albumin (%)	60.3	60.6~72.0
α 1 (%)	2.5	1.8~3.2
α 2 (%)	8.0	5.8~10.2
β (%)	8.7	6.1~9.9
γ (%)	20.5	10.1~20.1
M protein (%)	0.0	0.0
Immunoglobulin G (mg/dL)	1,491	870~1,700
Immunoglobulin G4 (mg/dL)	540	< 135
C-reactive protein PR (mg/dL)	0.59	0.00~0.30
Rheumatoid factor (IU/mL)	8	0~15
Anti-nuclear antibody	80	< 40
Speckled	80	
Nucleolar	40	

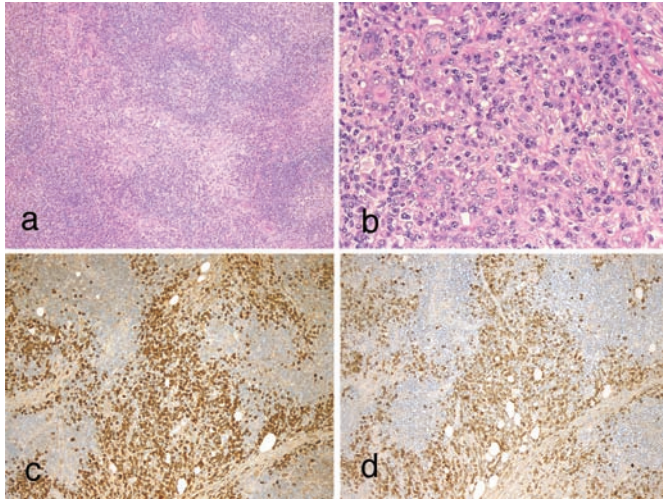


Fig. 3. Histological and immunohistochemical findings. (*3a* & *3b*) Diffuse and dense lymphoplasmacytic infiltration with lymphoid follicles and mild fibrosis (H&E stain). (*3c* & *3d*) The majority of plasma cells are IgG4⁺, and the IgG4⁺/IgG⁺ cell ratio is high (*3c*, IgG4 immunostaining; *3d*, IgG immunostaining).

DISCUSSION

The treatment of choice for IgG4-related diseases is systemic steroid administration. Rituximab may be used to treat IgG4-related diseases, but its effectiveness remains controversial.¹⁻³ However, in mild cases, follow-up alone may also sometimes be successfully carried out without any particular treatment. In our case study, MALT lymphoma was initially strongly suspected with respect to the pathology. The lacrimal gland lesion decreased as the follow-up continued without radiation therapy. Subsequently, the pathological diagnosis was revised to IgG4-related dacryoadenitis.

Three hypotheses may be proposed regarding the mechanism by which the lacrimal gland lesion decreased in size: spontaneous remission, the effect of betamethasone eye drops, and the effect of epinastine hydrochloride administration.

1. Spontaneous remission: Since IgG4-related dacryoadenitis is a type of inflammation, it is possible that such inflammation may gradually subside over time.

2. Betamethasone eye drops: There are no reports on the drug level in the lacrimal gland following betamethasone eye drop administration. Accordingly, the drug level in the lacrimal gland lesion following eye drop administration is unknown. However, according to the general consensus among ophthalmologists, the effect of betamethasone eye drops is limited to the anterior segment of the eye, such as the conjunctiva, episclera, cornea, anterior chamber, and chamber angle.

Betamethasone eye drops are absorbed by the conjunctiva, lacrimal duct, and nasal cavity, and thereafter may be transferred throughout the body. The peak blood concen-

tration level following administration of one betamethasone eye drop was about 500 pg/mL.⁵ Meanwhile, the peak blood concentration level following the oral intake of 2 betamethasone pills (1.0 mg) was 3 ng/mL.⁶ Namely, blood concentration level decreases substantially following betamethasone eye drop administration in comparison to that upon oral intake. Accordingly, betamethasone eye drop administration is not considered to be effective for the treatment of dacryoadenitis.

3. Epinastine hydrochloride administration: The side effects of the present agent, such as sleepiness, are milder than those of other anti-allergic agents, so there is less resistance to the continuous use of the agent for a long time. The medicinal actions of epinastine hydrochloride include selective H1 receptor antagonism, leukotriene C4 and platelet-activating factor antagonism, and histamine and slow-reacting substance of anaphylaxis (SRS-A) isolation-inhibiting action.⁷⁻¹⁰ It is unknown how these medicinal actions act upon IgG4-related inflammation, but the possibility of them being effective cannot be ruled out. IgG4-related diseases respond well to steroid therapy. However, such cases frequently relapse after a reduction of steroids. Accordingly, some steroids must be continuously administered for a long period of time, although the risk of side effects increases as the total dosage increases.

Patients suffering from IgG4-related diseases often demonstrate complications with allergic diseases, suggesting the involvement of an allergic mechanism in the pathophysiology.¹¹ Interestingly, our patient had allergic complications as well. As a result, epinastine hydrochloride administration may have been involved in the remission of the lacrimal gland lesions in this case.

Our case study suggests that the steroid dosage may be reduced while maintaining the remission of IgG4-related diseases by the concomitant administration of epinastine hydrochloride.

REFERENCES

- 1 Khosroshahi A, Stone JH: Treatment approaches to IgG4-related systemic disease. *Curr Opin Rheumatol* 23:67-71, 2011
- 2 Khosroshahi A, Bloch DB, Deshpande V, Stone JH: Rituximab therapy leads to rapid decline of serum IgG4 levels and prompt clinical improvement in IgG4-related systemic disease. *Arthritis Rheum* 62:1755-1762, 2010
- 3 Murakami J, Matsui S, Ishizawa S, Arita K, Wada A, *et al.*: Recurrence of IgG4-related disease following treatment with rituximab. *Mod Rheumatol* [2012 Sep 6. DOI:10.1007/s10165-012-0738-2]
- 4 Deshpande V, Zen Y, Chan JK, Yi EE, Sato Y, *et al.*: Consensus statement on the pathology of IgG4-related disease. *Mod Pathol* 25:1181-1192, 2012
- 5 Murazaki M, Mishima H, Miyachi Y: Ocular steroid therapies. 1.

- Plasma betamethasone level after topical application to eyes. *Nihon Ganka Gakkai Zasshi* 82:63-67, 1978 (*in Japanese*)
- 6 Miyachi Y, Yotsumoto H, Kano T, Mizuchi A, Muto T, *et al.*: Blood levels of synthetic glucocorticoids after administration by various routes. *J Endocrinol* 82:149-157, 1979
 - 7 Fügner A, Bechtel WD, Kuhn FJ, Mierau J: *In vitro* and *in vivo* studies of the non-sedating antihistamine epinastine. *Arzneimittelforschung* 38:1446-1453, 1988
 - 8 Tasaka K, Akagi M, Izushi K, Aoki I: Antiallergic effect of epinastine: the elucidation of the mechanism. *Pharmacometrics* 39:365-373, 1990
 - 9 Kamei C, Akagi M, Mio M, Kitazumi K, Izushi K, *et al.*: Antiallergic effect of epinastine (WAL 801 CL) on immediate hypersensitivity reactions: (I). Elucidation of the mechanism for histamine release inhibition. *Immunopharmacol Immunotoxicol* 14:191-205, 1992
 - 10 Kamei C, Mio M, Kitazumi K, Tsujimoto S, Yoshida T, *et al.*: Antiallergic effect of epinastine (WAL 801 CL) on immediate hypersensitivity reactions: (II). Antagonistic effect of epinastine on chemical mediators, mainly antihistaminic and anti-PAF effects. *Immunopharmacol Immunotoxicol* 14:207-218, 1992
 - 11 Sato Y, Notohara K, Kojima M, Takata K, Masaki Y, *et al.*: IgG4-related disease: Historical overview and pathology of hematological disorders. *Pathol Int* 60:247-258, 2010