

Original Article

Clinical Features and Treatment of Multicentric Castleman's Disease : A Retrospective Study of 21 Japanese Patients at a Single Institute

Hiroshi Kawabata,¹⁾ Norimitsu Kadowaki,¹⁾ Momoko Nishikori,¹⁾ Toshio Kitawaki,¹⁾
Tadakazu Kondo,¹⁾ Takayuki Ishikawa,¹⁾ Hajime Yoshifuji,²⁾ Noriyuki Yamakawa,²⁾
Yoshitaka Imura,²⁾ Tsuneyo Mimori,²⁾ Yumi Matsumura,³⁾ Yoshiki Miyachi,³⁾
Takeshi Matsubara,⁴⁾ Motoko Yanagita,⁴⁾ Hironori Haga,⁵⁾ and Akifumi Takaori-Kondo¹⁾

Multicentric Castleman's disease (MCD) is a rare polyclonal lymphoproliferative disorder that manifests with lymphadenopathy and inflammatory symptoms. In order to clarify the clinical features and actual management of MCD in Japan, we analyzed 21 patients diagnosed with MCD and treated in Kyoto University Hospital between 2005 and 2012. There were 12 men and 9 women. The median age at disease onset was 46 years, and the median follow-up period was 98 months. Common symptoms included splenomegaly (13/20), renal dysfunction (11/21), interstitial pneumonia (7/21), pleural effusion and/or ascites (7/21), and thrombocytopenia (6/21). The results of the anti-human immunodeficiency virus antibody and human herpes virus-8 DNA tests in the blood were available in 13 and 5 cases, respectively, and no patient was positive for either. Among 12 patients treated with tocilizumab, an anti-interleukin-6 receptor antibody, 11 exhibited an improvement in MCD-related symptoms and 3 achieved complete resolution of all these symptoms. In 8 patients treated with tocilizumab for over 1 year, the mean Hb level increased from 7.4 to 12.2 g/dL while the mean serum C-reactive protein level decreased from 13.2 to 0.4 mg/dL. Three patients died during the observation period due to sepsis, secondary leukemia, or pancreatic cancer. The clinical courses of most cases were indolent; however, in some cases with pleural effusion, ascites, renal dysfunction, and/or thrombocytopenia, the disease manifestation was serious. A nationwide survey is required to further clarify the epidemiology, clinical features, and optimal treatment strategies of MCD in Japan. [*J Clin Exp Hematop* 53(1): 69-77, 2013]

Keywords: idiopathic plasmacytic lymphadenopathy, interleukin-6, tocilizumab, TAFRO syndrome

INTRODUCTION

Castleman's disease (CD), also known as giant or angio-follicular lymph node hyperplasia, is a rare polyclonal lymphoproliferative disorder named after the pathologist who first described a series of 13 cases involving mediastinal lymph node hyperplasia.¹ CD is classified into 3 categories according to the histopathological features of the affected lymph

nodes; the hyaline-vascular, plasma cell, and mixed types.² CD is also categorized as either unicentric CD (UCD) or multicentric CD (MCD) on the basis of the lymph node lesions involved. In most UCD cases, patients are asymptomatic or manifest anemia only, and the disease is curable by resection of affected lymph nodes.³ In contrast, patients with MCD exhibit various systemic symptoms such as fever, night sweats, general malaise, weight loss, hepatosplenomegaly, and anemia. Laboratory tests of these patients show elevated serum C-reactive protein (CRP) level, polyclonal hyper- γ -globulinemia, microcytic anemia, low serum albumin level, and hypocholesterolemia. In Western countries, human herpes virus-8 (HHV-8) is frequently associated with the pathogenesis of MCD, especially in human immunodeficiency virus (HIV)-positive individuals, and the disease prognosis is generally poor.^{4,5} In contrast, Japanese MCD cases are seldom associated with HHV-8 and usually have indolent clinical courses.⁶ MCD sometimes overlaps with the POEMS

Received : January 15, 2013

Revised : February 7, 2013

Accepted : February 8, 2013

¹⁾Department of Hematology and Oncology, ²⁾Department of Rheumatology and Clinical Immunology, ³⁾Department of Dermatology, ⁴⁾Department of Nephrology, and ⁵⁾Department of Diagnostic Pathology, Graduate School of Medicine, Kyoto University, Kyoto, Japan.

Corresponding author : Hiroshi Kawabata, M.D., Department of Hematology and Oncology, Graduate School of Medicine, Kyoto University, 64 Shogoin-Kawaharacho, Sakyo-ku, Kyoto 606-507, Japan
e-mail, hkawabat@kuhp.kyoto-u.ac.jp

(polyneuropathy, organomegaly, endocrinopathy, M-protein, and skin pigmentation) syndrome, IgG4-related disease, and collagen diseases. MCD is now regarded as a morphologic syndrome uniting a group of diseases with various etiologies.⁷⁻⁹

Patients with MCD commonly require systemic therapies with corticosteroids, immunosuppressants such as cyclosporin A, or tocilizumab, an interleukin (IL)-6 receptor antibody. However, the treatments of this disease is often challenging. There is no practical guideline for the treatment of MCD, although the remarkable efficacies of tocilizumab against this disease have been reported previously.¹⁰⁻¹³ The purpose of this study is to clarify the strategies for diagnosing and treating Japanese MCD patients in the tocilizumab era. Here, we describe the clinical features, actual treatments, and clinical courses of 21 Japanese patients diagnosed with MCD and treated in Kyoto University Hospital between January 2005 and October 2012.

METHODS

Patients and medical records

This study was approved by the ethics committee of the Kyoto University Graduate School and Faculty of Medicine. First, CD patients were screened in the electronic medical record system of Kyoto University Hospital using the keyword "Castleman's disease". Thirty-four patients were picked up by this screening. Then, the individual records of these patients were carefully reviewed by physicians. As a result, 21 patients treated under the diagnosis of MCD between January 2005 and October 2012 were identified. One of these cases, which was complicated with dilated cardiomyopathy, was reported previously.¹¹ In this study, patients with typical systemic lupus erythematosus (SLE) and POEMS syndrome were excluded even if the histology of the lymph nodes was compatible with CD. The detailed clinical data of these 21 patients in the medical record system were analyzed in this study.

Criteria of symptoms

Anemia was defined as Hb level < 12 g/dL, and thrombocytopenia was defined as a platelet count < 100,000//L. Spleen size was evaluated by radiologists using computed tomography scans. Renal dysfunction was defined as the presence of at least one of the following ; histopathologically proved renal diseases (e.g., glomerulonephritis and membrane nephropathy), elevated serum creatinine levels above the reference range, proteinuria > 3.5 g/24 hr, and hydronephrosis.

Statistical analysis

Pearson's correlation coefficients were used to assess the correlations between clinical parameters. A 2-tailed paired *t*-test was performed to compare the mean values of clinical parameters before and after tocilizumab treatment. The level of significance was set at $P < 0.05$.

RESULTS

Patient characteristics

There were 12 men and 9 women. The median age at disease onset was 46 yr (range, 13-70 yr), and the median duration between disease onset and time of MCD diagnosis was 27.5 mon (range, 2-156 mon). The median duration between disease onset and the last follow-up was 98 mon (range, 29-252 mon).

Diagnostic procedures

The actual diagnostic procedures of MCD were essentially as follows. First, the possibility of MCD was suspected by the attending physician according to clinical features such as systemic lymphadenopathy, elevated serum CRP levels, and hyper- γ -globulinemia with a polyclonal pattern. Infectious diseases were ruled out by blood cultures and serological tests. In some cases, antibiotics were prescribed and found to be ineffective. Subsequently, the physician performed further detailed blood tests and computed tomography (CT) and/or ¹⁸fluorine-labeled fluorodeoxyglucose positron emission tomography (FDG-PET) scans and referred the patient to rheumatologists to rule out typical collagen diseases. Bone marrow aspiration and biopsy were performed in 12 and 6 cases, respectively, to rule out bone marrow infection and hematological malignancies. Lymph node biopsy was subsequently performed. Malignant lymphomas, histiocytic necrotizing lymphadenitis (Kikuchi-Fujimoto disease), granulomas, and IgG4-related disease were excluded.¹⁴ Finally, a diagnosis of MCD was made if the histological findings were consistent with it.

Histopathological features

Detailed information about the histopathological features of the involved lymph nodes was available in 19 cases ; 18 were of the plasma cell type, and 1 was a mixture of the plasma cell and hyaline vascular types. Bone marrow examination results were available in 12 cases ; there were 6 hypercellular, 3 normocellular, and 3 hypocellular marrows, and 6 patients exhibited various degrees of plasma cell proliferation. Bone marrow biopsy was performed in 6 cases, and reticulin myelofibrosis was observed in 3 patients (Fig. 1).

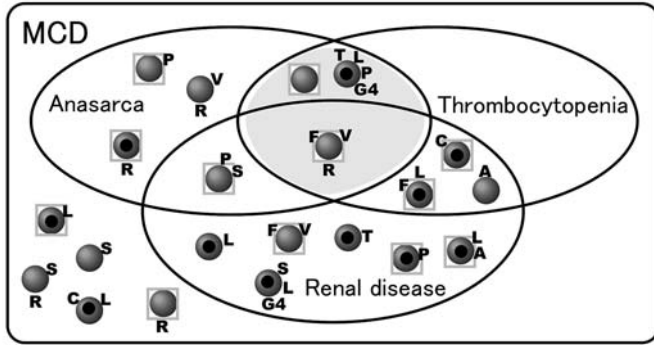


Fig. 1. Symptoms and characteristics of individual cases of multicentric Castleman's disease (MCD). Each case is shown as a sphere. Cases were categorized according to 3 major symptoms; anasarca (i.e., pleural effusion and/or ascites), thrombocytopenia, and renal disease. Other symptoms and characteristics of each case are indicated by capital letters or symbols as follows; A, autoimmune hemolytic anemia (Coombs test positive); C, hypocomplementemia together with circulating immune complex test positive results; F, documented myelofibrosis; G4, elevated serum IgG4 level with relatively low serum interleukin-6 level (IgG4-related disease); L, lung disease (interstitial pneumonia, etc.); P, chronic pancreatitis and/or pancreatic cancer; R, complete resolution of all disease symptoms achieved; S, skin lesion; T, chronic thyroiditis; V, vascular events (cerebral infarction, etc.); ●, serum IgG > 3,500 mg/dL (idiopathic plasmacytic lymphadenopathy, IPL type); □ (square frame), tocilizumab treatment applied. Candidate cases of TAFRO (thrombocytopenia, anasarca, fever, reticulosis and organomegaly) syndrome are located in the gray area.

Clinical features

The most common symptoms observed in our MCD patients were anemia and lymphadenopathy. These symptoms were observed in all patients at some point during the clinical course. Other common symptoms were hepatosplenomegaly, renal dysfunction, fever, pleural effusion, ascites, pulmonary diseases such as lymphocytic interstitial pneumonia, and thrombocytopenia (Table 1). Twenty out of 21 patients had at least one of the following symptoms; renal dysfunction, pleural effusion or ascites, pulmonary diseases (i.e., interstitial pneumonia), thrombocytopenia, and skin lesions (Fig. 1). Among the 11 patients with renal dysfunction, 4 required transient or permanent hemodialysis. Other symptoms and coexisting diseases included chronic pancreatitis in 4 patients (1 of them eventually developed pancreatic cancer), vascular events in 3 patients, chronic thyroiditis in 2 patients, liver cirrhosis in 2 patients, dilated cardiomyopathy (i.e., left ventricular ejection fraction < 50%) in 2 patients, autoimmune hemolytic anemia in 2 patients, and secondary leukemia probably due to cyclophosphamide treatment in 1 patient. The laboratory data at disease onset (or earliest available data after

Table 1. Frequencies of symptoms and coexisting diseases in multicentric Castleman's disease patients

Symptoms/coexisting diseases	Frequency
Lymphadenopathy	100% (21/21)
Anemia	100% (21/21)
Splenomegaly	65% (13/20*)
Renal dysfunction	52% (11/21)
Fever (> 38°C)	35% (7/20*)
Pulmonary diseases**	33% (7/21)
Pleural effusion and/or ascites	33% (7/21)
Thrombocytopenia	28% (6/21)
Skin lesions	19% (4/21)
Chronic pancreatitis	19% (4/21)
Diabetes	19% (4/21)
Heart failure	14% (3/21)
Vascular events	14% (3/21)

*, Information at the disease onset was missing in one case each. **, Lymphocytic interstitial pneumonia was the predominant pulmonary disease.

Table 2. Summary of laboratory data at disease onset and the time of exacerbation

Lab data	At disease onset*	At the time of exacerbation**
WBC ($\times 10^3/\mu\text{L}$)	6.7 (1.3-20.7)	
Hemoglobin (g/dL)	10.0 (6.9-13.7)	6.7 (4.2-10.8)
MCV (fL)	86.8 (66.2-98.8)	81.3 (68.4-97.4)
PLT ($\times 10^3/\mu\text{L}$)	283 (39-564)	
LDH (IU/L)	115 (77-289)	
ALP (IU/L)	286 (79-1469)	
ALB (g/dL)	2.9 (2.1-3.6)	2.2 (1.5-3.3)
CRP (mg/dL)	7.5 (0.1-20.3)	11.0 (3.1-30.7)
IgG (mg/dL)	4,918 (1,425-7,537)	
TSAT (%)	9.9 (6.4-47.8)	
Ferritin (ng/mL)	171 (31-735)	

Median values and the ranges are shown. *, In some cases, laboratory data at disease onset were not available; the earliest available data after the onset were used instead. **, At the time of the lowest hemoglobin level in each case during the disease course. The data of hemoglobin, MCV, serum albumin, and CRP are shown. Reference ranges are as follows; LDH, 124-226 IU/dL; ALP, 115-359 IU/dL; CRP, < 0.2 mg/dL; TSAT, 10-50%.

WBC, white blood cell count; MCV, mean corpuscular volume; PLT, platelet; LDH, lactate dehydrogenase; ALP, alkaline phosphatase; ALB, albumin; CRP, C-reactive protein; TSAT, transferrin saturation

onset for some patients) and at the time of exacerbation are summarized in Table 2. Microcytic anemia, hypoalbuminemia, elevation of serum CRP and IgG levels, and decreases in the serum lactate dehydrogenase levels were common features. The severity of microcytosis and anemia were associated with the elevation of serum CRP levels (Fig. 2). The transferrin saturation level decreased, while the serum ferritin level did not; these were consistent with the abnormal iron metabolism in anemia of inflammation.¹⁵ The median values

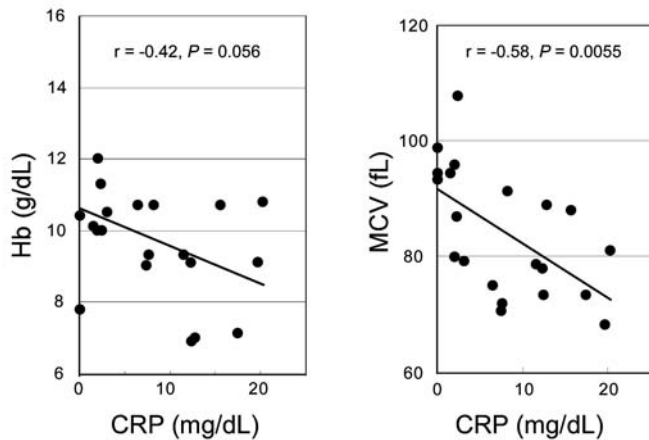


Fig. 2. Relationships between C-reactive protein (CRP) and either hemoglobin (Hb) level or mean corpuscular volume (MCV) in multicentric Castleman's disease patients at disease onset. For cases in which laboratory data at disease onset were unavailable, the earliest available data after the onset were used instead.

of soluble IL-2 receptor antibody, a biomarker of malignant lymphomas, and serum IL-6, an inflammatory cytokine, were elevated to 1,450 U/mL (range, 512-3,940 U/mL; $n = 16$, reference range, 145-519 U/mL) and 21.9 pg/mL (range, 2.9-128 pg/mL; $n = 18$; reference range, < 6.0 pg/mL), respectively. Serum IL-6 level was significantly correlated with the serum CRP level; however, a few patients had relatively low serum IL-6 levels despite high CRP levels (Fig. 3). The results for the anti-HIV antibody and HHV-8 DNA in the blood were available for 13 and 5 patients, respectively; no patient was positive for either. Serum IgG4 levels were measured in 9 patients and 6 showed elevation of the IgG4/IgG ratio exceeding 10%. Anti-nuclear antibody test results was available for 14 patients; the results were positive for 11 of them.

Treatments and clinical courses

Corticosteroids such as prednisolone, methylprednisolone, dexamethasone, and betamethasone were used in 18 of the 21 cases; tocilizumab was used in 12 cases; cyclophosphamide was used in 4 cases; and melphalan was used in 2 cases. Other drugs used to control MCD-related symptoms included vincristine, cyclosporine A, mizoribine, methotrexate, thalidomide, and bortezomib in 1 case each. Some patients were treated with combinations of these drugs.

Two patients achieved complete resolution of MCD-related symptoms with prednisolone alone. In one of these patients, the dose of prednisolone was carefully tapered and discontinued without any sign of disease recurrence. In most of the other patients, corticosteroids were somehow controlling the disease activity. However, secondary diabetes devel-

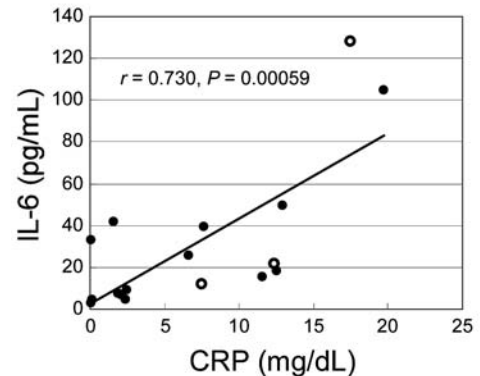


Fig. 3. Relationship between serum interleukin (IL)-6 and C-reactive protein (CRP) levels in multicentric Castleman's disease patients. Serum IL-6 was measured in 18 patients, and the earliest available data of each case are plotted. Open circles indicate the values of the 3 patients who achieved complete resolution of the disease symptoms after tocilizumab treatment.

oped in some patients.

Generally, tocilizumab was used for patients with severe symptoms or for those whose symptoms were refractory to corticosteroids (Fig. 1). Among the 12 patients treated with tocilizumab, some MCD-related symptoms improved in 11 patients and 3 achieved complete resolution of all MCD-related symptoms including lymphadenopathy and anemia. Two weeks after the initiation of tocilizumab therapy, the mean Hb and serum albumin levels of these 12 patients increased from 7.6 to 7.9 g/dL ($P = 0.010$) and from 2.5 to 2.9 g/dL ($P = 0.0062$), respectively; meanwhile, the mean serum CRP level decreased from 10.8 to 2.5 mg/dL ($P = 0.0015$). Eight patients were treated with tocilizumab for more than one year (Fig. 4). Their mean hemoglobin and serum albumin levels increased from 7.4 to 12.2 g/dL and from 2.5 to 3.8 g/dL, respectively, and the mean serum CRP level decreased from 13.2 to 0.4 mg/dL at the time of tocilizumab discontinuation ($n = 2$) or at the latest follow-up for those still continuing this therapy ($n = 6$). Serum IL-6 levels in 5 patients were monitored beyond 1 yr. Serum IL-6 levels increased drastically in all the patients after the initiation of this therapy, as reported previously (Fig. 5).¹⁶ While serum IL-6 levels stayed high until the end of monitoring in 2 cases, they decreased gradually to the basal levels in 3 patients who achieved complete resolution of the disease symptoms; the doses of tocilizumab for these 3 patients were tapered. Tocilizumab therapy was interrupted in 1 patient each because of infection and allergic reaction, and was resumed safely 4 and 34 mon after the interruption, respectively. By October 2012, seven patients were still being treated with this drug; 4 patients were using tocilizumab for over 6 yr without any

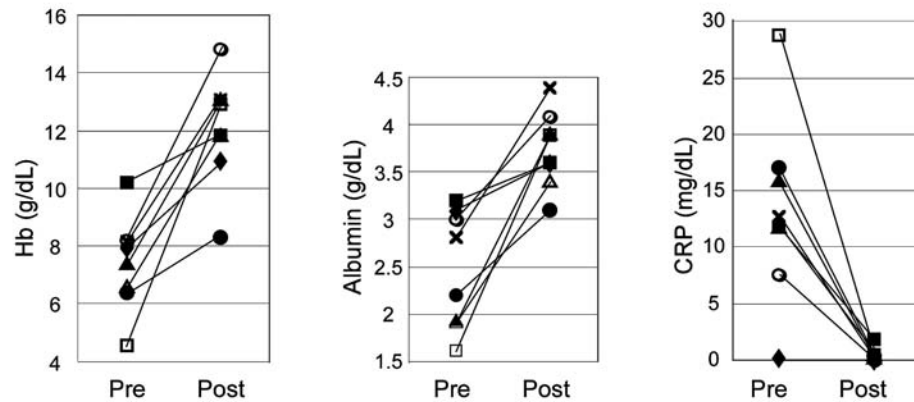


Fig. 4. Efficacy of tocilizumab therapy in multicentric Castleman's disease patients. Eight patients were treated with tocilizumab for over 1 year. For each patient, hemoglobin (Hb), serum albumin, and C-reactive protein (CRP) levels before the initiation of tocilizumab therapy (before) and at the time of their latest visit or discontinuation of this therapy (after) are connected with a line.

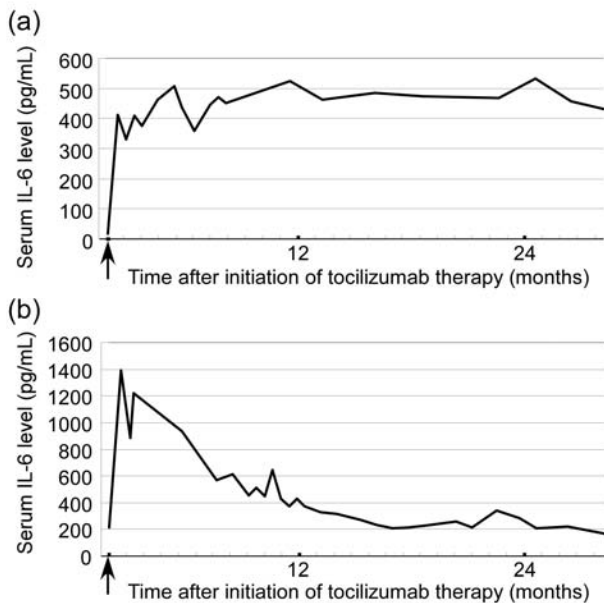


Fig. 5. Time courses of serum interleukin (IL)-6 levels of the representative patients. **(5a)** Serum IL-6 levels were high throughout the observation period. This patient achieved partial resolution of the disease symptoms. **(5b)** Serum IL-6 level gradually decreased. This patient achieved complete resolution of the disease symptoms. In both cases, serum IL-6 levels increased drastically after the initiation of tocilizumab therapy (arrows).

adverse events. The reasons for discontinuation of this therapy (each in 1 case) were the development of pancreatic cancer, progression of secondary leukemia, insufficient response, complete resolution of the disease symptoms, and economic difficulties.

Three patients died during the observation period ; 1 died

due to sepsis 8 years after disease onset, 1 died due to secondary leukemia 18 years after onset, and 1 died due to pancreatic cancer 8 years after onset. The patient with secondary leukemia had been treated with cyclophosphamide for a long period and developed myelodysplastic syndrome 16 years after onset, which eventually transformed into leukemia.

DISCUSSION

In this study, we analyzed the clinical features and disease courses of 21 Japanese MCD patients from a single institute. Since MCD is a very rare clinical entity, only a few large case series have been published to date. Herrada *et al.* reported 15 CD cases including 8 MCD cases,¹⁷ and Bowne *et al.* reported 16 CD cases including 3 MCD cases in the United States.³ In Western countries, a large proportion of MCD cases are associated with HIV and HHV-8, and have relatively aggressive disease courses.⁵ Kojima *et al.* analyzed the clinicopathological features of 28 MCD patients in Japan, and they found that the characteristics of MCD in Japan were quite different from those in Western countries.⁶ Consistent with their report, none of the present patients were HIV seropositive and most had indolent clinical courses as indicated by the median duration between disease onset and the last follow-up (98 mon). Two other relatively large case series have been reported from Asian countries ; Ye *et al.* summarized 52 CD cases including 4 MCD cases in China,¹⁸ and Shin *et al.* summarized 70 CD cases including 27 MCD cases in Korea.¹⁹ The current study identified 21 MCD cases but only 3 UCD cases in our medical record system in the same period. Therefore, the frequencies of UCD and MCD might differ among Asian countries.

Diagnosing MCD is sometimes challenging. The median duration between disease onset and the time of diagnosis in

the present cohort was 27.5 mon, reflecting the difficulties in diagnosing MCD. The relationships between MCD and associated diseases are illustrated in Fig. 6. A number of diseases, such as infectious, IgG4-related, and neoplastic diseases should be excluded before diagnosing MCD. Not only malignant lymphomas but also myeloid malignancies such as myeloproliferative neoplasms and myelodysplastic syndromes can cause systemic inflammation and lymphadenopathy. Especially, the clinical and histological features of IgG4-related disease can be quite similar to and sometimes indistinguishable from those of MCD. In fact, there were 6 patients of MCD with elevated serum IgG4/IgG ratios. Sato *et al.* claim that the serum IL-6 level, which is usually not elevated in IgG4-related disease, is a useful marker for distinguishing these 2 entities.⁹ Among the 6 patients with elevated serum IgG4/IgG ratios, the serum IL-6 and CRP levels were not elevated in 2 patients; retrospectively, these 2 cases should have been categorized as IgG4-related disease.

MCD is a clinicopathological entity that sometimes overlaps with others such as autoimmune diseases and POEMS syndrome; this also makes it difficult to diagnose MCD. The current study excluded patients whose symptoms fulfilled the criteria of classification for SLE,²⁰ a representative autoimmune disease, and those with POEMS syndrome who had M-proteinemia from our MCD cases. However, some investigators state that these clinical entities can overlap with MCD

(Fig. 6). In fact, the common clinical manifestations of MCD, including renal dysfunction, pleural effusion, ascites, thrombocytopenia, pulmonary diseases, and skin lesions, are also common in SLE. Moreover, patients with SLE and rheumatoid arthritis sometimes manifest systemic lymphadenopathy; the histological features of the lymph nodes in these diseases could be indistinguishable from those of MCD.²¹⁻²³ POEMS syndrome is another disease entity that can overlap with MCD. The major criteria for POEMS syndrome are polyneuropathy, organomegaly, endocrinopathy, M-proteinemia, and skin pigmentation.²⁴ The presence of M-protein indicates that at least a proportion of plasma cells in patients with POEMS syndrome are monoclonal. The histological features of lymph nodes of POEMS syndrome patients are often indistinguishable from those of plasma cell type CD.²⁵

It is widely accepted that, although the etiology of MCD appears heterogeneous, IL-6 is strongly associated with the clinical manifestations of MCD.²⁶ In Western countries, HHV-8, also known as Kaposi's sarcoma-associated herpes virus, plays an important role in the pathogenesis of many MCD cases.^{4,27-29} The HHV-8 genome encodes a viral IL-6 gene that shares about 25% identity with its human counterpart.³⁰ The viral IL-6 of HHV-8 can cause MCD in mice by collaborating with the endogenous IL-6.³¹ HHV-8 infection is found not only in MCD, but also in patients with

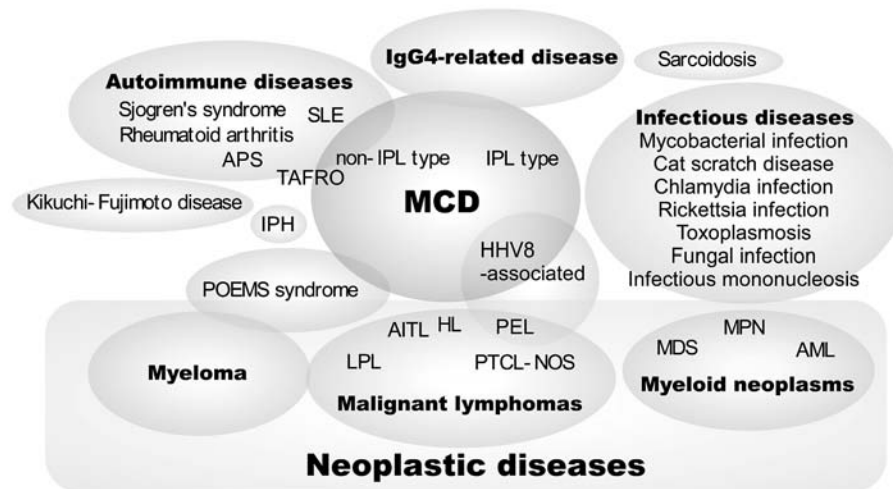


Fig. 6. Images of the disease entities of multicentric Castleman's disease and related diseases. Abbreviations; AITL, angioimmunoblastic T-cell lymphoma; AML, acute myeloid leukemia; APS, anti-phospholipid syndrome; HHV-8, human herpes virus-8; HL, Hodgkin's lymphoma; IPH, idiopathic portal hypertension; IPL, idiopathic plasmacytic lymphadenopathy; LPL, lymphoplasmacytic lymphoma; MCD, multicentric Castleman's disease; MDS, myelodysplastic syndromes; MPN, myeloproliferative neoplasms; PEL, primary effusion lymphoma; PTCL-NOS, peripheral T-cell lymphoma not otherwise specified; SLE, systemic lupus erythematosus; TAFRO, thrombocytopenia-anasarca-fever-myelofibrosis-organomegaly syndrome

Kaposi's sarcoma and primary effusion lymphoma with a high incidence observed in HIV infected individuals. Another viral IL-6 gene has been identified in rhesus macaque rhadinovirus, which causes retroperitoneal fibromatosis, lymphomas, and MCD in macaques.³² Viral IL-6 can presumably cause various systemic symptoms observed in MCD.³³ It is hypothesized that more viral IL-6 genes remain to be identified.

Another possible etiology of MCD in some cases is paracrine or autocrine IL-6 production. Once an inflammatory reaction occurs due to a trigger such as a viral infection, IL-6 is secreted from inflammatory cells and IL-6 stimulates plasma cell proliferation. Then, IL-6 and its downstream cytokines activate the IL-6-producing cells, further augmenting IL-6 production. This hypothesis is supported by our observations that some patients treated with tocilizumab achieved complete resolution of the disease symptoms followed by gradual decreases in serum IL-6 levels. The autoimmune reactivation of IL-6-producing cells is another presumable etiology of some MCD cases. In fact, the majority of our patients were positive for anti-nuclear antibody, and some of them were diagnosed with various autoimmune diseases such as chronic thyroiditis and autoimmune hemolytic anemia.

Kojima *et al.* classified Japanese MCD cases into 2 subcategories on the basis of clinicopathological findings; idiopathic plasmacytic lymphadenopathy (IPL) and non-IPL.⁶ IPL is characterized by prominent hyper- γ -globulinemia (IgG > 3,500 mg/dL), multicentric lymphadenopathy, high serum IL-6 levels, and plasma cell-type histology. In contrast, non-IPL is frequently associated with pleural effusion or ascites, thrombocytopenia, autoimmune diseases, and hyaline vascular-type or mixed-type histology. Kojima *et al.* reported 7 non-IPL cases with pleural effusion; 4 of them were accompanied by autoimmune thrombocytopenic purpura.³⁴ In the present series, 7 cases had pleural effusion or ascites, and 3 of them were complicated with thrombocytopenia. When we tentatively classified our cases as IPL or non-IPL on the basis of serum IgG levels (IPL, IgG > 3,500 mg/dL; non-IPL, IgG < 3,500 mg/dL), there were 11 IPL and 10 non-IPL cases. All 7 cases accompanied by lung diseases were classified as the IPL, while 5 out of 7 patients with anasarca were classified as the non-IPL (71%). Four out of 5 patients (80%) who achieved complete resolution of the disease symptoms were classified as the non-IPL MCD (Fig. 1). Kojima *et al.* also reported that the histopathological features of non-IPL MCD usually manifest the hyaline-vascular or mixed type. However, most of our MCD cases, regardless of IPL or non-IPL type, involved plasma cell-type morphology. The differences in the histopathology of non-IPL MCD may be due to differences in histological diagnostic procedures including immunohistochemical staining. Kojima *et al.* performed staining for follicular dendritic cells, which was not performed in most of our cases. Takai *et al.* recently reported 3

cases with thrombocytopenia, anasarca (i.e., ascites and/or pleural effusion), fever, reticulín myelofibrosis, and organomegaly (i.e., hepatosplenomegaly); they named this clinical entity as TAFRO syndrome by taking the initial letters of the 5 symptoms.³⁵ The histological features of the lymph nodes in 1 of their cases were consistent with the hyaline vascular type CD. According to the classification of Kojima *et al.*, TAFRO syndrome appears to overlap with non-IPL MCD (Fig. 6). Among the 21 patients in this study, there were 3 candidates of TAFRO syndrome who had thrombocytopenia together with ascites or pleural effusion (cases in the gray area in Fig. 1); in fact, myelofibrosis was found in 1 patient. Bone marrow biopsy was not performed in the other 2 cases.

Most Japanese MCD cases exhibit an indolent clinical course. However, after reviewing the clinical courses of the present patients, it was noticed that some manifested serious and life-threatening symptoms, especially in cases with ascites, pleural effusion, renal dysfunction, and/or thrombocytopenia. The majority of MCD patients at our institute have been treated with tocilizumab, which was effective in most of them. Tocilizumab is an anti-IL-6 receptor antibody that blocks the IL-6-induced inflammatory signaling pathway. In these patients, serum CRP levels started to decrease and hemoglobin and serum albumin levels started to increase within 2 weeks after the initiation of this treatment; this effect persisted in long-term users. In some patients, all MCD-related symptoms including systemic lymphadenopathy disappeared after the initiation of treatment. Some of our patients showed relatively low serum IL-6 levels with respect to their increased CRP levels (Fig. 4). However, tocilizumab effectively improved the MCD-related symptoms even in these cases. It is worth investigating whether tocilizumab is effective for HHV-8-associated MCD cases, because viral IL-6 does not require the cellular IL-6 receptor to bind to the gp130 receptor subunit to subsequently activate the JAK-STAT signaling.³⁶

We assume that the present data are largely representative of the clinical features and actual management of MCD in Japan in the tocilizumab era. However, because the present study is based on the experience of a single institute and MCD is a very rare disease entity, a nationwide survey is needed to clarify the epidemiology, clinical features and optimal treatment strategies for Japanese MCD patients.

ACKNOWLEDGEMENT

We thank Professor Shigeo Nakamura (Department of Pathology and Laboratory Medicine, Nagoya University) for encouraging and helping us in this work. We also thank Professor Kazuyuki Yoshizaki (Graduate School of Engineering, Osaka University) for valuable advices on treatment of MCD. This work was supported in part by a grant-in-aid for scientific research from the Ministry of Education,

REFERENCES

- 1 Castleman B, Iverson L, Menendez VP: Localized mediastinal lymphnode hyperplasia resembling thymoma. *Cancer* 9:822-830, 1956
- 2 Keller AR, Hochholzer L, Castleman B: Hyaline-vascular and plasma-cell types of giant lymph node hyperplasia of the mediastinum and other locations. *Cancer* 29:670-683, 1972
- 3 Bowne WB, Lewis JJ, Filippa DA, Niesvizky R, Brooks AD, *et al.*: The management of unicentric and multicentric Castleman's disease: A report of 16 cases and a review of the literature. *Cancer* 85:706-717, 1999
- 4 Soulier J, Grollet L, Oksenhendler E, Cacoub P, Cazals-Hatem D, *et al.*: Kaposi's sarcoma-associated herpesvirus-like DNA sequences in multicentric Castleman's disease. *Blood* 86:1276-1280, 1995
- 5 Oksenhendler E, Carcelain G, Aoki Y, Boulanger E, Maillard A, *et al.*: High levels of human herpesvirus 8 viral load, human interleukin-6, interleukin-10, and C reactive protein correlate with exacerbation of multicentric Castleman disease in HIV-infected patients. *Blood* 96:2069-2073, 2000
- 6 Kojima M, Nakamura N, Tsukamoto N, Otuski Y, Shimizu K, *et al.*: Clinical implications of idiopathic multicentric Castleman disease among Japanese: A report of 28 cases. *Int J Surg Pathol* 16:391-398, 2008
- 7 Cronin DM, Warnke RA: Castleman disease: An update on classification and the spectrum of associated lesions. *Adv Anat Pathol* 16:236-246, 2009
- 8 Muskardin TW, Peterson BA, Molitor JA: Castleman disease and associated autoimmune disease. *Curr Opin Rheumatol* 24:76-83, 2012
- 9 Sato Y, Kojima M, Takata K, Morito T, Mizobuchi K, *et al.*: Multicentric Castleman's disease with abundant IgG4-positive cells: A clinical and pathological analysis of six cases. *J Clin Pathol* 63:1084-1089, 2010
- 10 Nishimoto N, Kanakura Y, Aozasa K, Johkoh T, Nakamura M, *et al.*: Humanized anti-interleukin-6 receptor antibody treatment of multicentric Castleman disease. *Blood* 106:2627-2632, 2005
- 11 Kanda J, Kawabata H, Yamaji Y, Ichinohe T, Ishikawa T, *et al.*: Reversible cardiomyopathy associated with multicentric Castleman disease: Successful treatment with tocilizumab, an anti-interleukin 6 receptor antibody. *Int J Hematol* 85:207-211, 2007
- 12 Kawabata H, Tomosugi N, Kanda J, Tanaka Y, Yoshizaki K, *et al.*: Anti-interleukin 6 receptor antibody tocilizumab reduces the level of serum hepcidin in patients with multicentric Castleman's disease. *Haematologica* 92:857-858, 2007
- 13 Song SN, Tomosugi N, Kawabata H, Ishikawa T, Nishikawa T, *et al.*: Down-regulation of hepcidin resulting from long-term treatment with an anti-IL-6 receptor antibody (tocilizumab) improves anemia of inflammation in multicentric Castleman disease. *Blood* 116:3627-3634, 2010
- 14 Umehara H, Okazaki K, Masaki Y, Kawano M, Yamamoto M, *et al.*: A novel clinical entity, IgG4-related disease (IgG4RD): General concept and details. *Mod Rheumatol* 22:1-14, 2012
- 15 Ganz T: Molecular pathogenesis of anemia of chronic disease. *Pediatr Blood Cancer* 46:554-557, 2006
- 16 Nishimoto N, Sasai M, Shima Y, Nakagawa M, Matsumoto T, *et al.*: Improvement in Castleman's disease by humanized anti-interleukin-6 receptor antibody therapy. *Blood* 95:56-61, 2000
- 17 Herrada J, Cabanillas F, Rice L, Manning J, Pugh W: The clinical behavior of localized and multicentric Castleman disease. *Ann Intern Med* 128:657-662, 1998
- 18 Ye B, Gao SG, Li W, Yang LH, Zhao SH, *et al.*: A retrospective study of unicentric and multicentric Castleman's disease: A report of 52 patients. *Med Oncol* 27:1171-1178, 2010
- 19 Shin DY, Jeon YK, Hong YS, Kim TM, Lee SH, *et al.*: Clinical dissection of multicentric Castleman disease. *Leuk Lymphoma* 52:1517-1522, 2011
- 20 Tan EM, Cohen AS, Fries JF, Masi AT, McShane DJ, *et al.*: The 1982 revised criteria for the classification of systemic lupus erythematosus. *Arthritis Rheum* 25:1271-1277, 1982
- 21 Kojima M, Nakamura S, Morishita Y, Itoh H, Yoshida K, *et al.*: Reactive follicular hyperplasia in the lymph node lesions from systemic lupus erythematosus patients: A clinicopathological and immunohistological study of 21 cases. *Pathol Int* 50:304-312, 2000
- 22 Kojima M, Motoori T, Nakamura S: Benign, atypical and malignant lymphoproliferative disorders in rheumatoid arthritis patients. *Biomed Pharmacother* 60:663-672, 2006
- 23 Kojima M, Motoori T, Asano S, Nakamura S: Histological diversity of reactive and atypical proliferative lymph node lesions in systemic lupus erythematosus patients. *Pathol Res Pract* 203:423-431, 2007
- 24 Dispenzieri A: POEMS syndrome. *Blood Rev* 21:285-299, 2007
- 25 Dispenzieri A, Armitage JO, Loe MJ, Geyer SM, Allred J, *et al.*: The clinical spectrum of Castleman's disease. *Am J Hematol* 87:997-1002, 2012
- 26 Yoshizaki K, Matsuda T, Nishimoto N, Kuritani T, Taeho L, *et al.*: Pathogenic significance of interleukin-6 (IL-6/BSF-2) in Castleman's disease. *Blood* 74:1360-1367, 1989
- 27 Karcher DS, Alkan S: Herpes-like DNA sequences, AIDS-related tumors, and Castleman's disease. *N Engl J Med* 333:797-798; Author reply 798-799, 1995
- 28 Dupin N, Diss TL, Kellam P, Tulliez M, Du MQ, *et al.*: HHV-8 is associated with a plasmablastic variant of Castleman disease that is linked to HHV-8-positive plasmablastic lymphoma. *Blood* 95:1406-1412, 2000
- 29 Stebbing J, Adams C, Sanitt A, Mletzko S, Nelson M, *et al.*: Plasma HHV8 DNA predicts relapse in individuals with HIV-associated multicentric Castleman disease. *Blood* 118:271-275, 2011
- 30 Nicholas J, Ruvolo V, Zong J, Ciuffo D, Guo HG, *et al.*: A single 13-kilobase divergent locus in the Kaposi sarcoma-associated her-

- pesvirus (human herpesvirus 8) genome contains nine open reading frames that are homologous to or related to cellular proteins. *J Virol* 71:1963-1974, 1997
- 31 Suthaus J, Stuhlmann-Laeisz C, Tompkins VS, Rosean TR, Klapper W, *et al.*: HHV-8-encoded viral IL-6 collaborates with mouse IL-6 in the development of multicentric Castleman disease in mice. *Blood* 119:5173-5181, 2012
- 32 Orzechowska BU, Powers MF, Sprague J, Li H, Yen B, *et al.*: Rhesus macaque rhadinovirus-associated non-Hodgkin lymphoma: Animal model for KSHV-associated malignancies. *Blood* 112:4227-4234, 2008
- 33 Schulte KM, Talat N: Castleman's disease - a two compartment model of HHV8 infection. *Nat Rev Clin Oncol* 7:533-543, 2010
- 34 Kojima M, Nakamura N, Tsukamoto N, Yokohama A, Itoh H, *et al.*: Multicentric Castleman's disease representing effusion at initial clinical presentation: Clinicopathological study of seven cases. *Lupus* 20:44-50, 2011
- 35 Takai K, Nikkuni K, Shibuya H, Hashidate H: Thrombocytopenia with mild bone marrow fibrosis accompanied by fever, pleural effusion, ascites and hepatosplenomegaly. *Rinsho Ketsueki* 51:320-325, 2010 (*in Japanese*)
- 36 Suthaus J, Adam N, Grotzinger J, Scheller J, Rose-John S: Viral interleukin-6: Structure, pathophysiology and strategies of neutralization. *Eur J Cell Biol* 90:495-504, 2011