

Case Study

Primary Hepatic Circumscribed Burkitt's Lymphoma that Developed after Acute Hepatitis B : Report of a Case with a Review of the Literature

Yasunobu Sekiguchi,¹⁾ Hitomi Yoshikawa,¹⁾ Asami Shimada,^{1,3)} Hidenori Imai,¹⁾
Mutsumi Wakabayashi,¹⁾ Keiji Sugimoto,¹⁾ Noriko Nakamura,²⁾ Tomohiro Sawada,²⁾
Kengo Takeuchi,⁴⁾ Yasunori Ohta,⁵⁾ Norio Komatsu,³⁾ and Masaaki Noguchi¹⁾

A Japanese man aged 30 years old contracted acute hepatitis B in October 2011, and was cured following conservative treatment. Mild hepatosplenomegaly was the only positive finding on computed tomography (CT) and ultrasonography at that time. In May 2012, slight impairment of the liver function was detected again in the patient ; an abdominal CT at this time revealed a tumor mass in the right hepatic lobe, so subsegmentectomy of the right hepatic lobe was performed. On the basis of the findings of the resected specimen, primary hepatic circumscribed Burkitt's lymphoma (sporadic form), stage IA, was diagnosed. Multiple cycles of hyper-CVAD/MTX-Ara-C therapy with concomitant rituximab were administered, under which the patient was successfully maintained in complete remission. To date, at least 15 cases of primary hepatic Burkitt's lymphoma have been reported in the literature ; all of the 11 patients without concurrent human immunodeficiency virus (HIV) infection had the sporadic form of the disease. Asians were relatively common (7 patients) among these patients, and patients in their childhood or adolescence accounted for a considerable proportion. Therefore, the present case may be regarded as rather typical. The presence of hepatitis virus infection as a background disorder other than HIV is considered to be of profound interest etiologically. [*J Clin Exp Hematop* 53(2) : 167-173, 2013]

Keywords: acute hepatitis B, seroconversion, liver, Burkitt's lymphoma

INTRODUCTION

Primary hepatic malignant lymphoma is a rarely encountered disease that has been estimated to account for 0.4% of all cases of extranodal non-Hodgkin's lymphoma and about 0.016% of all cases of non-Hodgkin's lymphoma.^{1,2} The prognosis is unfavorable, in that the reported median survival of patients is 15.3 months (3 to 123.6 months).² This has been attributed to the presence, at a high frequency among the patients, of unfavorable prognostic factors such as advanced

age, systemic involvement, bulky disease, the histologic type associated with a poor prognosis, elevated lactate dehydrogenase, findings indicative of liver cirrhosis, chronic active hepatitis, human immunodeficiency virus (HIV)-positive status and an immunosuppressive state.²

On the other hand, the prognosis of patients with primary hepatic malignant lymphoma without acute hepatic failure is favorable, with a reported 5-year survival rate of 87%,³ and that of patients with primary hepatic malignant lymphoma with acute hepatic failure is grave, with a reported mean survival of these patients of 11 days and only 13% achieving complete remission.⁴ Therefore, Mattar *et al.* inferred that the presence/absence of acute hepatic failure may be a significant factor influencing the prognosis.⁵

There are no reports yet of large-scale analyses of patients with primary hepatic Burkitt's lymphoma because of the extremely low incidence of this disease. In this paper, we review 15 cases of this disease reported in the literature, including the case documented herein. While the prognosis was unfavorable in 4 of the reported patients with HIV infection, it seemed to be relatively favorable in the remaining 11

Received : April 4, 2013

Revised : April 25, 2013

Accepted : May 15, 2013

Departments of ¹⁾Hematology and ²⁾Clinical Laboratory Medicine, Juntendo University Urayasu Hospital, Urayasu, Japan

³⁾Department of Hematology, Juntendo University Juntendo Hospital, Tokyo, Japan

⁴⁾Department of Pathology, Cancer Institute Hospital, Ariake, Tokyo, Japan

⁵⁾Department of Pathology, Toranomon Hospital, Tokyo, Japan

Corresponding author : Dr. Yasunobu Sekiguchi, Department of Hematology, Juntendo University Urayasu Hospital, 2-1-1, Tomioka, Urayasu, Chiba 279-0021, Japan

E-mail : yasu_sek@juntendo-urayasu.jp

patients without concurrent HIV infection. There was no appreciable difference in the prognosis between patients with concurrent hepatitis virus infection [hepatitis B in 2 patients, hepatitis C in 1 patient and Epstein-Barr virus (EBV) in 1 patient] and those without any concurrent hepatitis virus infection. In the patient reported herein, the lymphoma occurred after cure of acute hepatitis B.

CASE REPORT

A Japanese man aged 30 years old presented with impaired liver function. The patient's past medical history and family history were unremarkable, but he had had sexual intercourse with a sex worker a few months before.

He was admitted to a nearby hospital in October 2011 because of jaundice, fever, epigastric pain and liver function test abnormalities. A diagnosis of acute viral hepatitis B (wild type) was made on the basis of the following serological test results : positive for HBs antigen, anti-IgM HBc antibody and HB viral DNA (both polymerase chain reaction and TaqMan tests). Non-contrast computed tomography (CT) and ultrasonography of the abdomen revealed only mild hepatosplenomegaly, without any mass lesion. As the liver function improved in response to treatment with bed rest, a glycyrrhizinate preparation and ursodesoxycholic acid, the patient was discharged home in November. By January 2012, the liver function parameters had improved further and returned to the reference ranges, serology for HBs antigen and HB viral DNA (TaqMan method) became negative, while that for anti-HBc antibody became positive. In May 2012, the patient was again found to have impaired liver function parameters (aspartate aminotransferase, 81 U/L ; alanine transaminase, 191

U/L), with the serologic test results being negative for HBs antigen, positive for anti-HBs antibody and anti-HBc antibody, negative for HBe antigen, positive for anti-HBe antibody and negative for HB viral DNA (TaqMan test) ; thus, there was no evidence of relapse of the hepatitis B. In June 2012, the patient underwent a medical workup at the Department of Gastroenterology of Juntendo University Urayasu Hospital. CT of the abdomen revealed a 68 × 16 mm mass in the right lobe of the liver (Fig. 1a), with no abnormalities in the left lobe (Fig. 1b). The patient was admitted to the Department of Surgery in October, and a partial subsegmentectomy of the liver (S5, S6) was performed (Fig. 2) because of suspected primary hepatocellular carcinoma on CT findings.

His status on admission was as follows : height, 162 cm ; weight, 86 kg ; temperature, 36.9°C ; blood pressure, 136/50 mmHg ; and pulse, 76/min and regular. The patient's consciousness was clear, conjunctival examination revealed no pallor or icterus, there were no enlarged superficial lymph nodes or pedal edema, the heart sounds were clear, the lungs were clear, the abdomen was protruded and soft with the liver and spleen not palpable, and neurological examination revealed no abnormalities.

The laboratory findings are shown in Table 1 : Impaired liver function was evident ; however, the criteria for acute hepatic failure were not fulfilled, in that both the prothrombin time and the prothrombin time-international normalized ratio remained within the reference ranges. Serum α -fetoprotein and PIVKA-2 (protein induced by vitamin K absence or antagonist-2) levels were within the reference ranges. Serology for anti-HIV antibody was negative. Pathologic examination of hematoxylin and eosin (H&E)-stained section

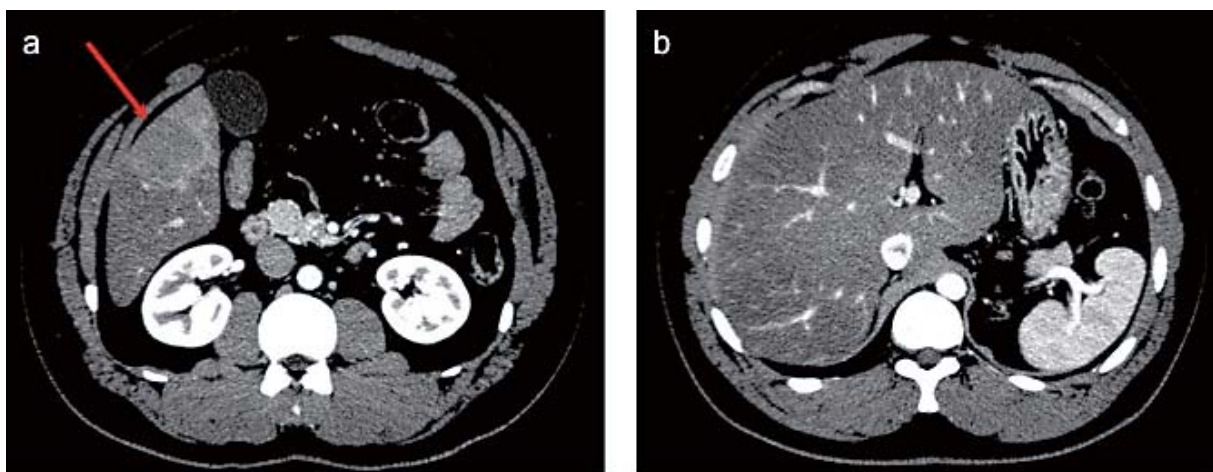


Fig. 1. Contrast-enhanced computed tomography (CT) of the abdomen. (*1a*) Contrast-enhanced CT scan of the abdomen at the time of admission of the patient in June 2012 shows a clearly demarcated mass lesion, about 68 × 16 mm in size, at the inferior margin of the right hepatic lobe (*red arrow*). (*1b*) Contrast-enhanced CT scan of the abdomen obtained at the time of admission of the patient in June 2012 shows no abnormalities in the left lobe.

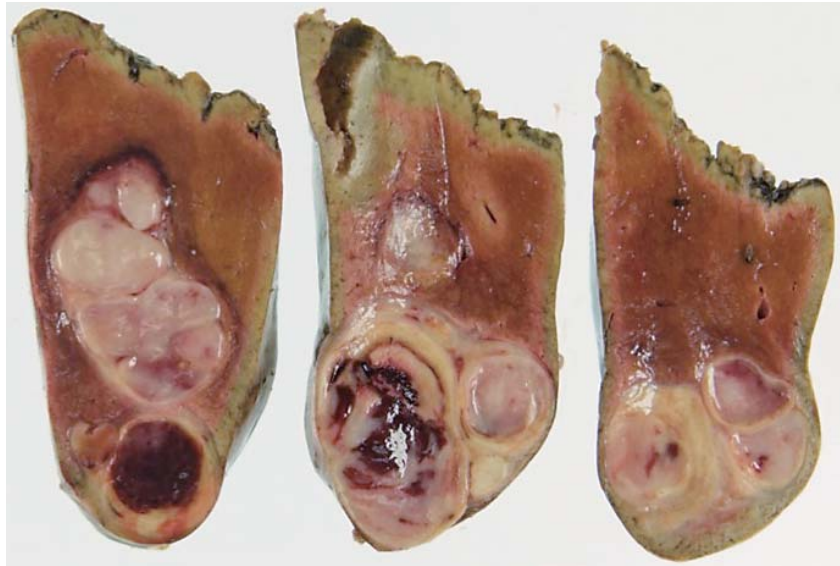

Fig. 2. A subsegmentectomy specimen of the right hepatic lobe. Multiple whitish nodular masses measuring about 3 to 4 cm in diameter were noted in the liver.

Table 1. Laboratory findings on admission

Complete blood cell count		Blood chemistry		Viral antigen/antibody	
White blood cell	7,300/ μ L	Total protein	7.5 g/dL	HBs antigen	Negative
Neutrophil	42.5%	Albumin	4.3 g/dL	Anti-HBs antibody	Positive \uparrow
Lymphocyte	39.5%	Total bilirubin	0.5 mg/dL	HBe antigen	Negative
Monocyte	9.0% \uparrow (4.0-7.0)	AST	100 IU/L \uparrow (12-33)	Anti-HBe antibody	Positive \uparrow
Eosinophil	5.5% \uparrow (1.0-5.0)	ALT	251 IU/L \uparrow (8-42)	HBc antigen	Not done
Basophil	2.0% \uparrow (0.0-1.0)	ALP	287 IU/L	Anti-HBc antibody	Positive \uparrow
Red blood cell	495×10^4 / μ L	Choline esterase	459 IU/L \uparrow (185-431)	HBV DNA	Negative
Hemoglobin	14.3 g/dL	LDH	346 IU/L \uparrow (119-229)	Anti-HCV antibody	Negative
Hematocrit	42.1%	γ -GTP	99 mg/dL \uparrow (10-47)	Anti-HTLV-1 antibody	Negative
Platelet	32.4×10^4 / μ L	Blood urea nitrogen	14 mg/dL	Anti-HIV antibody	Negative
Coagulation test		Creatinin	0.84 mg/dL	EBV VCA IgG	$\times 20 \uparrow$ (0-10)
PT	100%	C-reactive protein	0.6 mg/dL \uparrow (0.0-0.3)	EBV VCA IgM	$< \times 10$
PT-INR	0.97	Amylase	49 IU/L	EBV EBNA	$\times 20 \uparrow$ (0-10)
Immunology		Ammonias	39 μ g/dL	EBV DNA*	Negative
IgG	1,267 mg/dL	α -fetoprotein	1.1 ng/mL	Urine : No abnormality	
IgA	283 mg/dL	sIL-2 R	394 U/mL		
IgM	93 mg/dL	PIVKA-2	27 mAU/mL		
		Antinuclear antibody	$< \times 40$		

*, Southern blot assay ; PT, prothrombin time ; PT-INR, prothrombin time-international normalized ratio ; AST, aspartate aminotransferase ; ALT, alanine aminotransferase ; ALP, alkaline phosphatase ; LDH, lactate dehydrogenase ; γ -GTP, γ -glutamyl transpeptidase ; sIL-2 R, soluble IL-2 receptor ; PIVKA-2, protein induced by vitamin K absence or antagonist-2 ; HBV, hepatitis B virus ; HCV, hepatitis C virus ; HTLV, human T-lymphotropic virus ; HIV, human immunodeficiency virus ; EBV, Epstein-Barr virus

of the hepatic mass showed a starry sky appearance in the liver tissue under low-power magnification (Fig. 3a).

Examination under high-power magnification revealed diffuse infiltration by medium-sized tumor cells having delicate nuclei, with high N/C ratios (Fig. 3b). The tumor cells

were CD20-positive (Fig. 3c), CD10-positive (Fig. 3d), BCL-2-negative (Fig. 3e) and frequently positive for MIB-1 (Fig. 3f). The tumor cells were positive for CD79a (Fig. 3g). Paraffin-embedded tissue section fluorescence *in situ* hybridization (PS-FISH) analysis revealed positivity for the *c-myc*

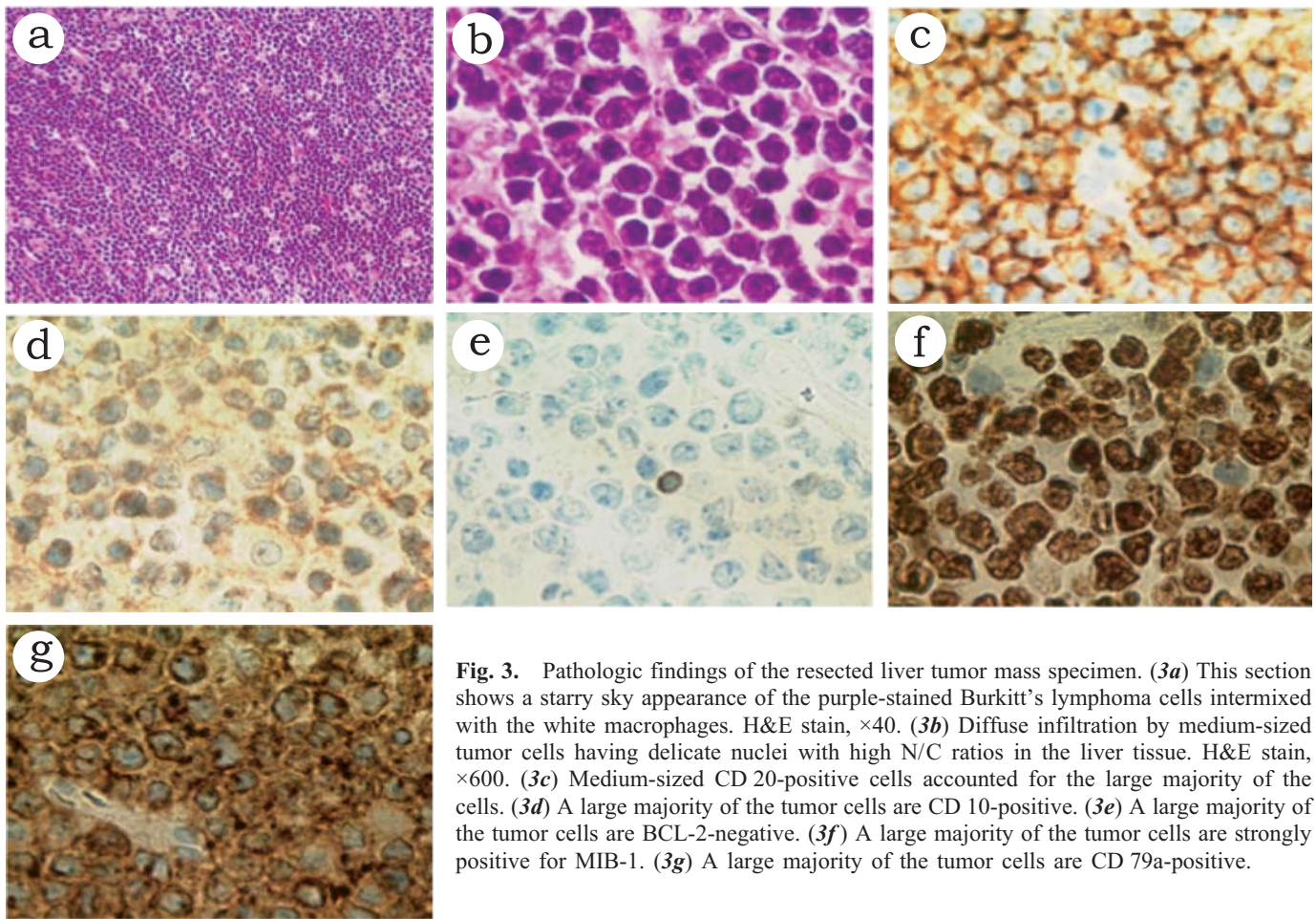


Fig. 3. Pathologic findings of the resected liver tumor mass specimen. (3a) This section shows a starry sky appearance of the purple-stained Burkitt's lymphoma cells intermixed with the white macrophages. H&E stain, $\times 40$. (3b) Diffuse infiltration by medium-sized tumor cells having delicate nuclei with high N/C ratios in the liver tissue. H&E stain, $\times 600$. (3c) Medium-sized CD 20-positive cells accounted for the large majority of the cells. (3d) A large majority of the tumor cells are CD 10-positive. (3e) A large majority of the tumor cells are BCL-2-negative. (3f) A large majority of the tumor cells are strongly positive for MIB-1. (3g) A large majority of the tumor cells are CD 79a-positive.

gene split signal (Fig. 4). On the basis of the above findings, the diagnosis of non-HIV-related, primary Burkitt's lymphoma (sporadic form), stage IA, was made.

The patient's clinical progress is shown in Fig. 5: Postoperative whole body CT scans did not reveal any evidence of tumors, nor did bone marrow and cerebrospinal fluid examinations reveal any abnormalities; therefore, the lesion, being confined to the liver, was judged to be stage I according to the Murphy (St. Jude) Staging Classification. The impaired liver function parameters improved after resection of the hepatic tumor, but a relapse followed. In November, the patient began a course of CHOP (cyclophosphamide, hydroxydaunorubicin, vincristine and prednisolone) therapy and concomitant entecavir medication. He was then switched back to hyper-CVAD/MTX-Ara-C (hyperfractionated cyclophosphamide, vincristine, doxorubicin and dexamethasone combined with methotrexate and cytarabine) therapy with concomitant rituximab in December, which was followed by complete remission.

DISCUSSION

The patient reported herein was diagnosed as having non-HIV-related, primary Burkitt's lymphoma (sporadic form), stage IA. Complete remission can generally be expected at a high probability in patients with Burkitt's lymphoma, insofar as administration of high-dose multi-drug combination chemotherapy is feasible, with a reported 5-year survival rate of 80% or more.^{6,7} On the other hand, primary hepatic Burkitt's lymphoma is a rare disease and the prognosis remains unclear.

There have been no more than 15 cases of primary hepatic Burkitt's lymphoma reported to date, including the case described herein (Table 2). Most of the reported patients were young, aged about 32 years old on average, and male. Patients with the sporadic form of the disease, that is, those without concurrent HIV infection, were younger, with a mean age of about 28 years, with a large proportion being children. The patient reported herein was 30 years old, a relatively old age, at the time of diagnosis. In regard to the ethnicity of the patients, the disease appears to be more frequent in Asians,

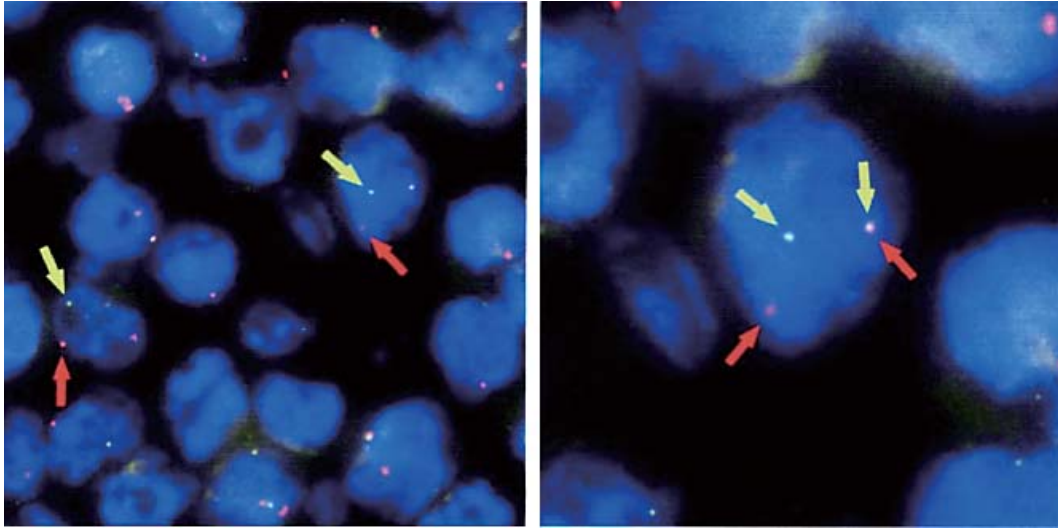


Fig. 4. Paraffin-embedded tissue section fluorescence *in situ* hybridization test of biopsy specimens of the liver mass showed a positivity rate for the *c-myc* split signal gene of 85% ; a red probe was placed on the blue telomeric side of the centromeric locus of the *c-myc* gene.

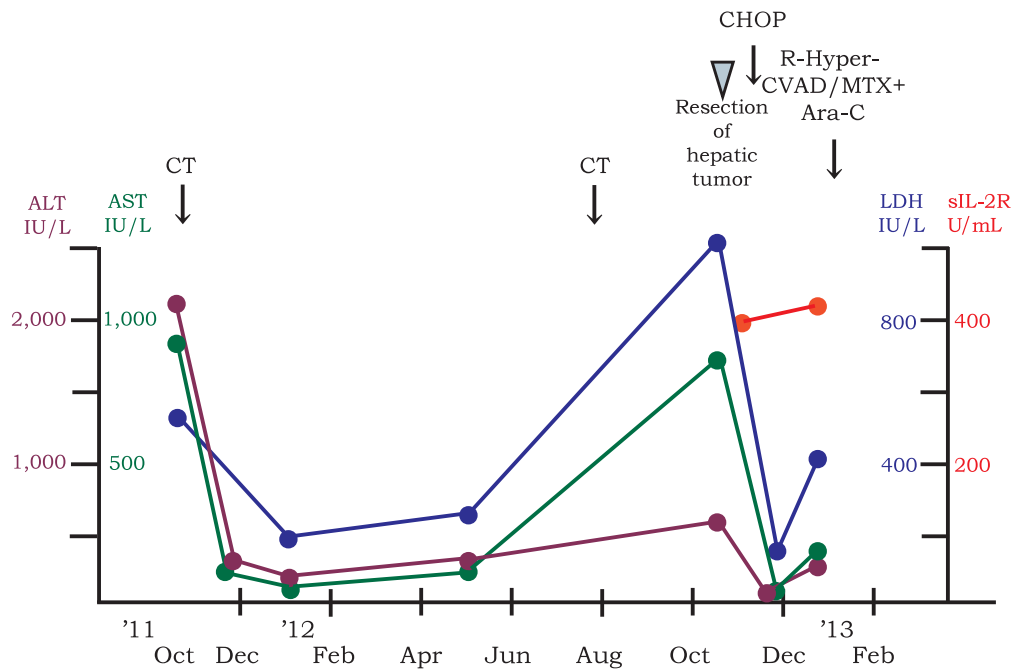


Fig. 5. Clinical progress chart. Acute hepatitis B was diagnosed in October 2011, and the liver function parameters improved following symptomatic treatment alone. In May 2012, the patient again developed evidence of hepatic dysfunction, without any evidence, however, of relapse of hepatitis B. Then, abdominal computed tomography revealed tumor masses in the right hepatic lobe, surgical resection of the tumor was performed, and the diagnosis of Burkitt's lymphoma (sporadic form) was established. A single course of CHOP (cyclophosphamide, hydroxydaunorubicin, vincristine and prednisolone) chemotherapy was administered, followed by hyper-CVAD/MTX-Ara-C (hyperfractionated cyclophosphamide, vincristine, doxorubicin and dexamethasone combined with methotrexate and cytarabine) therapy with concomitant rituximab, which were effective for maintaining complete remission in the patient.

Table 2. Reports of primary hepatic Burkitt's lymphoma cases

Case	Age/Sex	Nationality	Symptoms	Physical findings	Image	Concurrent disorder	Treatment	Outcome of lymphoma	Outcome	Reference
1	30/M	Japan	–	–	Solitary	Hepatitis B cured	Surgery/ chemotherapy	CR	CR was maintained for 3 months.	Present case
2	60/F	USA	Abdominal pain	Painful hepatomegaly	Multiple	HIV/acute hepatic failure/EBV	Chemotherapy	CR	CR was maintained for 12 months.	5
3	8.5/M	Kazakhstan	Fever/weight loss	Indolent hepatomegaly	Multiple	–	Chemotherapy	CR	CR was maintained for 22 months.	8
4	20/M	Korea	Abdominal pain	Painful hepatomegaly	Multiple	Hepatitis B carrier	Chemotherapy	CR	CR was maintained for 4 months.	9
5	40/F	USA	Abdominal pain/fever	NA	Multiple	HIV	Chemotherapy	NA	Died of sepsis	10
6	75/M	Japan	Fever/abdominal distention	Hepatomegaly, tenderness level unknown	Solitary	HCV	Chemotherapy	PD	Succumbed to the disease and sepsis	11
7	82/F	China	Abdominal distention/weight loss	Indolent hepatomegaly	Multiple	–	Chemotherapy	PR	Died of pneumonia after 4 months	12
8	32/M	USA	Fever/weight loss/ jaundice	Indolent hepatomegaly	Multiple	HIV	Chemotherapy	NA	Died of TLS 12 days after	13
9	14/M	China	Abdominal pain/weight loss	Painful hepatomegaly	Solitary	Hepatitis B carrier	Surgery/ chemotherapy	CR	CR was maintained for 8 years.	14
10	6/M	Brazil	Abdominal pain/ jaundice	Hepatomegaly, tenderness level unknown	Multiple	–	Chemotherapy	CR	CR was maintained for 25 months.	15
11	20/F	Portugal	Abdominal pain/ fever	Painful hepatomegaly	Multiple	–	Chemotherapy/ intracranial radiation	CR	CR was maintained for 3 years.	16
12	34/F	Morocco	Abdominal pain/ weight loss	Hepatomegaly, tenderness level unknown	Hepatomegaly	–	Surgery/ chemotherapy	CR	CR was maintained for more than 5 years.	17
13	47/M	France	NA	NA	Multiple	HIV	Chemotherapy	NA	Died of infection after 2 months	18
14	8/M	Nigeria	Abdominal distention	NA	Hepatomegaly	–	–	PD	Died of the disease 4 days after	19
15	14/M	Taiwan	Abdominal pain	Hepatomegaly, tenderness level unknown	Solitary	–	Surgery/ chemotherapy	NA	NA	20

M, man ; F, female ; CR, complete remission ; NA, not available ; PD, progression disease ; PR, partial remission ; HIV, human immunodeficiency virus ; HCV, hepatitis C virus ; TLS, tumor lysis syndrome

with the percentage of Asians increasing to 64% among patients with the sporadic form of the disease, that is, non-HIV-associated disease.

The common clinical manifestations in the reported cases were abdominal pain, pyrexia and the finding of hepatomegaly on physical examination. The hepatic lesions were diverse, for example, solitary tumors, multiple tumors or only hepatic enlargement. No concurrent disease was evident in a large proportion of the cases (7 patients), and, of profound interest, all concurrent disorders were viral diseases, being viral hepatitis in all the non-HIV-related cases. The concurrent disorders included HIV infection in 4 cases, hepatitis B virus carrier state in 2 cases, hepatitis C in 1 case and EBV infection in 1 case. Nevertheless, it was only in the present case that the symptoms of the subject disease developed after cure of acute hepatitis B.

Treatment consisted mainly of chemotherapy, with complete remission attained in 8 patients, while the disease progressed in only 1 patient. The outcome was death due to the disease in only 2 patients, of whom 1 had received no particular treatment. There were 5 patients who died due to complications (infection in 4 patients and tumor lysis syndrome in 1 patient), of whom 3 patients were HIV-positive. Thus, the

prognosis seems grave in HIV-positive patients. There was no appreciable difference in prognosis between non-HIV patients positive for hepatitis virus and those without any other concurrent disorders.

Thus, the prognosis of patients with primary hepatic Burkitt's lymphoma *per se* does not necessarily seem to be unfavorable, and could further improve with appropriate treatment, such as chemotherapy and corrective measures to cope with complications.

It has been reported that primary hepatic lymphoma may occur in patients receiving cyclosporine for the treatment of hepatitis B, hepatitis C, HIV infection, EBV infection, post-transplantation status or systemic erythematosus.^{2,3} A similar trend seems to prevail for primary hepatic Burkitt's lymphoma, as inferred from the above review of past reports. The above-mentioned factors could thus be thought of as risk factors (Table 2). The possibility that the immune responses to hepatitis B may have evoked the development of Burkitt's lymphoma of the liver in the case documented herein cannot be ruled out. Further accumulation of cases and analyses are needed. The reason why the Burkitt's lymphoma developed in the short time of approximately 8 months after the onset of hepatitis B is unknown.

CONFLICT OF INTEREST

The authors declare that they have no conflict of interest.

REFERENCES

- 1 Freeman C, Berg JW, Cutler SJ: Occurrence and prognosis of extranodal lymphomas. *Cancer* 29:252-260, 1972
- 2 Avlonitis VS, Linos D: Primary hepatic lymphoma : a review. *Eur J Surg* 165:725-729, 1999
- 3 Page RD, Romaguera JE, Osborne B, Medeiros LJ, Rodriguez J, *et al.*: Primary hepatic lymphoma : favorable outcome after combination chemotherapy. *Cancer* 92:2023-2029, 2001
- 4 Lettieri CJ, Berg BW: Clinical features of non-Hodgkin's lymphoma presenting with acute liver failure : a report of five cases and review of published experience. *Am J Gastroenterol* 98:1641-1646, 2003
- 5 Mattar WE, Alex BK, Sherker AH: Primary hepatic Burkitt lymphoma presenting with acute liver failure. *J Gastrointest Cancer* 41:261-263, 2010
- 6 Magrath I, Adde M, Shad A, Venzon D, Seibel N, *et al.*: Adults and children with small non-cleaved-cell lymphoma have a similar excellent outcome when treated with the same chemotherapy regimen. *J Clin Oncol* 14:925-934, 1996
- 7 Thomas DA, Faderl S, O'Brien S, Bueso-Ramos C, Cortes J, *et al.*: Chemoimmunotherapy with hyper-CVAD plus rituximab for the treatment of adult Burkitt and Burkitt-type lymphoma or acute lymphoblastic leukemia. *Cancer* 106:1569-1580, 2006
- 8 Mantadakis E, Raissaki M, Tzardi M, Katzilakis N, Chatzimichael A, *et al.*: Primary hepatic Burkitt lymphoma. *Pediatr Hematol Oncol* 25:331-338, 2008
- 9 Lee SH, Kim HJ, Mun JS, Oh HC, Lee HW, *et al.*: A case of primary hepatic Burkitt's lymphoma. *Korean J Gastroenterol* 51:259-264, 2008
- 10 Jacobs SL, Rozenblit A: HIV-associated hypervascular primary Burkitt's lymphoma of the liver. *Clin Radiol* 61:453-455, 2006
- 11 Kuroda J, Omoto A, Fujiki H, Okugawa K, Tamai H, *et al.*: Primary hepatic Burkitt's lymphoma with chronic hepatitis C. *Acta Haematol* 105:237-240, 2001
- 12 Chim CS, Choy C, Ooi GC, Liang R: Primary hepatic lymphoma. *Leuk Lymphoma* 40:667-670, 2001
- 13 Mossad SB, Tomford JW, Avery RK, Hussein MA, Vaughn KW: Isolated primary hepatic lymphoma in a patient with acquired immunodeficiency syndrome. *Int J Infect Dis* 4:57-58, 2000
- 14 Huang CB, Eng HL, Chuang JH, Cheng YF, Chen WJ: Primary Burkitt's lymphoma of the liver : report of a case with long-term survival after surgical resection and combination chemotherapy. *J Pediatr Hematol Oncol* 19:135-138, 1997
- 15 Ramos G, Murao M, de Oliveira BM, de Castro LP, Viana MB: Primary hepatic non-Hodgkin's lymphoma in children : a case report and review of the literature. *Med Pediatr Oncol* 28:370-372, 1997
- 16 Souto P, Romãozinho JM, Figueiredo P, Ferreira M, Sousa I, *et al.*: Severe acute liver failure as the initial manifestation of hematological malignancy. *Eur J Gastroenterol Hepatol* 9:1113-1115, 1997
- 17 Stemmer S, Geffen DB, Goldstein J, Cohen Y: Primary small noncleaved cell lymphoma of the liver. Report of an adult case in complete remission after treatment with combination chemotherapy. *J Clin Gastroenterol* 16:65-69, 1993
- 18 Scoazec JY, Degott C, Brousse N, Barge J, Molas G, *et al.*: Non-Hodgkin's lymphoma presenting as a primary tumor of the liver : presentation, diagnosis and outcome in eight patients. *Hepatology* 13:870-875, 1991
- 19 Adeodu OO, Nwosu SO, Odunusi OE: Hepatic Burkitt lymphoma. Presentation with extremely rapid growth. *Clin Pediatr (Phila)* 29:529-531, 1990
- 20 Wan YL, Chen WJ, Huang SC, Lee TY, Tsai CC: Solitary hepatic Burkitt lymphoma presenting as acute pancreatitis. *Pediatr Radiol* 18:160, 1988