

Case Study

Successful Treatment of Rituximab-Resistant Epstein-Barr Virus-Associated Post-transplant Lymphoproliferative Disorder Using R-CHOP

Takuro Kuriyama, Noriaki Kawano, Kiyoshi Yamashita, and Akira Ueda

Epstein-Barr virus (EBV)-associated post-transplant lymphoproliferative disorder (EBV-PTLD) is a complication of hematopoietic stem cell transplantation (HSCT). Standard initial treatment of patients with EBV-PTLD includes administration of rituximab or dose reduction of a calcineurin inhibitor. We report successful chemotherapeutic treatment of rituximab-resistant EBV-PTLD after HSCT in a patient with severe aplastic anemia (AA). A 38-year-old woman with antithymocyte globulin (ATG)-resistant severe AA received bone marrow transplantation from an unrelated donor (human leukocyte antigen-DR single-locus mismatch). The conditioning regimen included fludarabine, cyclophosphamide, ATG, and total body irradiation, and prophylaxis for graft-versus-host disease consisted of short methotrexate and tacrolimus. Neutrophil engraftment occurred on day 21. Left cervical lymph node swelling was observed after day 45, and analysis of a biopsy specimen revealed EBV-PTLD and a high blood EBV load (56,000 copies). The patient was treated with rituximab 4 times per week, but the lymphadenopathy continued and the blood EBV load increased to 96,000 copies. Half-dose treatment with rituximab, cyclophosphamide, vincristine, doxorubicin, and prednisolone (R-CHOP) was initiated on day 71. After 32 days of treatment with R-CHOP, the patient's neutrophil level was restored to $> 0.5 \times 10^9/L$ and both the lymphadenopathy and the blood EBV load (< 100 copies) were rapidly reduced. Although chemotherapy is not preferred soon after HSCT, it may be an effective strategy for treating patients with rituximab-resistant EBV-PTLD. [*J Clin Exp Hematop* 54(2) : 149-153, 2014]

Keywords: Epstein-Barr virus, hematopoietic stem cell transplantation, post-transplant lymphoproliferative disorder

INTRODUCTION

Hematopoietic stem cell transplantation (HSCT) is a recommended treatment option for patients with severe or very severe aplastic anemia (AA) who are 40 years of age or younger if they have a human leukocyte antigen (HLA)-identical sibling donor.¹ If there is no HLA-identical sibling donor, antithymocyte globulin (ATG) and cyclosporine are first-line treatments; however, recalcitrant cases must often undergo transplantation anyway. There are no clear guidelines for a conditioning regimen for patients with AA; however, in general, a conditioning regimen consisting of fludarabine, cyclophosphamide, ATG, or alemtuzumab and total body irradiation (TBI) is recommended.^{2,3} A conditioning

regimen that includes ATG improves graft rejection but increases the risk of complications such as viral infection, including reactivation of cytomegalovirus and Epstein-Barr virus (EBV).⁴

EBV-associated post-transplant lymphoproliferative disorder (EBV-PTLD) is a complication of HSCT.^{5,6} Immunosuppression, especially T-cell dysfunction, is important in the pathogenesis of EBV-PTLD, and EBV-PTLD usually occurs within 1 year after HSCT, before reconstitution of the EBV-specific cytotoxic T-lymphocyte response.⁷ The risk factors for EBV-PTLD are HLA mismatch between donor and recipient, conditioning regimens that include ATG, and T-cell-depleted transplantation.⁶⁻¹⁰ EBV DNA load is elevated exponentially in patients with EBV-PTLD, and weekly screening of the EBV DNA level is recommended for at least 3 months in high-risk patients who have undergone HSCT.¹¹⁻¹³

Reducing immunosuppression is the usual first-line treatment for patients with EBV-PTLD.¹⁴ However, it is often difficult to reduce immunosuppression in the early stages after HSCT because of concerns about exacerbation of graft-versus-host disease (GVHD) and graft rejection. Recently, rituximab, an anti-CD20 monoclonal antibody, has been used

Received: May 16, 2014

Revised : June 10, 2014

Accepted: July 29, 2014

Department of Internal Medicine, Miyazaki Prefectural Miyazaki Hospital, Miyazaki, Japan

Corresponding author: Takuro Kuriyama

Department of Internal Medicine, Miyazaki Prefectural Miyazaki Hospital, 5-30 Kitatakamatsu-machi, Miyazaki 880-8510, Japan

E-mail: t-kuri@pref-hp.miyazaki.miyazaki.jp

for the treatment of patients with EBV-PTLD, and response rates of 44-100% have been reported.¹⁵⁻¹⁹ However, these reports included patients treated with solid organ transplantation (SOT), and the effectiveness of treatment with rituximab limited to patients who have undergone HSCT remains unclear. Donor lymphocyte infusion (DLI) or chemotherapy is used for the treatment of rituximab-resistant EBV-PTLD, but there is no definitive therapy for this disease. Specifically, there is no established therapy for rituximab-resistant EBV-PTLD after HSCT. We report the successful chemotherapeutic treatment of a patient with rituximab-resistant EBV-PTLD after HSCT using ATG for severe AA.

CASE REPORT

A 38-year-old Japanese woman was referred to our hospital because of severe AA; she gave informed consent to publish the details of her case. On admission, her blood cell counts had not yet recovered 1 year after treatment with ATG and cyclosporine. Results of laboratory studies included the following: hemoglobin, 6.1 g/dL; reticulocytes, $13.9 \times 10^9/L$; platelets, $9.0 \times 10^9/L$; white blood cell count, $0.98 \times 10^9/L$ (neutrophils, $0.33 \times 10^9/L$); blood urea nitrogen, 14.6 mg/dL; creatinine, 0.6 mg/dL; total bilirubin, 0.63 mg/dL; aspartate aminotransferase, 25 U/L; alanine aminotransferase, 40 U/L; lactate dehydrogenase, 139 U/L; C-reactive protein, 0.09 mg/dL; and ferritin, 1,002 ng/dL. She had a history of infection with EBV; EBV-viral capsid antigen immunoglobulin M antibody was negative, EBV-viral capsid antigen immunoglobulin G antibody was positive, and EBV DNA load was

< 100 copies in whole blood. We obtained the patient's agreement for HSCT, which she received from an HLA-DR, single-locus, mismatched unrelated donor because she had no siblings or an HLA-matched unrelated donor. She received a conditioning regimen of 30 mg/m² fludarabine (days -7 to -4), 750 mg/m² cyclophosphamide (days -7 to -4), 2.5 mg/kg ATG (days -3 and -2), and 2 Gy of TBI (day -1). Prophylaxis for GVHD consisted of tacrolimus and short methotrexate. The donor was male, his blood type was AB⁺ (recipient: B⁺ major mismatch), and donor cell level was 1.70×10^8 cells/kg.

The clinical course is shown in Fig. 1. The patient developed a high fever when she received ATG on day -3, but was afebrile the next day, and there were no other adverse events during conditioning chemotherapy. Tacrolimus was given from day -1, and methotrexate was given on days 1, 3, 6, and 11. There were no grade ≥ 3 adverse events other than hematological toxicity and febrile neutropenia until neutrophil engraftment. Engraftment of neutrophils ($> 0.5 \times 10^9/L$) was achieved on day 21. Chimerism analysis showed complete donor type on day 34, and no grade ≥ 2 GVHD occurred.

On day 43, the patient developed a fever with swelling of her left tonsil. At first, we considered tonsillitis and she was treated with an oral antibiotic, but the swelling did not improve and left cervical lymphadenopathy appeared. Measurement of the EBV DNA level showed an increase to 56,000 copies (from < 100 copies on day 21). A biopsy of the tonsil was performed; histopathological analysis showed that the normal structure was destroyed, with diffuse invasion of cells showing atypical nuclear bodies. With immunostain-

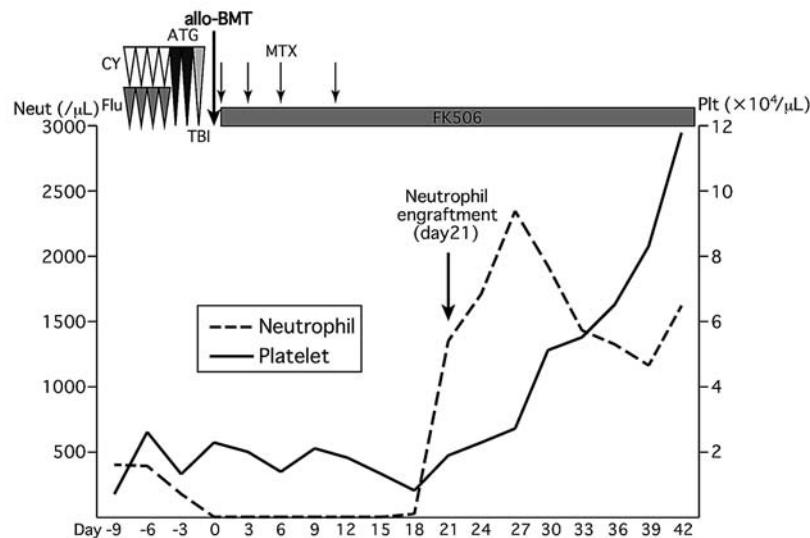


Fig. 1. The course of hematopoietic stem cell transplantation. Neut, neutrophil; Plt, platelets; CY, cyclophosphamide; Flu, fludarabine; ATG, antithymocyte globulin; TBI, total body irradiation; allo-BMT, allogeneic bone marrow transplantation; MTX, methotrexate; FK506, tacrolimus

ing, CD10, CD20, CD30, and EBV-encoded small RNA were positive and the MIB-1 index was 70%. EBV-PTLD was diagnosed on the basis of these results, and the patient was treated with rituximab (375 mg/m²) weekly from day 50. Treatment with tacrolimus was slowly tapered without exacerbating the GVHD; however, the patient's tonsil swelling and cervical lymphadenopathy did not improve. After 3 administrations of rituximab, computed tomography (CT) revealed exacerbation of the tonsil swelling and cervical lymphadenopathy compared with the case before rituximab therapy, and the EBV DNA level had increased to 96,000 copies. The patient was treated with R-CHOP (rituximab: 375 mg/m² on day 1; cyclophosphamide: 375 mg/m² on day 2; vincristine: 0.7 mg/m² on day 2; doxorubicin: 25 mg/m² on day 2; and prednisolone: 50 mg on days 2-6) at a 50% dose as second-line therapy for rituximab-resistant EBV-PTLD from day 71. Although grade 4 neutropenia and thrombocytopenia were prolonged for more than 4 weeks, the patient's tonsil swelling and cervical lymphadenopathy improved and responded well to chemotherapy (Fig. 2). After recovery from the myelosuppression, CT and positron emission tomography/CT revealed resolution of the tonsil swelling and cervical lymphadenopathy, and a rapid reduction in the blood EBV load was observed (< 100 copies) (Fig. 3). Thereafter, the patient was treated with rituximab weekly for 4 doses and was discharged from our hospital on day 125.

DISCUSSION

Standard therapy for EBV-PTLD after HSCT is rituximab or reduced immunosuppression therapy. However, it is difficult to reduce immunosuppression early after HSCT because

of concerns about exacerbating GVHD; for this reason, rituximab is often chosen for the treatment of patients with EBV-PTLD. The treatment of rituximab-resistant EBV-PTLD has not yet been established. With SOT, 63% of patients who developed localized EBV-PTLD improved with radiation therapy and 65-90% of patients with EBV-PTLD responded to standard CHOP or R-CHOP.²⁰⁻²² In pediatric patients with rituximab-resistant EBV-PTLD after SOT, there was an 83% overall response rate to low-dose chemotherapy (cyclophosphamide 600 mg/m² and prednisolone every 3 weeks for 6 cycles).²³ There are some reports of the treatment of EBV-PTLD after SOT or in pediatric patients, but there are only a few reports of treatment of EBV-PTLD after HSCT, especially during the early phase after HSCT. If chemotherapy is used for treatment, decisions regarding the therapeutic dose and frequency of treatment are currently made by the individual institution.

In our case, therapeutic options included DLI or chemotherapy when rituximab alone was ineffective for the treatment of EBV-PTLD. We chose chemotherapy because the patient's hematopoietic function had recovered (neutrophils > 2.0 × 10⁹/L, platelets > 100 × 10⁹/L) and we were concerned that DLI might lead to unnecessary exacerbation of GVHD for AA. However, the optimal dosage of chemotherapy is unclear, and we chose a 50% dose reduction for R-CHOP. Despite the reduced dose, myelosuppression was greater than that with standard R-CHOP dosing for malignant lymphoma, and grade 4 neutropenia and thrombocytopenia were prolonged for 4 weeks. Although the single cycle of chemotherapy improved the cervical lymphadenopathy and blood EBV load, the number of cycles to use was unknown. We considered maintenance therapy with rituximab to be a reasonable

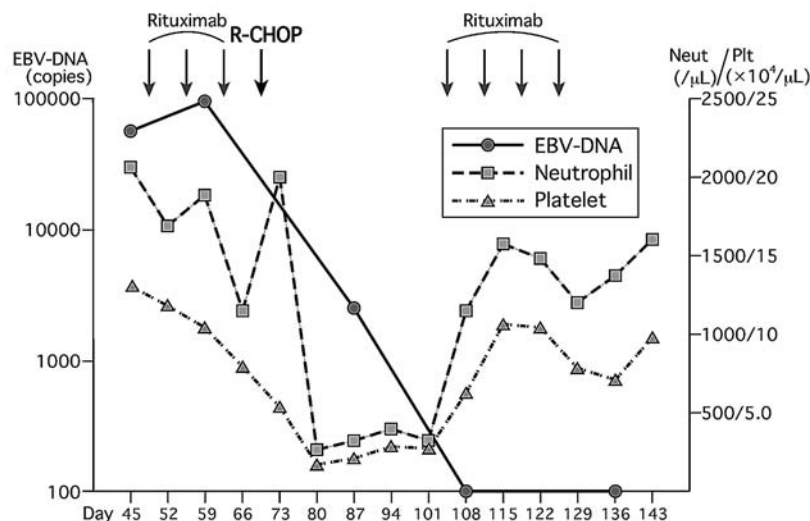


Fig. 2. The course of treatment of Epstein-Barr virus-associated post-transplant lymphoproliferative disorder. Neut, neutrophil; Plt, platelets; R-CHOP, rituximab, cyclophosphamide, vincristine, doxorubicin, prednisolone

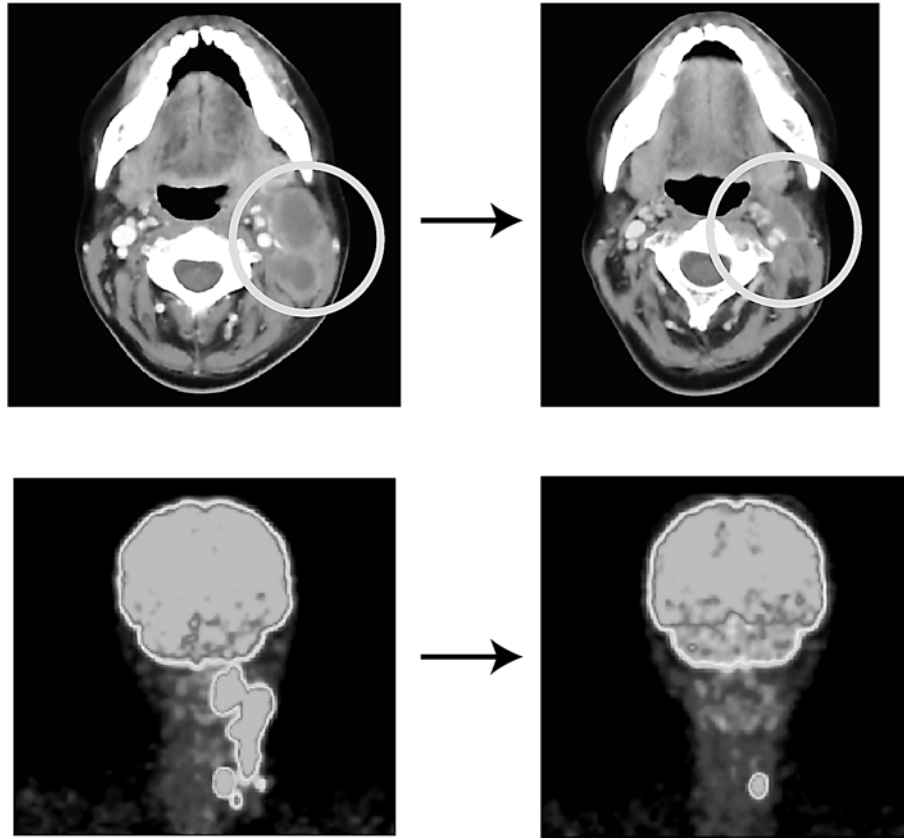


Fig. 3. Computed tomography and positron emission tomography images before and after treatment. Computed tomography and positron emission tomography revealed resolution of the tonsil swelling and cervical lymphadenopathy. There was a left thyroid mass before hematopoietic stem cell transplantation and cytological analysis revealed a benign disorder.

choice of therapy because the patient achieved remission with only a single course of R-CHOP, myelosuppression was greater than with standard R-CHOP dosing for malignant lymphoma and it would be difficult for the patient to receive multiple courses of chemotherapy, even though initial therapy with rituximab was ineffective for EBV-PTLD. After treatment, cervical lymphadenopathy did not recur in this patient and the blood EBV load has remained negative.

The response rate of DLI for EBV-PTLD is > 70%, but it is associated with an increased risk of exacerbating GVHD because the frequency of alloreactive T cells exceeds that of EBV-specific T cells.²⁴ Recent reports have shown that rituximab-resistant EBV-PTLD can be treated with EBV-specific T cells.²⁵⁻²⁸ Administration of EBV-specific T cells has few adverse effects, is effective, and prevents the development of EBV-PTLD. However, the cultivation of EBV-specific T cells takes more than 1 month and these cells cannot be reliably cultured and grown.

In conclusion, rituximab-resistant EBV-PTLD after HSCT for AA was treated with R-CHOP. Myelosuppression was prolonged for 4 weeks, although a single cycle of chemother-

apy improved the EBV-PTLD. It is expected that diversification of the transplant source, including an HLA-haploidentical donor, is associated with increased potent immunosuppression, including the administration of ATG; as a result, there is the potential for an increase in the development of EBV-PTLD. With the reported efficacy of administering EBV-specific T cells, a wide range of clinical applications is expected.

CONFLICT OF INTEREST

The authors declare no competing financial interests.

REFERENCES

- 1 Marsh JC, Ball SE, Cavenagh J, Darbyshire P, Dokal I, *et al.*: Guidelines for the diagnosis and management of aplastic anaemia. *Br J Haematol* 147:43-70, 2009
- 2 Gupta V, Ball SE, Sage D, Ortin M, Freires M, *et al.*: Marrow transplants from matched unrelated donors for aplastic anaemia using alemtuzumab, fludarabine and cyclophosphamide based

- conditioning. *Bone Marrow Transplant* 35:467-471, 2005
- 3 Bacigalupo A, Locatelli F, Lanino E, Marsh J, Socie G, *et al.*: Fludarabine, cyclophosphamide and anti-thymocyte globulin for alternative donor transplants in acquired severe aplastic anemia: a report from the EBMT-SAA Working Party. *Bone Marrow Transplant* 36:947-950, 2005
 - 4 Scheinberg P, Fischer SH, Li L, Nunez O, Wu CO, *et al.*: Distinct EBV and CMV reactivation patterns following antibody-based immunosuppressive regimens in patients with severe aplastic anemia. *Blood* 109:3219-3224, 2007
 - 5 Micallef IN, Chhanabhai M, Gascoyne RD, Shepherd JD, Fung HC, *et al.*: Lymphoproliferative disorders following allogeneic bone marrow transplantation: the Vancouver experience. *Bone Marrow Transplant* 22:981-987, 1998
 - 6 Shapiro RS, McClain K, Frizzera G, Gajl-Peczalska KJ, Kersey JH, *et al.*: Epstein-Barr virus associated B cell lymphoproliferative disorders following bone marrow transplantation. *Blood* 71: 1234-1243, 1988
 - 7 Heslop HE: How I treat EBV lymphoproliferation. *Blood* 114: 4002-4008, 2009
 - 8 Cohen JM, Cooper N, Chakrabarti S, Thomson K, Samarasinghe S, *et al.*: EBV-related disease following haematopoietic stem cell transplantation with reduced intensity conditioning. *Leuk Lymphoma* 48:256-269, 2007
 - 9 Brunstein CG, Weisdorf DJ, DeFor T, Barker JN, Tolar J, *et al.*: Marked increased risk of Epstein-Barr virus-related complications with the addition of antithymocyte globulin to a nonmyeloablative conditioning prior to unrelated umbilical cord blood transplantation. *Blood* 108:2874-2880, 2006
 - 10 van Esser JW, van der Holt B, Meijer E, Niesters HG, Trensche R, *et al.*: Epstein-Barr virus (EBV) reactivation is a frequent event after allogeneic stem cell transplantation (SCT) and quantitatively predicts EBV-lymphoproliferative disease following T-cell-depleted SCT. *Blood* 98:972-978, 2001
 - 11 Rooney CM, Loftin SK, Holladay MS, Brenner MK, Krance RA, *et al.*: Early identification of Epstein-Barr virus-associated post-transplantation lymphoproliferative disease. *Br J Haematol* 89:98-103, 1995
 - 12 Styczynski J, Reusser P, Einsele H, de la Camara R, Cordonnier C, *et al.*: Management of HSV, VZV and EBV infections in patients with hematological malignancies and after SCT: guidelines from the Second European Conference on Infections in Leukemia. *Bone Marrow Transplant* 43:757-770, 2009
 - 13 Kimura H, Ito Y, Suzuki R, Nishiyama Y: Measuring Epstein-Barr virus (EBV) load: the significance and application for each EBV-associated disease. *Rev Med Virol* 18:305-319, 2008
 - 14 Heslop HE, Li C, Krance RA, Loftin SK, Rooney CM: Epstein-Barr infection after bone marrow transplantation. *Blood* 83:1706-1708, 1994
 - 15 Faye A, Van Den Abele T, Peuchmaur M, Mathieu-Boue A, Vilmer E: Anti-CD20 monoclonal antibody for post-transplant lymphoproliferative disorders. *Lancet* 352:1285, 1998
 - 16 Verschuuren EA, Stevens SJ, van Imhoff GW, Middeldorp JM, de Boer C, *et al.*: Treatment of posttransplant lymphoproliferative disease with rituximab: the remission, the relapse, and the complication. *Transplantation* 73:100-104, 2002
 - 17 Ganne V, Siddiqi N, Kamaplath B, Chang CC, Cohen EP, *et al.*: Humanized anti-CD20 monoclonal antibody (Rituximab) treatment for post-transplant lymphoproliferative disorder. *Clin Transplant* 17:417-422, 2003
 - 18 Blaes AH, Peterson BA, Bartlett N, Dunn DL, Morrison VA: Rituximab therapy is effective for posttransplant lymphoproliferative disorders after solid organ transplantation: results of a phase II trial. *Cancer* 104:1661-1667, 2005
 - 19 Oertel SH, Verschuuren E, Reinke P, Zeidler K, Papp-Váry M, *et al.*: Effect of anti-CD20 antibody rituximab in patients with post-transplant lymphoproliferative disorder (PTLD). *Am J Transplant* 5:2901-2906, 2005
 - 20 Dotti G, Fiocchi R, Motta T, Mammana C, Gotti E, *et al.*: Lymphomas occurring late after solid-organ transplantation: influence of treatment on the clinical outcome. *Transplantation* 74: 1095-1102, 2002
 - 21 Choquet S, Trappe R, Leblond V, Jäger U, Davi F, *et al.*: CHOP-21 for the treatment of post-transplant lymphoproliferative disorders (PTLD) following solid organ transplantation. *Haematologica* 92:273-274, 2007
 - 22 Trappe R, Oertel S, Leblond V, Mollee P, Sender M, *et al.*: Sequential treatment with rituximab followed by CHOP chemotherapy in adult B-cell post-transplant lymphoproliferative disorder (PTLD): the prospective international multicentre phase 2 PTLT-1 trial. *Lancet Oncol* 13:196-206, 2012
 - 23 Gross TG, Bucuvalas JC, Park JR, Greiner TC, Hinrich SH, *et al.*: Low-dose chemotherapy for Epstein-Barr virus-positive post-transplantation lymphoproliferative disease in children after solid organ transplantation. *J Clin Oncol* 23:6481-6488, 2005
 - 24 Heslop HE, Brenner MK, Rooney CM: Donor T cells to treat EBV-associated lymphoma. *N Engl J Med* 331:679-680, 1994
 - 25 Rooney CM, Smith CA, Ng CY, Loftin SK, Sixbey JW, *et al.*: Infusion of cytotoxic T cells for the prevention and treatment of Epstein-Barr virus-induced lymphoma in allogeneic transplant recipients. *Blood* 92:1549-1555, 1998
 - 26 Heslop HE, Ng CY, Li C, Smith CA, Loftin SK, *et al.*: Long-term restoration of immunity against Epstein-Barr virus infection by adoptive transfer of gene-modified virus-specific T lymphocytes. *Nat Med* 2:551-555, 1996
 - 27 Comoli P, Basso S, Zecca M, Pagliara D, Baldanti F, *et al.*: Preemptive therapy of EBV-related lymphoproliferative disease after pediatric haploidentical stem cell transplantation. *Am J Transplant* 7:1648-1655, 2007
 - 28 O'Reilly RJ, Doubrovina E, Trivedi D, Hasan A, Kollen W, *et al.*: Adoptive transfer of antigen-specific T-cells of donor type for immunotherapy of viral infections following allogeneic hematopoietic cell transplants. *Immunol Res* 38:237-250, 2007