

Original Article

Six Cases of CD20-Positive Adult T-Cell Leukemia

Riko Kawano,¹⁾ Daisuke Niino,²⁾ and Koichi Ohshima¹⁾

Adult T-cell leukaemia/lymphoma (ATLL) is a neoplasm originating in mature CD4⁺ peripheral T cells. However, rare cases of CD20⁺ ATLL have been reported. Here, we describe six cases of CD20⁺ ATLL diagnosed in our department. The median age was 79 years (range, 54–90 years); two patients were men, and four were women. Elevated lactate dehydrogenase was observed in four cases. All cases were lymphoma type and positive for human T-lymphotropic virus-1 (HTLV-1). HTLV-1 proviral DNA was detected in four cases. The Ann Arbor stage was I, II, or IV in one patient each and III in three patients. The clinical course was poor in almost all cases. Tumour cells were large in all cases, and flow cytometry revealed CD20⁺ lymphoma cells in five of six cases. Immunohistochemistry revealed lymphoma cells positive for CD20, CD3, CD4, and CCR4 and negative for CD8, CD79a, and PAX5 in all cases. CD20 expression was lower than that in normal B cells. One case was initially misdiagnosed as diffuse large B-cell lymphoma. Thus, combined use of an antibody panel and molecular genetic studies is important to avoid misdiagnosing ATLL as B-cell lymphoma. [*J Clin Exp Hematop* 56(2):119-125, 2016]

Keywords: adult T-cell leukaemia/lymphoma, CD20, human T-cell lymphotropic virus 1

INTRODUCTION

Adult T-cell leukaemia/lymphoma (ATLL) is a type of T-cell lymphoma caused by infection with human T-cell lymphotropic virus 1 (HTLV-1).¹ HTLV-1 is endemic to the southwest region of Japan, the Caribbean, and central Africa, and infection occurs via mother's milk, sexual transmission, or blood transfusion. The risk of ATLL is 0.1–0.2% per year, and individuals 70 years of age have a 2–5% chance of contracting the disease.² More than 1 million individuals in Japan are thought to be carriers of HTLV-1, and approximately 500–600 individuals are diagnosed with ATLL each year in Japan. The male:female ratio of patients is 1.2:1. The average age of onset is 57 years,² and symptoms include skin-related symptoms, lymphadenopathy, hepatosplenomegaly, and hypercalcaemia. Analysis of the peripheral blood has shown the presence of lymphocytes resembling the 'flower cell' appearance. Moreover, in typical pathological histology, the lymph nodes show diffuse proliferation of lymphoid cells having atypical nuclei with deep notches.

Several studies have examined the markers of ATLL cells. Typically, ATLL cells exhibit the helper inducer T-cell phenotype, i.e., CD2⁺CD3⁺CD4⁺CD8⁻CD5⁺CD25⁺HLA-DR⁺. Some rare cases have shown the phenotypes of CD4⁺CD8⁻CD4⁺CD8⁺, or CD4⁺CD8⁺. Moreover, it is critical to differentiate between T cells and B cells when diagnosing malignant lymphoma.³ Therefore, in the diagnosis of malignant lymphoma, CD20 and CD3 immunostaining should be routinely performed. Notably, CD20 is a common marker of B cells, and ATLL cells are generally negative for CD20. However, CD20⁺ ATLL has been reported in rare cases.^{4,5} These cases were also shown to express CD3, CD4, and CD25.

In the study, we identified six cases of CD20⁺ ATLL diagnosed at our department, and analysed the clinical and pathological features.

MATERIAL AND METHODS

Cases

Tissue samples (n = 6) from six patients with ATLL were used. All tumour specimens were retrieved from the archives of Kurume University and their affiliated hospitals between 2009 and 2014. The samples and medical records used in our study were approved by the Institutional Review Board of the Kurume University School of Medicine (Fukuoka, Japan). Consent was obtained from all patients according to the Declaration of Helsinki.

Received: March 25, 2016

Revised : July 15, 2016

Accepted: July 19, 2016

¹⁾Second Department of Pathology, Kurume University School of Medicine, Fukuoka, Japan

²⁾Department of Nagasaki Educational and Diagnostic Center of Pathology, Nagasaki University School of Medicine, Nagasaki, Japan

Corresponding author: Professor Koichi Ohshima, Second Department of Pathology, Kurume University School of Medicine, 67 Asahi-machi, Fukuoka, 830-0011, Japan

E-mail: ohshima_kouichi@med.kurume-u.ac.jp

Histological and immunohistochemical studies

Tissue samples were fixed in 10% buffered formalin, embedded in paraffin, and processed using conventional histological and immunohistochemical methods. Sections (5 µm) were stained with hematoxylin and eosin (H&E) for histological evaluation. The remaining serial unstained sections were used for immunohistochemistry. All specimens were histologically diagnosed according to the World Health Organization criteria.

Immunohistochemical imaging was performed on paraffin-embedded sections following heat-induced antigen retrieval, staining with the appropriate antibodies, and signal detection using the immunoperoxidase methods (ChemMate ENVISION kit/HRP [DAB]; DakoCytomation; Dako, Glostrup, Denmark) using an autostainer (Dako Autostainer Universal Staining System). We performed immunostaining using monoclonal antibodies against human CD20 (dilution 1:5; IR604; Dako), human CD3 (dilution 1:50; M7254; Dako), human CD4 (dilution 1:30; 790-4423; Ventana, Tucson, AZ, USA), human CD8 (dilution 1:50; NCL-L-CD8-295; Leica, Newcastle Upon Tyne, UK), CD45RO (UCHL-1; dilution 1:200; NCL-UCHL1; Leica), human CD79a (dilution 1:400; M7050; Dako), human PAX5 (dilution 1:50; ACR207B; BioCareMedical, Pike Lane Concord, CA, USA), CC chemokine receptor 4 (CCR4; CD194; dilution 1:100; 551121; BD Pharmingen, Franklin Lakes, NJ, USA), and FOXP3 (dilution 1:50; ab99963; Abcam, Cambridge, UK). Immunohistochemical evaluation was performed by two observers (KO and DN) in independent readings.

In situ hybridization

In situ hybridization for the detection of Epstein-Barr Virus-encoded nuclear RNA (EBER) was performed on paraffin-embedded sections using standard procedures and commercially available reagents (dilution 1:5; Y5200; Dako).

Flow cytometry

Flow cytometry was performed on a FACSCalibur flow cytometer (Becton-Dickinson) using Cell Quest software (Becton-Dickinson) and conventional methods described previously.⁶ Briefly, cells were stained with fluorescein isothiocyanate (FITC)- or phycoerythrin (PE)-labelled monoclonal antibodies using the following combinations: CD2 (FITC), CD3 (FITC), CD4 (FITC), CD5 (PE), CD7 (PE), CD8 (PE), CD10 (PE), CD11c (PE), CD16 (FITC), CD19 (PE), CD20 (FITC), CD25 (PE), CD30 (FITC), CD34 (FITC), and CD56 (PE). Monoclonal antibodies targeting CD2, CD3, CD4, CD5, CD7, CD8, CD10, CD16, CD19, CD34, and CD56 were obtained from Coulter-Immunotech (Hiialeah, FL,

USA); those targeting CD11c, CD20, and CD25 as well as monoclonal kappa and lambda immunoglobulins were obtained from Becton-Dickinson; and those targeting CD23 and CD30 were from Coulter-Immunotech and Dako Cytomation, respectively. B-cell clonality was confirmed when evaluation of surface immunoglobulin expression showed bright monocytic light chain expression. In contrast, T-cell clonality was confirmed when the expression pattern was considered abnormal and to reflect a tumour cell pattern when one of the following three conditions was met: (i) partly positive or negative for at least a single pan-T-cell marker (CD2, CD3, CD5, and CD7); (ii) positive or partly positive for at least a single aberrant marker (CD10, CD11c, CD16, CD25, CD30, CD34, and CD56); and (iii) double positive or double negative for CD4/CD8.

Polymerase chain reaction (PCR) for the detection of TCR γ rearrangements

The TCR γ locus consists of 14 variable (V γ) genes that can be organized into four subgroups and five join (J γ) genes. Because the V γ I (V γ I-8) subgroup genes and the J γ gene segments are preferentially used in the majority (approximately 70%) of TCR γ rearrangements in lymphoid malignancies, we restricted our study to the analysis of TCR rearrangements involving these segments. The high homology between the genes of the V γ I subgroup allowed the construction of a consensus primer (TCR-GV1). For the J γ region, the consensus J12, JP12, and JP primers were designed to anneal to a completely homologous region of published sequences (J γ 1 and J γ 2, J γ P1 and J γ P2, and J γ P, respectively). These primers were used as a mixed primer J-Mix containing J12, JP12, and JP primers. The primer sequences were as follows: TCR-GV1, 5'-CACCAGGAGGGGAAGGCCACAGC(A/G)TCTTC-3'; J12, 5'-GACAAC(A/C)AGTGTGTTCCACTGCCA-3'; JP12, 5'-TTACCAGG(C/T)G A A G T T A C T A T G A G C - 3'; and JP, 5'-TAATGATAAGCTTTGTTCCGGGACC-3'. PCR amplification was performed with AmpliTaq Gold (Applied Biosystems, Foster City, CA, USA) using the primers TCR-GV1 and J-Mix. PCR cycling conditions were as follows: an initial denaturation at 95°C for 10 min; followed by 25 cycles of 95°C for 30 sec, 65°C for 30 sec, and 72°C for 30 sec; and a final extension at 72°C for 10 min. The amplified products were evaluated by 3% agarose gel electrophoresis and visualized by ethidium bromide staining under ultraviolet light. PCR products of TCR γ rearrangements appeared in the size range between 230 and 250 bp.

PCR for the detection of IgH rearrangements

Amplification of the IgH gene from the framework two part of the V segment to the J region was carried out using

the consensus primers complementary to the framework two portion of the VH region (FR2B) and the JH region (CFW1) from genomic DNA. The sequences of the primers used were as follows: FR2B, 5'-GTCCTGCAGGC(C/T)(C/T)CCGG(A/G)AA(A/G)(A/G)GTCTGGAGTGG-3'; CFW1, 5'-ACCTGAGGAGACGGTGACCAGGGT-3'. The PCR conditions were as follows: initial denaturation at 95°C for 10 min; five cycles of 95°C for 30 sec, 63°C for 30 sec, and 72°C for 30 sec; 45 cycles of 95°C for 30 sec, 60°C for 30 sec, and 72°C for 30 sec; and a final extension at 72°C for 10 min. Analysis of PCR products was performed as described above for TCR γ amplification. The size of IgH rearrangement fragments was usually between 250 and 300 bp.

RESULTS

Patients

We examined six cases of CD20⁺ ATLL. The median age of patients was 79 years (range, 54–90 years). Two patients were men, and four were women. Laboratory data showed an elevation of lactate dehydrogenase (LDH) in four of six cases. In all cases, serum test results were positive for HTLV-1, and HTLV-1 proviral DNA was detected in four of the six cases (i.e., cases 3, 4, 5, and 6). The Ann Arbor stage was I, II, III, or IV in one, one, four, and zero patients, respectively. Liver dysfunction was detected in case 1

(Table 1). We investigated the clinical course in cases 1, 2, 4, 5, and 6 (Table 1) and found that the survival time ranged from 10 days to 9 mon.

Pathological histology

Lymph nodes showed diffuse proliferation of large lymphoid cells (Fig. 1).

Immunostaining

As shown in Table 2 and Fig. 1, CD20 was weak to strongly positive (20–90%) in all cases, and CD45RO was weak to strongly positive (20–100%) in tumour cells. CD3 was strongly positive in all cases, and CD4 was positive in cases 1, 2, 3, 4, and 6. CD8 was negative in all cases, whereas CD79a was positive in only one case (case 6). PAX5 was negative in all cases, and CCR4 was positive in all cases. FOXP3 was positive in cases 2, 3, and 5. In cases 4 and 5, EBER-positive cells were scattered in the background (Fig. 1).

Flow cytometry

Flow cytometry revealed that all five of the analysed cases (cases 2, 3, 4, 5, and 6) were positive for CD20 (Table 3).

Table 1. Clinical data

No.	1	2	3	4	5	6
Age	54	88	65	90	73	84
Sex	Female	Female	Male	Female	Male	Female
Site	Neck Clavicle superior fovea	Neck	Skin Eyelid Neck Abdominal cavity	Axilla Neck	Neck Abdominal cavity Inguinal region Mediastinum	Neck Axilla Inguinen Abdominal cavity
Fever	+	-	-	-	-	-
Hepatospleno- megaly	Liver dysfunction (AST 69, ALT 120, γ GTP 191)	-	-	-	-	-
LDH	1,018	192	188	345	609	1,226
PS	1	1	0	0	0	1
Stage	III	I	III	II	III	III
Extranodal region	-	-	+	-	-	-
HTLV-1 antibody	+	+	+	+	+	+
sIL-2R	23,100		5,130	1,490		
Survival time	6 mon	9 mon	-	6 mon	6 mon	10 days

AST, aspartate aminotransferase; ALT, alanine transaminase; γ GTP, γ -glutamyl transpeptidase; HTLV, human T-lymphotropic virus

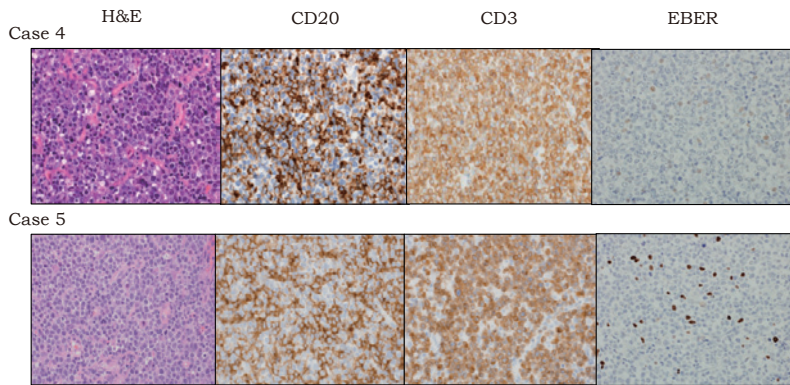


Fig. 1. Histological and immunohistochemical studies (cases 4 & 5). CD20 was weak to strongly positive, and CD3 was strongly positive. Epstein-Barr virus-encoded small RNA (EBER)-positive cells were scattered in the background.

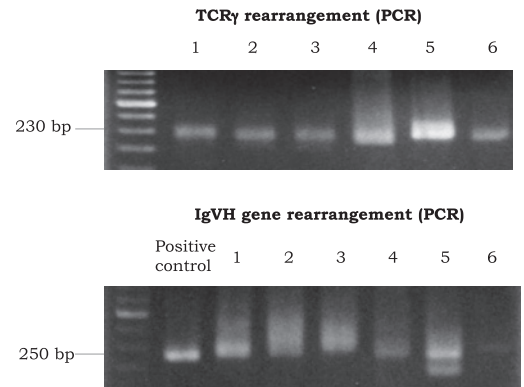


Fig. 2. TCR γ rearrangement and IgVH gene rearrangement on polymerase chain reaction (PCR).

Table 2. Morphological and immunohistochemical features

No.	1	2	3	4	5	6
Biopsy site	Neck Lymph node	Neck Lymph node	Neck Lymph node	Axillary lymph node	Neck lymph node	Lymph node
Growth pattern	Diffuse	Diffuse	Diffuse	Diffuse	Diffuse	Diffuse
Cell size	Large	Large	Large	Large	Large	Large
Nucleus	Pleomorphic	Pleomorphic	Pleomorphic	Pleomorphic	Pleomorphic	Pleomorphic
Mitosis	+	+	+	+	+	+
CD20/CD3 (%)	50	80	50	90	80	20
CD3	+	+	+	+	+	+
CD4	+	+	+	+	-	+
CD8	-	-	-	-	-	-
CD45RO/CD3 (%)	20	70	20	20	90-100	60
CD79a	-	-	-	-	-	+
PAX5	-	-	-	-	-	-
CCR4	+	+	+	+	+	+
FOXP3	-	+	+	-	+	-
EBV-ISH	-	-	-	+(*)	+(*)	-

(*), positive cells in the background; EBV-ISH, Epstein-Barr virus-*in situ* hybridization

HTLV-1 proviral DNA

HTLV-1 proviral DNA was analysed and found to be positive in four cases (data not shown).

Table 3. Flow cytometry analysis

No.	1	2	3	4	5	6
CD2	ND	66.2	94.1	51.9	5.7	97.4
CD3	ND	18.0	11.3	49.0	4.1	30.3
CD4	ND	20.9	93.5	38.4	2.9	88.8
CD5	ND	79.0	77.2	54.0	99.3	17.2
CD7	ND	71.7	9.3	47.8	80.1	15.9
CD8	ND	3.7	1.5	18.6	12.9	10.5
CD20	ND	71.6	49.0	55.9	81.4	70.7
CD25	ND	24.6	64.5	16.0	38.5	71.3
CD30	ND	10.1	3.9	1.4	30.9	16.6

ND, not done

Table 4. Chromosome test

No.	
1	Not done
2	47,X,- X,add(1)(q42),add(2)(q31)x2,dup(3)(p21p25),+add(4)(p11),add(4)(q21),del(5)(q?), add(10)(p11.2),add(12)(q13),add(22)(p11.2)+mar1{19}/46,XX{1}
3	46,XY,add(5)(q33), add(10)(p11.2), -14, add(21)(p11.2), +mar1[1]/46.idem,- 14,+mar2[7]/46,idem,ins(11;?)(q13;?)-14,+mar3[4]
4	48,XX,add(4)(q31),-5,add(5)(p11),-9,-9,add(12)(p11.2),-16,-17,+7mar[1]/46,XX[18]
5	60<2n>,X,- Y,+add(X)(p22.1),+add(1)(p13),add(1)(q11),add(2)(p11.2),add(2)(p23),add(3)(q11. 2),add(3)(q27),del(5)(q?)- 6,del(6)(q?),add(7)(q11.2),+add(8)(q22),+add(11)(p11.2),add(12)(q24.1),- 13,add(14)(q32),add(14)(q32),15,17,17,18,-22,+18mar[1]/46,XY[8]
6	87,XX,-X,-X,add(1)(p13),add(1)(p32)x2,-2,- 3,add(3)(q11.2)ins(3;?)(p21;?)x2,add(4)q31,-7,-8,del(10)(p13)x2,-13,-15,+17,-18,- 20,-20,+5mar[1]/46,XX[5]

Chromosome test

As shown in Table 4, samples from five patients were subjected to chromosome examination (cases 2, 3, 4, 5, and 6). A complex karyotype was observed in all five cases.

Gene rearrangement

TCR rearrangement and IgH rearrangement were analysed in all cases. TCR rearrangement was found in all cases, whereas IgH rearrangement was not detected in any case (Fig.2).

DISCUSSION

ATLL cells are usually negative for CD20. However, we encountered six cases of CD20⁺ ATLL in our department. All cases showed a poor clinical course with CD20, CD45RO, and CD3 expression. PAX5, a transcription factor expressed in pro- and premature B cells, was negative in all cases. TCR γ rearrangements were observed in all cases, whereas no IgH rearrangements were observed. The

findings also suggested a T-cell origin. These rare findings provide important insights into the pathogenesis of CD20⁺ ATLL.

The EBER⁺ lymphocytes were scattered in the background in two cases; however, no tumour cells showed EBV infection. Generally, EBV infects normal B lymphocytes, and when the percentage of EBV⁺ cells increases, B lymphocytes are also increased. In this study, the EBER⁺ lymphocytes detected in the background were thought to be B cells. Moreover, there were no correlations between CD20⁺ tumour cells and EBER⁺ cells. Thus, the CD20⁺ tumour cells in this study were shown to originate from T cells, and CD20 was aberrantly expressed by tumour cells.

Notably, when diagnosing ATLL, in order to prevent misdiagnosis, it is necessary to carefully analyse the histopathological features of the samples. For immunostaining of suspected malignant lymphoma, routine analyses include CD20 and CD3 immunostaining. CD3 is a T-cell marker; however, CD3⁺ cases have been reported on occasion. Additionally, CD3⁺ B-cell lymphomas have been reported.^{4,7} We recommend immunostaining for CD3, CD4, and CD8, additional T-cell markers, as well as CD79a and PAX5, which are B-cell markers. Further analysis of surface markers of lymphocytes is also necessary for diagnosing malignant lymphoma, and flow cytometry is a useful method in this regard. CD20 is only weakly expressed in a subset of normal peripheral blood T cells.⁸ Additionally, based on the expression of CD20 in T-cell lymphomas, the possibility of transformation of neoplastic CD20⁺ T cells has been reported.⁹ In our cases, CD20⁺ cells were also positive for CD3, CD4, and CCR4; therefore, we concluded that CD20 was expressed in ATLL cells.

In a report by Rahemtullah *et al.*, CD20 expression in T-cell lymphomas was shown to be weaker than that in normal B cells, suggesting neoplastic transformation of a normal CD20^{dim+} T-cell subset.⁷ Twenty-six case reports of CD20⁺ T-cell lymphoma have been published,⁷ and CD20⁺ ATLL has been reported in only two cases.^{4,5} In the first case, the T cells were characterized as CD2⁻CD3^{dim+}CD5⁺CD7⁺CD4⁺CD8⁻TCR $\alpha\beta$ ⁺TCR $\gamma\delta$ ⁻, and the B cells were characterized as CD2^{dim+}CD19⁻. TCR β rearrangement was clonal, and IgH was polyclonal. The patients received chemotherapy, and the lymphadenopathy disappeared, accompanied by decreased numbers of ATLL cells in the peripheral blood.⁴ In ATLL cells expressing CD20, CD20 mRNA was also expressed, further confirming the expression of CD20 in these cells.⁴ In another case,⁵ the T cells were characterized as CD2⁻CD3^{dim+}cCD3⁺CD4⁺CD5⁺CD7^{dim+}CD4⁺CD8⁻CD43⁺, and the B cells were characterized as CD20⁺FMC-7⁺CD10⁻CD25^{dim+}CD30⁻TdT⁻. TCR β rearrangement was clonal, and IgH was rearrangement polyclonal. The patient refused treatment and died within 11 days. In both cases, rituximab was not administered.^{4,5} Thus, the clinical course, histology,

immunostaining, and gene rearrangement results were similar between these two cases and our six cases.

Several cases of CD20⁺ peripheral T-cell lymphoma (not ATL) have been reported,⁹⁻¹¹ with patients being treated using rituximab. The patient was initially treated for stage III cancer with rituximab and a CHOP (rituximab, cyclophosphamide, doxorubicin, vincristine, and prednisolone) regimen, with substitution of liposomal doxorubicin for conventional chemotherapy. However, the patient relapsed within 1 month.⁵ Thus, these data suggested that rituximab may not be effective for the treatment of CD20⁺ T-cell lymphoma.

Finally, when diagnosing ATLL, in order to prevent misdiagnosis, it is necessary to carefully analyse and confirm immunostaining, flow cytometry, and histopathological findings.

CONFLICT OF INTEREST

The authors declare no conflicts of interest.

REFERENCES

- 1 Takatsuki K, Yamaguchi K, Kawano F, Hattori T, Nishimura H, *et al.*: Clinical diversity in adult T-cell leukemia-lymphoma. *Cancer Res* 45(9 Suppl):4644s-4645s, 1985
- 2 Tajima K, Hinuma Y: Epidemiology of HTLV-I/II in Japan and the world. *Gann Mono Can Res* 39:129-149, 1992
- 3 Kress AK, Grassmann R, Fleckenstein B: Cell surface markers in HTLV-1 pathogenesis. *Viruses* 3:1439-1459, 2011
- 4 Yasukawa M, Arai J, Kakimoto M, Sakai I, Kohno H, *et al.*: CD20-positive adult T-cell leukemia. *Am J Hematol* 66:39-41, 2001
- 5 Buckner CL, Christiansen LR, Bourgeois D, Lazarchick JJ, Lazarchick J: CD20 positive T-cell lymphoma/leukemia: a rare entity with potential diagnostic pitfalls. *Ann Clin Lab Sci* 37:263-267, 2007
- 6 Ohshima K, Haraoka S, Suzumiya J, Kawasaki C, Kanda M, *et al.*: Cytoplasmic cytokines in lymphoproliferative disorders: multiple cytokine production in angioimmunoblastic lymphadenopathy with dysproteinemia. *Leuk Lymphoma* 38:541-545, 2000
- 7 Rahemtullah A, Longtine JA, Harris NL, Dorn M, Zembowicz A, *et al.*: CD20⁺ T-cell lymphoma: clinicopathologic analysis of 9 cases and a review of the literature. *Am J Surg Pathol* 32:1593-1607, 2008
- 8 Storie I, Wilson GA, Granger V, Barnett D, Reilly JT: Circulating CD20^{dim} T-lymphocytes increase with age: evidence for a memory cytotoxic phenotype. *Clin Lab Haematol* 17:323-328, 1995
- 9 Quintanilla-Martinez L, Preffer F, Rubin D, Ferry JA, Harris NL: CD20⁺ T-cell lymphoma. Neoplastic transformation of a normal T-cell subset. *Am J Clin Pathol* 102:483-489, 1994
- 10 Matnani RG, Stewart RL, Pulliam J, Jennings CD, Kesler M:

Peripheral T-cell lymphoma with aberrant expression of CD19, CD20, and CD79a: case report and literature review. *Case Rep Hematol* 2013;183134, 2013 [doi: 10.1155/2013/183134]

- 11 Kamata M, Sugaya M, Miyagaki T, Sonoda K, Ichimura Y, *et al.*: A case of CD20-positive peripheral T-cell lymphoma treated with rituximab and multiagent chemotherapy. *Int J Dermatol* 53:e24-e26, 2014