

Original Article

# The Impact of a Humanized CCR4 Antibody (Mogamulizumab) on Patients with Aggressive-Type Adult T-Cell Leukemia-Lymphoma Treated with Allogeneic Hematopoietic Stem Cell Transplantation

Noriaki Kawano,<sup>1)</sup> Takuro Kuriyama,<sup>1)</sup> Shuro Yoshida,<sup>1)</sup> Sayaka Kawano,<sup>1)</sup>  
Yoshihisa Yamano,<sup>2)</sup> Kousuke Marutsuka,<sup>3)</sup> Seiichirou Minato,<sup>4)</sup> Kiyoshi Yamashita,<sup>1)</sup>  
Hidenobu Ochiai,<sup>5)</sup> Kazuya Shimoda,<sup>6)</sup> Fumihiko Ishikawa,<sup>7)</sup> and Ikuo Kikuchi<sup>1)</sup>

Although a humanized CCR4 antibody (mogamulizumab) was reported to be effective for refractory adult T-cell leukemia-lymphoma (ATL), several reports regarding the use of mogamulizumab before allo-hematopoietic stem cell transplantation (HSCT) strongly indicated a high incidence of severe acute graft-versus-host-disease (GVHD) and treatment-related mortality (TRM). We retrospectively analyzed nine aggressive-type ATL patients who underwent allo-HSCT at a single institution in Miyazaki from 2006.1.1 to 2015.7.31. Among nine ATL patients, three had used mogamulizumab before treatment with allo-HSCT because of the poor control of refractory ATL. All three patients were treated with four to eight cycles of mogamulizumab. The interval from last administration of mogamulizumab to allo-HSCT was two to five months. All three patients with prior mogamulizumab treatment developed mild-moderate acute GVHD (grade 2) 28, 34, or 40 days after allo-HSCT. Acute GVHD was controlled by prednisolone treatment. Two patients in complete remission before allo-HSCT exhibited relatively prolonged survival (survival rate, 66%). Moreover, one patient developed human T-cell leukemia virus type 1-associated myelopathy-mimicking myelitis at five months after allo-HSCT. In contrast, two of six ATL patients without a history of mogamulizumab use survived (survival rate 33%). Thus, in cases of mogamulizumab use before treatment with allo-HSCT for refractory ATL, an appropriately long interval from the last administration of mogamulizumab to allo-HSCT may be one of factors to reduce TRM by acute GVHD, and to subsequently enhance graft-versus-tumor effects in ATL cases. Furthermore, caution is needed when administering mogamulizumab before allo-HSCT for severe GVHD and TRM. [*J Clin Exp Hematop* 56(3):135-144, 2017]

**Keywords:** aggressive-type adult T-cell leukemia-lymphoma, humanized CCR4 antibody, allo-HSCT, acute GVHD, GVT

Received: January 2, 2016

Revised : November 28, 2016

Accepted: January 19, 2017

<sup>1)</sup>Department of Internal Medicine, Miyazaki Prefectural Miyazaki Hospital, Miyazaki, Japan

<sup>2)</sup>Department of Rare Diseases Research, Institute of Medical Science, St. Marianna University Graduate School of Medicine, Kanagawa, Japan

<sup>3)</sup>Department of Pathology, Miyazaki Prefectural Miyazaki Hospital, Miyazaki, Japan

<sup>4)</sup>Department of Neurology, Miyazaki Prefectural Miyazaki Hospital, Miyazaki, Japan

<sup>5)</sup>Trauma and Critical Care Center, Faculty of Medicine, University of Miyazaki Hospital, Miyazaki, Japan

<sup>6)</sup>Division of Gastroenterology and Hematology, Department of Internal Medicine, Faculty of Medicine, University of Miyazaki, Miyazaki, Japan

<sup>7)</sup>Research Unit for Human Disease Models, RIKEN Research Center for Allergy and Immunology, Yokohama, Japan

**Corresponding author:** Dr. Noriaki Kawano, Department of Internal Medicine, Miyazaki Prefectural Miyazaki Hospital, 5-30 Kitatakamatsu, Miyazaki, Miyazaki 880-8510, Japan

E-mail: kawanoriaki@yahoo.co.jp

## INTRODUCTION

Adult T-cell leukemia-lymphoma (ATL) is caused by clonal proliferation of human T-cell leukemia virus type 1 (HTLV-1)-infected CD4 T-cells.<sup>1,2</sup> Approximately 2–5% of HTLV-1 carriers develop ATL after a latency period that can last for decades, although the mechanism underlying leukemogenesis has not yet been clarified.<sup>3</sup> In general, acute lymphoma-type ATL progresses rapidly and the outcomes are generally poor within 6–12 months.<sup>4</sup> The remarkable progress in the understanding and treatment of the disease was achieved by the first description of the disease by Uchiyama in 1977, by the development of Shimoyama's criteria in 1991, by the clinical reports of the Japan Clinical Oncology Group-Lymphoma Study Group published in 2001 and 2007, and by

the treatment recommendations of the International Consensus Meeting of ATL researchers in 2009.<sup>1,4-10</sup> Moreover, hematopoietic stem cell transplantation (HSCT) has resulted in an overall survival (OS) rate of 30–40% at 3 years.<sup>11-15</sup>

Despite these remarkable advances in treatment, the mortality statistics from the Ministry of Health, Labour and Welfare in Japan show that approximately 1,000 people die annually from ATL, a statistic that has remained unchanged for at least the past decade;<sup>16</sup> a single-institution retrospective study at our institution yielded similar data.<sup>17</sup>

Mogamulizumab, a humanized CCR4 antibody, is a newly developed antibody that is effective for refractory and relapsed ATL, and newly diagnosed ATL.<sup>18-21</sup> It provided a breakthrough paradigm shift to a molecule-targeted approach for ATL therapy.<sup>18-21</sup> Mogamulizumab attacks targeted ATL cells via antibody-dependent cellular cytotoxicity and natural killer cells.<sup>21</sup> In addition to this mechanism, mogamulizumab also reduces the number of the effector regulatory T-cells (T-reg)<sup>22</sup>, which may be closely related to the control of acute graft-versus-host disease (GVHD) and cytotoxic T-cells in allo-HSCT.

Although the impact of mogamulizumab for acute GVHD and treatment-related mortality (TRM) of patients treated with allo-HSCT is presently unclear, the treatment outcomes of aggressive-type ATL treated with allo-HSCT with prior use of mogamulizumab were reported to be poor in contrast with ATL treatment with allo-HSCT without prior use of mogamulizumab.<sup>23-26</sup> One of the main reasons for this was speculated to be the occurrence of severe acute GVHD.<sup>23-26</sup> Thus, the prior use of mogamulizumab before treatment with allo-HSCT is still controversial for high incidence of TRM caused by severe acute GVHD. In refractory ATL cases with prior treatment with mogamulizumab, the reduction of the TRM caused by severe acute GVHD was essential for overcoming the poor treatment outcome.<sup>23-26</sup> Thus, in clinical practice, caution is needed when administering mogamulizumab before allo-HSCT because of the risk of the development of severe GVHD and TRM.

In this study, we retrospectively focused on and analyzed the three refractory ATL cases treated with conventional therapy, subsequently treated with mogamulizumab, and finally treated with allo-HSCT in comparison with six ATL cases treated with allo-HSCT without prior use of mogamulizumab.

## PATIENTS AND METHODS

Among 126 patients with aggressive ATL of acute-type (74 cases), lymphoma-type (50 cases), or chronic-type with unfavorable risk (two cases) according to Shimoyama's criteria, who required treatment from January 1, 2006 to July 31, 2015, we retrospectively analyzed and focused on nine patients with aggressive ATL who had been treated with allo-HSCT at Miyazaki Prefectural Miyazaki Hospital.

We previously reported that six aggressive ATL patients underwent allo-HSCT treatment without the prior use of mogamulizumab among 81 aggressive ATL patients required treatments from January 1, 2006 to November 20, 2012.<sup>17</sup> For additional analysis, we retrospectively reported that the two ATL patients who underwent allo-HSCT treatment with prior use of mogamulizumab among 14 ATL patients required mogamulizumab treatment from January 1, 2012 to November 20, 2014.<sup>21</sup>

At our institution, the indication for allo-HSCT treatment is based on the Fukuoka Bone Marrow Transplantation Group HSCT treatment guidelines:<sup>27</sup> age < 60 years, Eastern Cooperative Oncology Group performance status (PS) 0-2, adequate liver and kidney function (serum bilirubin level, < 2.0 mg/dl; serum creatinine level, < 2.0 mg/dl), and good disease control (complete remission, partial remission, or stable disease). Patients younger than 55 years underwent a myeloablative conditioning regimen consisting of total body irradiation of 12 Gy and cyclophosphamide (120 mg/kg), while those aged 55-60 years were preconditioned with a reduced intensity conditioning regimen of fludarabine (180 mg/sqm), busulfan (6.4 mg/kg), and low-dose total body irradiation (2 Gy). Eligible bone marrow (BM) donors included human leukocyte antigen-identical related (R-BM) and unrelated (UR-BM) donors from the Japan Marrow Donor Program as well as cord blood (CB) donors from the Japan Cord Blood Bank Network. Prophylaxis for GVHD was performed using short-term methotrexate plus cyclosporine for HSCT with human leukocyte antigen-identical and CB donors, and short-term methotrexate plus tacrolimus for allo-HSCT treatment using UR-BM donors. At our institution, mogamulizumab was administered for refractory ATL starting in May 2012. In January 2014, use of mogamulizumab before treatment with allo-HSCT was initiated.

The selection of the patients for mogamulizumab therapy was based on the following criteria: (a) those with disease refractory to the initial treatment, (b) those who required salvage therapy, and (c) those who demonstrated difficulty with continuing the initial treatment because of severe side effects such as prolonged thrombocytopenia. Consequently, three ATL patients were administered four to eight weekly cycles of mogamulizumab therapy at a dose of 1.0 mg/kg before HSCT treatment, based on the above selection criteria (case 1 (a), case 2 (c), case 3 (c)) and the clinical findings of the phase 2 study.<sup>19</sup> Treatment response was judged according to the Japan Clinical Oncology Group treatment response criteria for ATL.<sup>28</sup>

This retrospective study was conducted in compliance with good clinical practices and the ethical principles of the Declaration of Helsinki. Prior approval was obtained from the ethics review board at our institution.

**RESULTS**

**Patient characteristics and treatment outcomes of ATL patients treated with allo-HSCT following use of mogamulizumab**

The clinical characteristics of the three ATL patients that were treated with allo-HSCT and had a history of prior use of mogamulizumab are shown in Table 1A. At our institution, mogamulizumab was administered for refractory ATL starting in May 2012. In January 2014, use of mogamulizumab before treatment with allo-HSCT was initiated. After treatment with allo-HSCT, acute GVHD (grade 2, skin) was observed 28, 34, and 40 days after treatment with allo-HSCT in cases 1, 2, and 3, respectively. Typical skin images and histological findings are shown in Fig. 1A and Fig. 1B. In case 2, a bilateral skin rash was observed on the lower

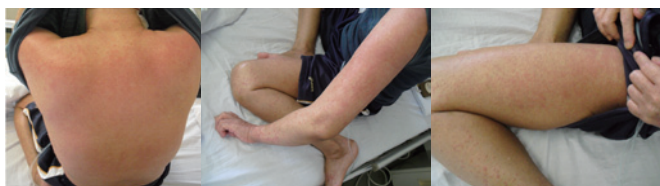extremities, abdomen, and back (Fig. 1A). A skin biopsy demonstrated the infiltration of T cells in the upper dermis and basal site of the epidermis, as well as the spongiotic change consistent with acute GVHD of the skin (Fig. 1B). Acute GVHD was controlled by the administration of prednisolone (PSL) ointment in case 1 and case 2, and by PSL treatment and PSL ointment in case 3, respectively (Fig. 2A-2C).

Two out of three ATL patients with a history of prior use of mogamulizumab showed relatively prolonged survival without relapse (66%). As for graft-versus-tumor effect (GVT) for ATL, in one patient (case 1) with lymphoma-type ATL, the skin lesions and lymph nodes regressed and partially diminished during the acute GVHD periods (Fig. 3). These findings clearly demonstrated the transient GVT of lymphoma-type ATL. However, the patient (case 1)

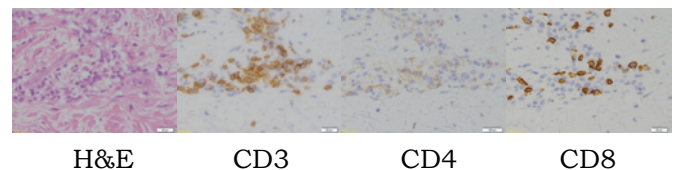
**Table 1A.** Patient characteristics and treatment outcomes of three adult T-cell leukemia-lymphoma patients treated with allogeneic hematopoietic stem cell transplantation with prior use of mogamulizumab

Case	Age	Sex	Subtype	Chemotherapy	Disease status	Mogamulizumab	Disease status	Allo-HSCT (Source)	Allo-HSCT (Conditioning)	GVHD prophylaxis	Acute GVHD	Survival
1	63	F	Lymphoma	CHOP (1)	PD	8	SD	Related HLA full matched PB	FLU/BU/TBI	CSP + sMTX	Grade 2 (skin)	355 days (dead)
2	46	F	acute	VCAP-AMP-VECP (1)	PR (thrombocytopenia)	4	CR	Unrelated HLA full matched BM	TBI/CY	FK + sMTX	Grade 2 (skin)	295 days (alive)
3	54	M	acute	VCAP-AMP-VECP (1)	PR (thrombocytopenia)	8	CR	Unrelated HLA full matched BM	TBI/CY	FK + sMTX	Grade 2 (skin)	546 days (alive)

F, female; M, male; CHOP, cyclophosphamide, doxorubicin, vincristine, and prednisolone; VCAP-VMPV-ECP, vincristine, cyclophosphamide, doxorubicin, and prednisone (VCAP)-doxorubicin, ranimustine, and prednisone (AMP)-vindesine, etoposide, carboplatin, and prednisone (VECP) therapy; PD, progressive disease; PR, partial response; CR, complete response; SD, stable disease; allo-HSCT, allogeneic hematopoietic stem cell transplantation; HLA, human leukocyte antigen; PB, peripheral blood; BM, bone marrow; FLU, fludarabine; BU, busulfan; TBI, total body irradiation, CY, cyclophosphamide; CSP, cyclosporine; sMTX, short-term methotrexate; FK, acrolimus; GVHD, graft-versus-host disease



**Fig. 1A.** Acute graft-versus-host-disease (GVHD) of skin in case 2. Skin rash was observed on upper and lower extremities, and back at day 34 after treatment with allogeneic hematopoietic stem cell transplantation. Skin biopsy was consistent with acute GVHD (grade 2) (in Fig. 1B). Furthermore, prednisolone ointments resolved the acute GVHD skin lesion.



**Fig. 1B.** Histological findings of acute graft-versus-host-disease (GVHD) of skin in case 2. Skin biopsy revealed that this lesion had mild, diffuse infiltration of lymphocytes in the upper dermis and basal side of epidermis. Spongiotic changes and individual cell necrosis of epidermal cells were observed, but no massive necrosis of epidermis or subepidermal cleft formation could be found. Moreover, immunohistochemically, infiltrating lymphocytes exclusively contained cCD3-positive T-lymphocytes, and an almost equal volume of CD4- and CD8-positive cells were noted. Only a few CD79a-positive B-lymphocytes were intermingled in one area. This was considered to be grade 2 acute GVHD.

Fig.2A: clinical course of case 1

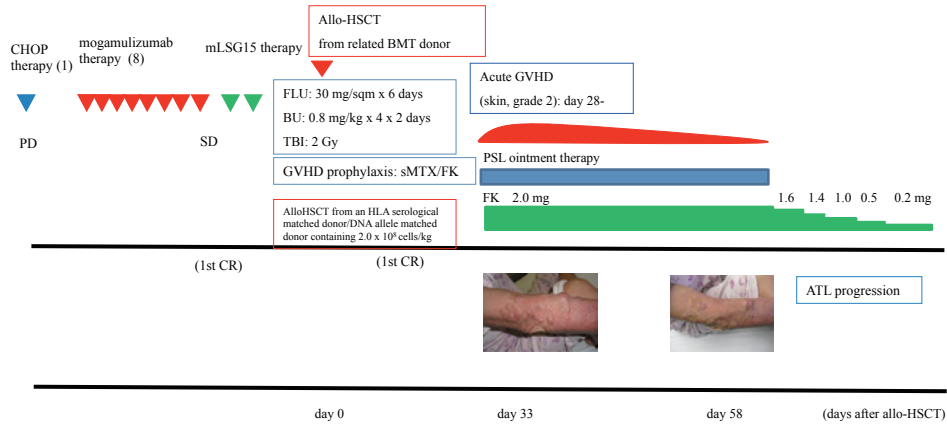


Fig.2B: clinical course of case 2

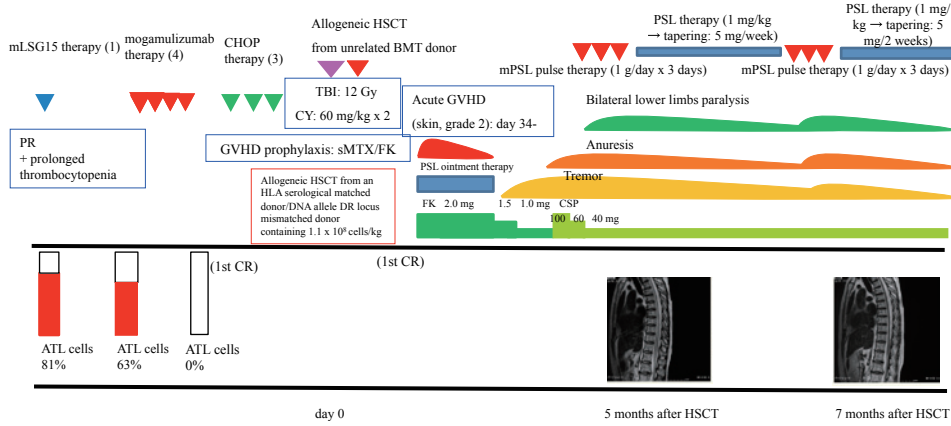
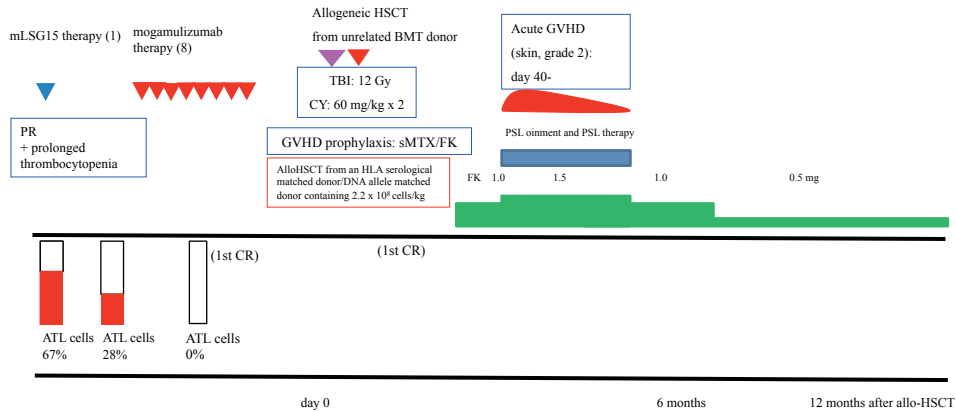


Fig.2C: clinical course of case 3



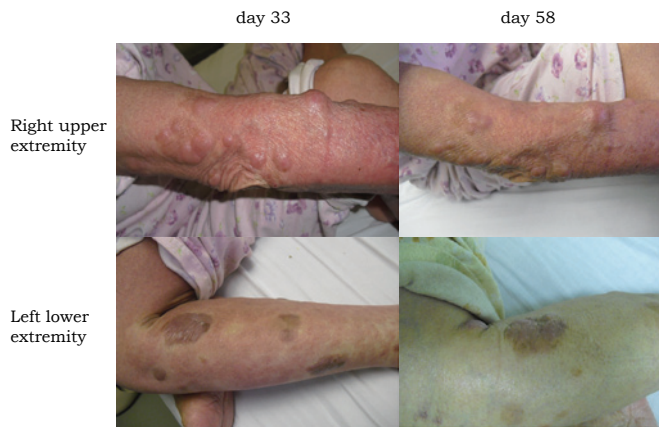**Fig. 2.** Clinical course. (2A) Clinical course of case 1. (2B) Clinical course of human T-cell leukemia virus type 1 associated myelopathy-mimicking myelitis in case 2. (2C) Clinical course of case 3. ATL, adult T-cell leukemia-lymphoma; CHOP, cyclophosphamide, doxorubicin, vincristine, and prednisolone; HSCT, hematopoietic stem cell transplantation; FLU, fludarabine; BU, busulfan; TBI, total body irradiation; GVHD, graft-versus-host disease; TBI, total body irradiation; CY, cyclophosphamide, sMTX, short-term methotrexate; FK, acrolimus; HLA, human leukocyte antigen; CR, complete remission; PD, progressive disease; PR, partial response; SD, stable disease; PSL, prednisolone; CSP, cyclosporine



eventually relapsed. Subsequently, tacrolimus gradually tapered and ceased. Further treatment, such as donor lymphocyte infusion or mogamulizumab, was not administered because of the progression of ATL and the poor PS. We did not measure the numbers of T-reg or the serum concentration of mogamulizumab before or after treatment with allo-HSCT

in the three cases.

In case 2, HTLV-1-associated myelopathy (HAM)-mimicking myelitis developed five months after treatment with allo-HSCT. Clinical courses are shown in Fig. 2B. In this case, the patient developed tremors at 3 months, anuresis at 4 months, and bilateral lower-limb paralysis at 5 months following treatment with allo-HSCT. Taking together the clinical symptoms (tremor, anuresis, and paralysis); increase in inflammatory cells ( $82/\text{mm}^3$ ), total protein level (150 mg/dl), and Th1 cytokine levels (neopterin: 95 pmol/ml, CXCL-10:IP-10: 41,556.8 pg/ml) in cerebrospinal fluid (CSF); radiological findings (swelling of spinal cord with enhancement); the absence of anti-HTLV-1 antibody; the absence of ATL cells; and the presence of HTLV-1 DNA by polymerase chain reaction analysis in the CSF, we finally made a diagnosis of acute onset HAM-mimicking myelitis following treatment with allo-HSCT, but not definite HAM because of the lack of anti-HTLV-1 antibody in the CSF. Treatment with mPSL pulse therapy twice and maintenance PSL therapy with rehabilitation led to remission of clinical symptoms, and laboratory and radiological findings without relapse.



**Fig. 3.** Transient graft-versus-tumor effect (GVT) effect after development of acute graft-versus-host-disease (GVHD) in case 1 (skin nodule of adult T-cell leukemia-lymphoma: day 33→day 58). In case 1, transient GVT during and after acute GVHD (skin, grade 2) was observed. From day 33 to day 58 after treatment with allogeneic hematopoietic stem cell transplantation, skin lesions and lymph node lesions markedly regressed. These findings clearly demonstrated that GVT was induced by acute GVHD.

**Table 1B.** Patient characteristics and treatment outcomes of six ATL patients treated with allo-HSCT without prior use of mogamulizumab

Case	Age	Sex	Subtype	Chemotherapy	Disease status	Allo-HSCT (Source)	Allo- HSCT (Conditioning)	GVHD prophylaxis	Acute GVHD	Survival
4	49	F	Lymphoma	CHOP-VMMV	CR	CB	TBI/CY	CSP + sMTX	-	138 days (dead, relapse)
5	42	M	Lymphoma	CHOP-VMMV	CR	CB	TBI/CY	CSP + sMTX	-	135 days (dead, relapse)
6	61	F	Acute	CHOP-VMMV	PR	CB	BU/FLU/ TBI	CSP + sMTX	-	28 days (dead, relapse)
7	44	F	Acute	VCAP-AMP-VECP	CR	Unrelated HLA full matched BM	TBI/CY	FK + sMTX	-	1084 days (alive)
8	56	F	Acute	VCAP-AMP-VECP	CR	Unrelated HLA full matched BM	TBI/CY	FK + sMTX	-	1156 days (alive)
9	41	F	Acute	VCAP-AMP-VECP	CR	Unrelated HLA full matched BM	TBI/CY	FK + sMTX	-	122 days (dead)

F, female; M, male; CHOP-VMMV, cyclophosphamide, doxorubicin, vincristine, and prednisone (CHOP) followed by etoposide, vindesine, ranimustine, and mitoxantrone with granulocyte colony-stimulating factor support; VCAP-AMP-VECP, vincristine, cyclophosphamide, doxorubicin, and prednisone (VCAP)-doxorubicin, ranimustine, and prednisone (AMP)-vindesine, etoposide, carboplatin, and prednisone (VECP) therapy; allo-HSCT, allogeneic hematopoietic stem cell transplantation; CR, complete response; PR, partial response; TBI, total body irradiation; CY, cyclophosphamide; FLU, fludarabine; CB, cord blood; GVHD, graft-versus-host disease; CSP, cyclosporine; sMTX, short term methotrexate

### ***Patient characteristics and treatment outcomes of ATL patients treated with allo-HSCT without prior use of mogamulizumab***

The clinical characteristics of the six ATL patients who underwent treatment with allo-HSCT without prior use of mogamulizumab are shown in Table 1B. These six ATL patients were treated with allo-HSCT from January 2006 to December 2013. After treatment with allo-HSCT, acute GVHD was not observed in any of the ATL patients. Three of the six ATL patients underwent treatment with allo-HSCT following chemotherapy using the source of CB because of the lack of availability of sibling donors or non-sibling donors and early transplantation during the disease control of ATL. Consequently, only two out of six ATL patients survived without relapse (33%). However, the remaining four ATL patients eventually relapsed. These patients did not respond to immediate cessation of immunosuppressants, and neither subsequent donor lymphocyte infusion nor salvage therapy (including mogamulizumab) was performed because of the aggressive progression of ATL and the poor PS.

### ***Comparison of ATL patients treated with allo-HSCT with and without prior use of mogamulizumab***

After treatment with allo-HSCT, acute GVHD was observed in 0/6 and 3/3 of the non-drug and mogamulizumab groups, respectively. Acute GVHD (grade 2, skin) was observed 28, 34, and 40 days after treatment with allo-HSCT in cases 1, 2, and 3, respectively. In contrast, in the non-drug groups, three of six ATL patients underwent treatment with allo-HSCT using the source of CB, and this resulted in the low incidence of acute GVHD during treatment with allo-HSCT. In the mogamulizumab groups, patients treated with mogamulizumab received eight, four, and eight administration cycles in cases 1, 2, and 3, respectively. The intervals from the last mogamulizumab administration to HSCT were 5, 3, and 2 months in cases 1, 2, and 3, respectively. The OS ratios were 33% (2 out of 6) and 66% (2 out of 3) for the non-drug and mogamulizumab groups, respectively. GVT for lymphoma-type ATL was observed in 0/2 and 1/1 of the non-drug and mogamulizumab groups, respectively.

HAM-mimicking myelitis after treatment with allo-HSCT was observed in 0/6 and 1/3 of the non-drug and mogamulizumab groups, respectively.

## **DISCUSSION**

Mogamulizumab eliminates not only CCR4-positive ATL cells<sup>18-21</sup> but also CCR4-positive normal T-reg, which play an important role in the regulation of GVHD.<sup>29</sup> Although the impact of mogamulizumab on acute GVHD and TRM of allo-HSCT is unclear, the use of mogamulizumab before treatment with allo-HSCT is still controversial because of the high incidence of TRM caused by severe acute GVHD.<sup>23-26</sup> In clinical practice, caution is needed when administering mogamulizumab before allo-HSCT. Indeed, the use of mogamulizumab before treatment with allo-HSCT should be limited to refractory aggressive-type ATL cases treated with conventional chemotherapy such as modified LSG 15 therapy. In such refractory ATL cases with prior treatment with mogamulizumab, reducing the TRM caused by severe acute GVHD is essential to overcome the poor treatment outcome.

The results of our retrospective study of refractory aggressive ATL cases that had undergone allo-HSCT treatment and had a history of mogamulizumab use before allo-HSCT were as follows: (i) onset of mild to moderate acute GVHD (grade 2) in all three patients who received mogamulizumab treatment; (ii) relatively prolonged survival with acute GVHD in two patients under complete remission before treatment with allo-HSCT; (iii) transient GVT effect in one patient with stable disease before treatment with allo-HSCT; (iv) interval of two to five months from the last administration of mogamulizumab to allo-HSCT; and (v) development of HAM-mimicking myelitis in one patient.

Consequently, despite using a small sample size at a single institution, our results clearly indicated that prior use of mogamulizumab before treatment with allo-HSCT in a relatively long interval from the last administration of mogamulizumab to allo-HSCT may reduce severe acute GVHD and affect the development of mild to moderate acute GVHD during the follow-up periods after treatment with allo-HSCT. Subsequently, mild to moderate acute GVHD may induce GVT and a relatively prolonged survival. Thus, our clinical

**Table 2.** The cycles and intervals of mogamulizumab before allo-HSCT (hematopoietic stem cell transplantation) and the development of acute graft-versus-host-disease (GVHD) after allo-HSCT among 3 cases

Case	Cycles of mogamulizumab	The days from last mogamulizumab administration to HSCT	Acute GVHD (Skin)
Case 7	8	151 days	Grade 2 (day 28)
Case 8	4	140 days	Grade 2 (day 34)
Case 9	8	61 days	Grade 2 (day 40)

results demonstrated good results of OS with three ATL patients who were treated with mogamulizumab before allo-HSCT in a relatively long interval from the last administration of mogamulizumab to allo-HSCT (151 days, 140 days, and 61 days.).

Thus, in the case of prior use of mogamulizumab before treatment with allo-HSCT for refractory ATL cases, an appropriately long interval from last mogamulizumab administration to allo-HSCT may be one of the factors to reduce TRM caused by acute GVHD. In clinical practice, caution is needed when administering mogamulizumab before allo-HSCT.

In addition, we discussed the possible benefits and risks of the use of mogamulizumab prior to treatment with allo-HSCT for the treatment of ATL in relation to the GVT effect for ATL and acute GVHD. Considering the possible benefits and risks of the use of mogamulizumab prior to treatment with allo-HSCT for the treatment of aggressive ATL, the priority is to reduce the risk of severe acute GVHD, and subsequently increase the benefit of the GVT effect for ATL.

First, the possible disadvantage of using mogamulizumab before treatment with allo-HSCT is that marked depletion of effector T-reg may result in the development of severe life-threatening acute GVHD.

Several reports<sup>23-26</sup> strongly indicated the increased development of acute GVHD and TRM after treatment with allo-HSCT in ATL patients previously treated with mogamulizumab (Table 3). Among several reports, Inoue *et al.*<sup>25</sup> reported that the 11 ATL patients treated with mogamulizumab before allo-HSCT presented acute GVHD grade II-IV (81.8%) and III-IV (36.4%) at 100 days after treatment with allo-HSCT, and chronic GVHD at 6 months after treatment with allo-HSCT. Thus, OS and TRM at 6 months were extremely severe outcomes, such as 31.8% and 58.2%, respectively. Thus, the use of mogamulizumab before treatment with allo-HSCT in short intervals (median 46 days) from the last administration of mogamulizumab to allo-HSCT was highly correlated with an increase of severe acute GVHD and TRM.<sup>25</sup>

**Table 3.** Previous reports and their present cases regarding the prior use of mogamulizumab and allo-HSCT

References	Age/Sex	ATL	Initial treatment	Response	Moga-mulizumab	Last mog administration to allo-HSCT	Disease status at allo-HSCT	Allo-HSCT source	Conditioning regimen	GVHD prophylaxis	The use of ATG	Acute GVHD	NRM	Overall Survival
Motohashi K, <i>et al.</i> (2013) <sup>23</sup>	52/female	Acute	VCAP-AMP-VECP (5)	PD	8	2 months	CR	UR-BM Serological 2 mismatch	Flu (25)5, mel (70) (2), ATG 1.25 mg/kg (1), TBI 3	FK + sMTX	+	Grade I (skin 2, liver 0, gut 0)	-	Alive: 4 months CR GVHD-
Ohgiya D, <i>et al.</i> (2014) <sup>24</sup>	54/female	Acute	VCAP-AMP-VECP (2)	PR	3	N.D.	CR	CB 2 locus mismatch	TBI/CY	FK + sMTX	-	Grade 2: skin	+	110 days dead
Inoue Y, <i>et al.</i> (2015) <sup>25</sup>	Male: 7, female: 4 54(44-66)	Acute 11	Prior regimen 1: 7, 2: 2, > 3: 2	N.D.	5 (1-8)	46 days: 54 <: 4, 36-54: 3, < 36: 4	CR: 4, PR: 5, SD: 1, PD: 1	PB: 3, BM: 8, CB: 0	MAC: 2, RIC: 9	CSP based 1, FK based 10	-	Acute GVHD at day 100 Grade II-IV: 81.8%, Grade III-IV: 36.4%, Chronic GVHD at 6 months: 21.2%	58.2% at 6 months Severe acute GVHD: 3 Graft failure 2 MOF 1	31.8% at 6 months
Haji S, (2016) <sup>26</sup>	56/male 61/female 49/male 63/male	Acute; 3 Lymph oma; 1	mEPOCH 4-6	PR1 PD3	1 2 3 4	37 38 100 122	CR2 PR2	UR-BM: 4	RIC4: FLU (30): 6 BU (3.2)2 TBI: 2	FK + sMTX: 4	-	All: 4 Acute GVHD II-III	1/4 fungal infection	1/4 survival Alive: 650 days Dead: 191, 201, 147 days
Present cases	63/female 46/female 54/male	Acute 2 Lymph oma 1	VCAP-AMP-VECP (2) CHOP (1)	PR 2 PD 1	8 4 8	151 140 61	CR 2 SD 1	Sibling BM: 1 UR- BM: 2	RIC: 1 TBI/CY (2)	CSP + sMTX (1) FK + sMTX (2)	-	ALL (3) Grade 2	0	2/3 Alive: 1084 days 1156 days Dead 122 days

VCAP -AMP-VECP, vincristine, cyclophosphamide, doxorubicin, and prednisone (VCAP)-doxorubicin, ranimustine, and prednisone (AMP)-vindesine, etoposide, carboplatin, and prednisone (VECP) therapy; mEPOCH, modified combination chemotherapy with etoposide, prednisone, vincristine, doxorubicin and carboplatin; N.D., not done; CR, complete response; PR, partial response; SD, stable disease; PD, progressive disease; allo-HSCT, allogeneic hematopoietic stem cell transplantation; UR-BM, unrelated donors of bone marrow from the Japan Marrow Donor Program (JMDP); CB, cord blood; BM, bone marrow; MAC, myeloablative conditioning; RIC, reduced-intensity conditioning; TBI, total body irradiation; CY, cyclophosphamide; FLU, fludarabine; BU, busulfan; GVHD, graft-versus-host disease; FK, tacrolimus; sMTX, short-term methotrexate; CSP, cyclosporine; MOF, multiple organ failure

To reduce the risk of acute GVHD, Motohashi *et al.*<sup>23</sup> successfully performed allo-HSCT for the ATL patient treated with prior use of mogamulizumab with a non-sibling donor with serological 2 mismatch by the intensification of GVHD prophylaxis-combined low dose anti-thymocyte globulin (ATG) (1.25 mg/kg). Thus, the intensification of acute GVHD prophylaxis for allo-HSCT, such as ATG, may be a reasonable therapeutic strategy for ATL patients previously treated with mogamulizumab before allo-HSCT.

In our study, all three patients with prior mogamulizumab treatment developed mild to moderate acute GVHD (grade 2) 28, 34, or 40 days after treatment with allo-HSCT. The intervals from the last mogamulizumab administration to HSCT were 5, 3, and 2 months in cases 1, 2, and 3, respectively. Thus, an appropriately long interval from last mogamulizumab administration to allo-HSCT may be one of the factors to reduce the risk of severe acute GVHD.

Consequently, for refractory ATL cases previously treated with mogamulizumab before allo-HSCT, a relatively prolonged interval from last administration of mogamulizumab to allo-HSCT may be one of factors to reduce the development of severe GVHD and TRM. Moreover, the intensification of GVHD prophylaxis or conditioning regimens, such as ATG, may be potential treatment strategies to reduce the development of severe GVHD and TRM.

Moreover, in our one case, HAM-mimicking myelitis was observed. The development of HAM-mimicking myelitis following treatment with allo-HSCT has been rarely reported. Kawamata *et al.*<sup>30</sup> first reported a post-transplant ATL case with HAM-mimicking myelitis.<sup>31</sup> Furthermore, these results suggest the possible involvement of a certain immunological mechanism, such as HAM, in the patient's symptoms, irrespective of the lack of anti-HTLV-1 antibody in the patient's CSF.<sup>31</sup> The depletion of effector T-reg may affect the unbalance of Th1 and Th2. Markedly high Th1 activity was related with the development of HAM-mimicking myelitis. Thus, immediate diagnosis and immediate PSL treatment were essential to improve the clinical symptoms and radiological findings of HAM-mimicking myelitis following treatment with allo-HSCT. In our case, immediate diagnosis of acute onset HAM-mimicking myelitis following treatment with allo-HSCT, but not definite HAM because of the lack of anti-HTLV-1 antibody in the CSF, and subsequent immediate PSL treatment also resolved the clinical symptoms and radiological findings of HAM-mimicking myelitis following treatment with allo-HSCT. Our clinical findings and treatment response may support that the donor immunological reaction following treatment with allo-HSCT may affect the development of HAM-mimicking myelitis.

Next, the possible advantages of using mogamulizumab before treatment with allo-HSCT may be the disease control of ATL before allo-HSCT, the induction of the GVT effect for ATL by mild-moderate acute GVHD (skin), and the

achievement of relatively prolonged survival by the selective depletion of effector T-reg. The mechanism of induction of acute GVHD was not fully elucidated. However, one of the possibilities is that the regulatory T-cells play a crucial role in the pathogenesis of acute GVHD. Hoffmann *et al.* reported that donor-type CD4<sup>+</sup>CD25<sup>+</sup> T-reg suppress lethal acute GVHD after treatment with allo-HSCT.<sup>29</sup> Thus, the selective depletion of effector regulatory T-cells may increase the possibility of development of acute GVHD. However, Kanda *et al.* also reported that the development of mild-to-moderate acute GVHD confers a lower risk of disease progression and a beneficial influence on survival of ATL patients treated with allo-HSCT.<sup>30</sup>

In addition to the development of acute GVHD, the selective depletion of effector T-reg by mogamulizumab may also contribute to the increase of cytotoxic T-cells in ATL patients through immune check point inhibition.<sup>18,22</sup> In a basic setting, Sugiyama *et al.* reported that mogamulizumab selectively depleted effector T-reg, evoking an anti-tumor immune response in humans.<sup>22</sup> In a clinical setting, Yamamoto *et al.* reported that three ATL patients treated only with mogamulizumab exhibited a relatively prolonged survival of 617 days, 379 days, and 198 days, respectively.<sup>18</sup> Our previous retrospective study also revealed that six ATL patients treated only with mogamulizumab demonstrated relatively prolonged survival (over 100 days).<sup>32</sup> These immunological effects by immune check point inhibitors may contribute to the relatively prolonged survival of ATL patients treated only with mogamulizumab.

Consequently, in our study, all three ATL patients treated with prior use of mogamulizumab before allo-HSCT developed tolerable acute GVHD, two of these patients exhibited prolonged survival without relapse, and one such patient exhibited GVT effect for lymphoma-type ATL.

Thus, with prior use of mogamulizumab before allo-HSCT, it is essential to reduce the risk of severe GVHD, which subsequently enhances the benefit of GVT for ATL. In clinical practice, the use of mogamulizumab before treatment with allo-HSCT should be limited to refractory aggressive ATL cases. Indeed, for refractory and relapsed ATL patients with a history of prior use of mogamulizumab before allo-HSCT, appropriately long intervals from last mogamulizumab to allo-HSCT may reduce the risk of acute GVHD. The appropriate relatively long intervals may be speculated from the following basic and clinical findings: (i) 18-day half-life of the pharmacokinetics of mogamulizumab;<sup>18,19</sup> (ii) pharmacokinetics of eight cycles of mogamulizumab;<sup>19</sup> (iii) the three- to four-month recovery time of T-reg;<sup>19</sup> or (iv) the onset of short intervals of severe acute GVHD (median 46 days) after the last mogamulizumab administration in patients treated with allo-HSCT.<sup>25</sup> Moreover, in the case of an ATL patient previously treated with mogamulizumab before allo-HSCT, the intensification of GVHD prophylaxis



may be needed to reduce the risk of acute GVHD.<sup>23</sup>

In the future, the relationship between the use of mogamulizumab before allo-HSCT and acute GVHD after treatment with allo-HSCT should be further studied to reveal the numbers of T-reg, the serum concentration of mogamulizumab, the occurrence of severe acute GVHD, and TRM. Moreover, a nation-wide study is needed to elucidate the duration from last mogamulizumab administration to allo-HSCT, the conditioning regimen of allo-HSCT, and the GVHD prophylaxis of allo-HSCT. Until the combination of clinical experience, further clinical trials, and nation-wide studies reveal the impact and the appropriate timing of prior use of mogamulizumab for allo-HSCT for ATL, caution is needed when administering mogamulizumab before allo-HSCT in clinical practice.

In conclusion, in cases of prior use of mogamulizumab before allo-HSCT for refractory ATL cases, appropriately long intervals from last mogamulizumab administration to allo-HSCT are needed to reduce TRM caused by acute GVHD. In clinical practice, caution is needed when administering mogamulizumab before allo-HSCT until further clinical trials, clinical experience, and nation-wide studies reveal the impact and the appropriate timing of prior use of mogamulizumab for allo-HSCT for ATL in the future.

### CONFLICT OF INTEREST

The authors state that they have no conflict of interest.

### REFERENCES

- 1 Uchiyama T, Yodoi J, Sagawa K, Takatsuki K, Uchino H: Adult T-cell leukemia: clinical and hematologic features of 16 cases. *Blood* 50:481-492, 1977
- 2 Yoshida M, Seiki M, Yamaguchi K, Takatsuki K: Monoclonal integration of human T-cell leukemia provirus in all primary tumors of adult T-cell leukemia suggests causative role of human T-cell leukemia virus in the disease. *Proc Natl Acad Sci U S A* 81:2534-2537, 1984
- 3 Tajima K, Kuroishi T: Estimation of rate of incidence of ATL among ATL (HTLV-I) carriers in Kyushu, Japan. *Jpn J Clin Oncol* 15:423-430, 1985
- 4 Shimoyama M: Diagnostic criteria and classification of clinical subtypes of adult T-cell leukaemia-lymphoma. A report from the Lymphoma Study Group (1984-87). *Br J Haematol* 79:428-437, 1991
- 5 Yamada Y, Tomonaga M, Fukuda H, Hanada S, Utsunomiya A, *et al.*: A new G-CSF-supported combination chemotherapy, LSG15, for adult T-cell leukaemia-lymphoma: Japan Clinical Oncology Group Study 9303. *Br J Haematol* 113:375-382, 2001
- 6 Tsukasaki K, Utsunomiya A, Fukuda H, Shibata T, Fukushima T, *et al.*: VCAP-AMP-VECP compared with biweekly CHOP for adult T-cell leukemia-lymphoma: Japan Clinical Oncology Group Study JCOG9801. *J Clin Oncol* 25:5458-5464, 2007
- 7 Tsukasaki K, Hermine O, Bazarbachi A, Ratner L, Ramos JC, *et al.*: Definition, prognostic factors, treatment, and response criteria of adult T-cell leukemia-lymphoma: A proposal from an international consensus meeting. *J Clin Oncol* 27:453-459, 2009
- 8 Ishitsuka K, Tamura K: Treatment of adult T-cell leukemia/lymphoma: past, present, and future. *Eur J Haematol* 80:185-196, 2008
- 9 Uozumi K: Treatment of adult T-cell leukemia. *J Clin Exp Hematop* 50:9-25, 2010
- 10 Tsukasaki K, Tobinai K: Clinical trials and treatment of ATL. *Leuk Res Treat* 2012:101754, 2012
- 11 Fukushima T, Miyazaki Y, Honda S, Kawano F, Moriuchi Y, *et al.*: Allogeneic hematopoietic stem cell transplantation provides sustained long-term survival for patients with adult T-cell leukemia/lymphoma. *Leukemia* 19:829-834, 2005
- 12 Okamura J, Utsunomiya A, Tanosaki R, Uike N, Sonoda S, *et al.*: Allogeneic stem-cell transplantation with reduced conditioning intensity as a novel immunotherapy and antiviral therapy for adult T-cell leukemia/lymphoma. *Blood* 105:4143-4145, 2005
- 13 Tanosaki R, Uike N, Utsunomiya A, Saburi Y, Masuda M, *et al.*: Allogeneic hematopoietic stem cell transplantation using reduced-intensity conditioning for adult T cell leukemia/lymphoma: impact of antithymocyte globulin on clinical outcome. *Biol Blood Marrow Transplant* 14:702-708, 2008
- 14 Hishizawa M, Kanda J, Utsunomiya A, Taniguchi S, Eto T, *et al.*: Transplantation of allogeneic hematopoietic stem cells for adult T-cell leukemia: a nationwide retrospective study. *Blood* 116:1369-1376, 2010
- 15 Ishida T, Hishizawa M, Kato K, Tanosaki R, Fukuda T, *et al.*: Allogeneic hematopoietic stem cell transplantation for adult T-cell leukemia-lymphoma with special emphasis on pre-conditioning regimen: a nationwide retrospective study. *Blood* 120:1734-1741, 2012
- 16 Yamada Y, Atogami S, Hasegawa H, Kamihira S, Soda M, *et al.*: Nationwide survey of adult T-cell leukemia/lymphoma (ATL) in Japan. *Rinsho Ketsueki* 52:1765-1771, 2011 (*in Japanese*)
- 17 Kawano N, Yoshida S, Kuriyama T, Tahara Y, Yamashita K, *et al.*: Clinical features and treatment outcomes of 81 patients with aggressive type adult T-cell leukemia-lymphoma at a single institution over a 7-year period (2006-2012). *Intern Med* 54:1489-1498, 2015
- 18 Yamamoto K, Utsunomiya A, Tobinai K, Tsukasaki K, Uike N, *et al.*: Phase I study of KW-0761, a defucosylated humanized anti-CCR4 antibody, in relapsed patients with adult T-cell leukemia-lymphoma and peripheral T-cell lymphoma. *J Clin Oncol* 28:1591-1598, 2010
- 19 Ishida T, Joh T, Uike N, Yamamoto K, Utsunomiya A, *et al.*: Defucosylated anti-CCR4 monoclonal antibody (KW-0761) for relapsed adult T-cell leukemia-lymphoma: a multicenter phase II study. *J Clin Oncol* 30:837-842, 2012
- 20 Ishida T, Jo T, Takemoto S, Suzushima H, Uozumi K, *et al.*:

- Dose-intensified chemotherapy alone or in combination with mogamulizumab in newly diagnosed aggressive adult T-cell leukaemia-lymphoma: a randomized phase II study. *Br J Haematol* 169:672-682, 2015
- 21 Niwa R, Shoji-Hosaka E, Sakurada M, Shinkawa T, Uchida K, *et al.*: Defucosylated chimeric anti-CC chemokine receptor 4 IgG1 with enhanced antibody-dependent cellular cytotoxicity shows potent therapeutic activity to T-cell leukemia and lymphoma. *Cancer Res* 64:2127-2133, 2004
  - 22 Sugiyama D, Nishikawa H, Maeda Y, Nishioka M, Tanemura A, *et al.*: Anti-CCR4 mAb selectively depletes effector-type FoxP3<sup>+</sup>CD4<sup>+</sup> regulatory T cells, evoking antitumor immune responses in humans. *Proc Natl Acad Sci U S A* 110:17945-17950, 2013
  - 23 Motohashi K, Suzuki T, Kishimoto K, Numata A, Nakajima Y, *et al.*: Successful treatment of a patient with adult T cell leukemia/lymphoma using anti-CC chemokine receptor 4 monoclonal antibody mogamulizumab followed by allogeneic hematopoietic stem cell transplantation. *Int J Hematol* 98:258-260, 2013
  - 24 Ohgiya D, Machida S, Ichiki A, Amaki J, Aoyama Y, *et al.*: Strong effect of mogamulizumab on splenic residual disease of adult T cell leukemia/lymphoma. *Ann Hematol* 93:719-720, 2014
  - 25 Inoue Y, Fuji S, Tanosaki R, Fukuda T: Pretransplant mogamulizumab against ATLL might increase the risk of acute GVHD and non-relapse mortality. *Bone Marrow Transplant* [Published online: December 21, 2015, DOI: 10.1038/bmt.2015.315]
  - 26 Haji S, Kiyasu J, Choi I, Suehiro Y, Toyoda K, *et al.*: Administration of an anti-CC chemokine receptor 4 monoclonal antibody, mogamulizumab, before allogeneic bone marrow transplantation for adult T-cell leukemia/lymphoma. *Bone Marrow Transplant* 51:432-434, 2016
  - 27 Nagafuji K, Miyamoto T, Eto T, Kamimura T, Taniguchi S, *et al.*: Monitoring of minimal residual disease (MRD) is useful to predict prognosis of adult patients with Ph-negative ALL: results of a prospective study (ALL MRD2002 Study). *J Hematol Oncol* 6:14, 2013
  - 28 Yamada Y, Tomonaga M, Fukuda H, Hanada S, Utsunomiya A, *et al.*: A new G-CSF-supported combination chemotherapy, LSG15, for adult T-cell leukaemia-lymphoma: Japan Clinical Oncology Group Study 9303. *Br J Haematol* 113:375-382, 2001
  - 29 Hoffmann P, Ermann J, Edinger M, Fathman CG, Strober S: Donor-type CD4<sup>+</sup>CD25<sup>+</sup> regulatory T cells suppress lethal acute graft-versus-host disease after allogeneic bone marrow transplantation. *J Exp Med* 196:389-399, 2002
  - 30 Kawamata T, Ohno N, Sato K, Kobayashi M, Jo N, *et al.*: A case of post-transplant adult T-cell leukemia/lymphoma presenting myelopathy similar to but distinct from human T-cell leukemia virus type I (HTLV- I)-associated myelopathy. *Springerplus* 3:581, 2014
  - 31 Kanda J, Hishizawa M, Utsunomiya A, Taniguchi S, Eto T, *et al.*: Impact of graft-versus-host disease on outcomes after allogeneic hematopoietic cell transplantation for adult T-cell leukemia: a retrospective cohort study. *Blood* 119:2141-2148, 2012
  - 32 Kawano N, Kuriyama T, Sonoda KH, Yoshida S, Yamashita K, *et al.*: Clinical impact of humanized CCR4 antibody (mogamulizumab) treatment on 14 patients with aggressive adult T-cell leukemia-lymphoma at a single institution over a 3-year period (2012–2014). *Intern Med* [*in press*]